

A Functional Neuroanatomy of Tics in Tourette Syndrome

Emily Stern, MD; David A. Silbersweig, MD; Kit-Yun Chee, MD; Andrew Holmes, PhD; Mary M. Robertson, MD; Michael Trimble, MD; Christopher D. Frith, PhD; Richard S. J. Frackowiak, MD; Raymond J. Dolan, MD

Background: Tics are involuntary, brief, stereotyped motor and vocal behaviors often associated with irresistible urges. They are a defining symptom of the classic neuropsychiatric disorder, Tourette syndrome (TS), and constitute an example of disordered human volition. The neural correlates of tics are not well understood and have not been imaged selectively.

Methods: Event-related [^{15}O]H $_2\text{O}$ positron emission tomography techniques combined with time-synchronized audio and videotaping were used to determine the duration of, frequency of, and radiotracer input during tics in each of 72 scans from 6 patients with TS. This permitted a voxel-by-voxel correlational analysis within Statistical Parametric Mapping of patterns of neural activity associated with the tics.

Results: Brain regions in which activity was significantly correlated with tic occurrence in the group in-

cluded medial and lateral premotor cortices, anterior cingulate cortex, dorsolateral-rostral prefrontal cortex, inferior parietal cortex, putamen, and caudate, as well as primary motor cortex, the Broca's area, superior temporal gyrus, insula, and claustrum. In an individual patient with prominent coprolalia, such vocal tics were associated with activity in prerolandic and postrolandic language regions, insula, caudate, thalamus, and cerebellum, while activity in sensorimotor cortex was noted with motor tics.

Conclusions: Aberrant activity in the interrelated sensorimotor, language, executive, and paralimbic circuits identified in this study may account for the initiation and execution of diverse motor and vocal behaviors that characterize tics in TS, as well as for the urges that often accompany them.

Arch Gen Psychiatry. 2000;57:741-748

TOURETTE SYNDROME (TS) is a classic neuropsychiatric disorder characterized by multiple motor and vocal tics. Tourette syndrome is seen worldwide, with typical onset in childhood, and a prevalence of approximately 5 per 10000.¹ Comorbid obsessive-compulsive, attention-deficit, and learning disorder features have been described as well.² There is a significant genetic component in TS, with a suggestion of autosomal dominant transmission, although there have been no significant linkage findings to date.^{1,3,4} Autoimmune mechanisms have also been implicated in some cases.^{5,6}

See also page 753

Tics, the defining symptom of TS, are sudden, brief, stereotyped actions. They may be simple vocalizations (such as grunting or sniffing), or movements of individual muscle groups. Alternatively, they

may be complex in nature, comprising whole words (including curses [coprolalia]) or clusters of movements.² Mild tics can be unintentional, involuntary actions that can occur without a patient's awareness. However, the more severe or complex tics are often intentional, "unvoluntary" actions, in that they are briefly suppressible, performed to relieve a local tension, sometimes preceded or provoked by an uncomfortable sensation, or performed compulsively in association with irresistible urges.^{2,7} In these cases, the subjective sense of free will is disrupted: tics are performed against the patient's will, or the will to act is not under the patient's control. Therefore, TS provides a model of one type of disordered human volition.

The neural correlates of these striking symptoms of volitional disruption are not well defined. Basal ganglia dysfunction has been suggested by the occurrence of tics in pathological conditions that affect these deep structures, such as carbon monoxide poisoning and encephali-

From the Department of Psychiatry, Weill Medical College of Cornell University, New York, NY (Drs Stern and Silbersweig); the Wellcome Department of Cognitive Neurology, Institute of Neurology (Drs Stern, Silbersweig, Holmes, Frith, Frackowiak, and Dolan) and the National Hospital for Neurologic Diseases (Drs Robertson and Trimble), London, England; and the Neuropsychiatric Institute, Prince Henry Hospital, Sydney, Australia (Dr Chee).

SUBJECTS AND METHODS

SUBJECTS AND CLINICAL CHARACTERIZATION

Six right-handed male patients with a *DSM-IV*³⁸ diagnosis of TS (mean age, 36.7 years, range, 25-47 years; duration of illness: mean \pm SD, 30.3 \pm 10.9 years) and frequent tics were studied after informed consent was obtained. Two patients were unmedicated and 4 suffered from tics despite neuroleptic medication (chlorpromazine dose equivalents, 2175, 50, 300, and 75 mg). All patients were assessed with the Yale Global Tic Severity Scale (mean \pm SD score, 39.3 \pm 12.2 of 55), the questionnaire form of the Leyton Obsessional Inventory (mean \pm SD score, 23.0 \pm 15.9 of 68), and the Beck Depression Inventory (mean \pm SD score, 7.2 \pm 6.0 of 39). Patients with notable head or neck tics, which could produce substantial head movement, were excluded. During the study sessions, all patients had simple and complex motor tics in varying muscle group distributions. Five patients had simple vocal tics, 4 of them had complex vocal tics, including coprolalia in 3.

SCAN CONDITIONS

Each of the patients was scanned 12 times, once every 10 minutes. Before each of the scans in the study session, each patient was instructed to relax, to close his eyes, and to allow the tics to emerge if they happened to occur, without any effort to induce or suppress them. The motor tics were monitored with 2 video cameras: 1 focusing just on the face and 1 covering the entire body. The vocal tics were monitored with a throat microphone and tape recorder, as well as with the video/audio camera. The video and audio tapes were time-synchronized with the computer that logged the whole-brain time-activity curve, which reflects radiotracer delivery to the brain during each scan. Head motion was kept to less than the full-width half maximum of the smoothed spatial resolution of the images with a custom-designed head holder that provided comfortable restraint.

IMAGE ACQUISITION, PROCESSING, AND STATISTICAL ANALYSIS

Regional cerebral blood flow was measured (as an index of neuronal activity) with a Siemens 953B PET scanner (Siemens Medical Systems, Hoffman Estates, Ill) in high-sensitivity 3-dimensional mode using a low-dose (15-mCi) [¹⁸O]H₂O slow-bolus technique, with 90-second acquisition (including a critical period of approximately 30 seconds, during which the pattern of radiotracer distribution in the

brain is determined).³⁵ The procedure was covered under an approval by the local hospital ethical committee and the Administration of Radioactive Substances Advisory Committee, United Kingdom. The data were corrected for background activity and attenuation, reconstructed (Hanning filter 0.5; 8.4-mm resolution full width half maximum), and the images were realigned to one another, smoothed with a 15 \times 15 \times 15-mm gaussian filter, transformed to the stereotactic space of Talairach and Tournoux,³⁹ and normalized using an analysis of covariance to remove the effect of differences in global blood flow across scans or sessions.⁴⁰ For each of the 12 scans in the study session, the type and distribution of each tic, and the timing and duration of each tic in relation to radiotracer delivery was noted on video and audio tapes. This information was obtained by a neuropsychiatrist (K.-Y.C.) extremely experienced with tics and TS patients, who repeatedly watched and listened to the tapes (which had time markers) to determine the tic information for each second of the critical radiotracer delivery periods. This information was then used to derive a weighted score for each scan,³⁶ reflecting the contribution of radiotracer deposition during tics to the image (**Table 1**). There was a spread of scan scores over the study session, reflecting differences across scans in the exact timing, duration, and frequency of tics, as well as the dynamic nature of the radiotracer input function during each scan. An event-related count rate correlational analysis³⁶ was then performed within the framework of voxel-by-voxel Statistical Parametric Mapping.⁴⁰ Without the need for separate "nontic control scans," this symptom-specific analysis identifies voxels with intensities covarying with the scores, corresponding to areas of the brain in which activity is specifically associated with the tics. The group analysis was performed for all 72 scans by determining the significance of the average covariate (tic scan score) effect, or average correlation, at each voxel, in a linear model (multiple regression with block effect), including subject-specific parameters for the scan scores, an effect for global cerebral blood flow, and additive subject effects; the latter adjust for between-subject differences in mean regional cerebral blood flow not accounted for by global changes. The effect of neuroleptic medication was minimized within subjects by focusing exclusively on the variance induced by tics (present despite medication in the medicated subjects) within a study session in which the dose was constant; it was minimized across subjects by the removal of subject-specific effects (which included medication dose), and by considering chlorpromazine equivalent doses as covariates of no interest. A similar, single-subject analysis was performed with data from an individual patient, for whom separate coprolalia/vocal tic and motor tic scores were calculated for each of 12 scans in the study session.

tic lethargia.^{8,9} The dopaminergic system has been implicated in TS because dopaminergic medication can induce tics, while blockade of dopaminergic neurotransmission can be effective in their suppression.² Most in vivo radioligand imaging and postmortem histochemical studies of TS have therefore focused on presynaptic and postsynaptic dopaminergic function in the basal ganglia,¹⁰⁻¹⁵ although a number of other brain regions and neurochemical (including peptide and second messenger) systems have been examined.¹⁶⁻¹⁸ Recent structural magnetic resonance imaging studies have demonstrated abnormalities

of volume and lack of normal asymmetry in the basal ganglia.¹⁹⁻²² A possible role for the anterior cingulate and midbrain in the generation of tics has also been suggested.^{23,24} Single-photon emission computed tomography and fludeoxyglucose F 18 positron emission tomography (PET) studies in the "resting" baseline state²⁵⁻³³ have produced variable results, with decreased or increased activity described in regions such as the striatum and thalamus, and premotor, sensorimotor, and paralimbic cortices. Disordered interactions between subcortical, paralimbic, and sensorimotor brain regions have also been

postulated.³⁰ A recent functional magnetic resonance imaging study³⁴ focusing on the suppression of tics found that increased severity of tics outside the scanner was associated with less of a suppression-related decrease in ventral globus pallidus, putamen, and midthalamus activity (and less of a corresponding increase in midfrontal, lateral temporal, inferior occipital, and head of caudate activity).

To date, the functional neuroimaging experiments of TS have provided extremely valuable information, but have not measured (or, in some cases, controlled for) tic occurrence during scanning, and therefore have not generated an image of the brain state specifically associated with tics. We have developed and validated methods of PET image acquisition and analysis^{35,36} that can isolate patterns of brain activity associated with transient, randomly occurring neuropsychiatric states. These methods have been used to study the functional neuroanatomy of hallucinations (involuntary perception) in schizophrenia.³⁷ In this study, they were used to examine the pathophysiology of tics (unvoluntary/involuntary action) in TS.

RESULTS

The group results were assessed at a threshold of $P < .005$, with spatial extent of activations corrected for multiple comparisons at a threshold of $P < .05$. Increased brain activity highly correlated with tic behavior was detected in a set of neocortical, paralimbic, and subcortical regions, including supplementary motor, premotor, anterior cingulate, dorsolateral-rostral prefrontal, and primary motor cortices, the Broca's area, insula, claustrum, putamen, and caudate. Activations in superior temporal gyrus, inferior parietal cortex, and a point near the anterior thalamus, extending toward the head of caudate were also detected. These foci of activation are displayed and characterized in **Figure 1** and **Table 2**.

For a single subject in whom greater than 90% of vocal tics were coprolalia, separate scan scores were generated for coprolalia/vocal tics and for motor tics. At a threshold of $P < .005$, with spatial extent corrected for multiple comparisons at $P < .05$, coprolalia was associated with activity in a set of regions, including the frontal operculum and the Broca's area (Brodmann areas [BAs] 44, 45) ($z = 4.34$; $x, y, z = -30, 20, 16$) (extending ventrally in the opercular region adjacent to BA 47; $z = 2.88$; $x, y, z = 22, 28, 0$); superior temporal gyrus (BA 42; $z = 4.22$; $x, y, z = -60, -26, 8$) (BA 22; $z = 4.05$; $x, y, z = -50, -40, 12$); head of caudate ($z = 3.46$; $x, y, z = -4, 10, 12$); body of caudate ($z = 2.72$; $x, y, z = 12, 6, 20$); a region near the tail of the caudate and hippocampus ($z = 3.67$; $x, y, z = 34, -40, 4$); supramarginal gyrus (BA 40; $z = 3.43$; $x, y, z = -54, -50, 32$); posterior insula ($z = 3.37$; $x, y, z = 30, -26, 4$); middle temporal gyrus (BA 21; $z = 3.31$; $x, y, z = -54, -60, 0$); putamen ($z = 3.29$; $x, y, z = -16, 16, 4$); cerebellar vermis ($z = 3.23$; $x, y, z = 4, -54, 0$); cerebellum ($z = 2.77$; $x, y, z = 12, -48, -12$); posterior thalamus ($z = 2.98$; $x, y, z = 22, -26, 8$); medial thalamus ($z = 2.78$; $x, y, z = -6, -12, 16$); and posterior cingulate gyrus ($z = 2.82$; $x, y, z = 6, -44, 8$). At the same threshold, motor tics were associated with activation in a region deep to inferior parietal and sensorimotor cortex ($z = 5.04$; $x, y, z = -40, -22, 28$); sensorimotor cortex (BAs 2, 4; $z = 3.96$; $x, y, z = -48, -22, 36$);

Table 1. Tic Scan Scores*

Scan No.	Subject No.					
	1	2	3	4	5	6
1	0.269	0.096	0.761	0.532	0.509	0.959
2	0.798	0.167	0.942	0.822	0.309	0.944
3	0.607	0.494	0.953	0.955	0.156	0.765
4	0.590	0.435	0.946	0.997	0.389	0.686
5	0.745	0.192	0.284	0.727	0.291	0.379
6	0.657	0.087	0.514	1.000	0.302	0.307
7	0.331	0.099	0.477	0.850	0.322	0.581
8	0.389	0.135	0.791	0.986	0.202	0.338
9	0.796	0.624	0.588	0.954	0.776	0.767
10	0.818	0.998	0.883	0.952	0.589	0.998
11	0.588	0.576	0.887	0.826	0.859	0.998
12	0.953	0.621	0.866	0.771	0.849	0.999

* Scan scores represent the radiotracer deposition during motor and vocal tics, hence the contribution of these events to the resultant image. These weighted scores constitute the covariate of interest in the group correlational analysis performed. See the "Image Acquisition, Processing, and Statistical Analysis" subsection of the "Subjects and Method" section, as well as Silbersweig et al.³⁶

superior temporal gyrus (BAs 42, 22; $z = 3.60$; $x, y, z = -56, -26, 16$); and somatosensory cortex (BA 2; $z = 2.70$; $x, y, z = -60, -22, 24$) (**Figure 2**). While the sensorimotor activations were on the left at this threshold, right-sided activations, as well as putamen activation, were seen at a lower threshold ($P < .01$, uncorrected) in this subject. It should be noted that, although the distribution differed, vocal tics occurred simultaneously with a subset of the motor tics in this subject, so one would not expect that these activations represent maps purely of vocal or motor tics. It should also be kept in mind that certain regions of activation may become apparent with the increased power of the group analysis, while other regions may be more specific to an individual analysis.

COMMENT

These results define a distributed neural system in which abnormal activity is associated with the spontaneous initiation of, or failure to suppress, motor and vocal behavioral repertoires in this group of TS patients. Prominent activity was noted in primary motor and Broca's areas, corresponding to the modality-specific outflow pathways of behavioral expression in motor and vocal tics. Striatal activity was also noted, supporting the involvement of basal ganglia circuits that are emphasized in traditional pathophysiological models of TS. The extensive activity in executive and premotor regions may be particularly notable, and may help to extend our understanding of disordered action and volition in TS, because these regions have traditionally been associated with the selection, preparation, and initiation of behavior.

Activity detected in the striatum can be seen in the context of cortico-striato-pallido-thalamo-cortical circuits that modulate activity in parallel brain systems underlying discrete psychomotor functions with specific functional and somatotopic organization.⁴¹ Within these circuits, the direct and indirect basal ganglia pathways provide a balance of excitation and inhibition⁴² that may

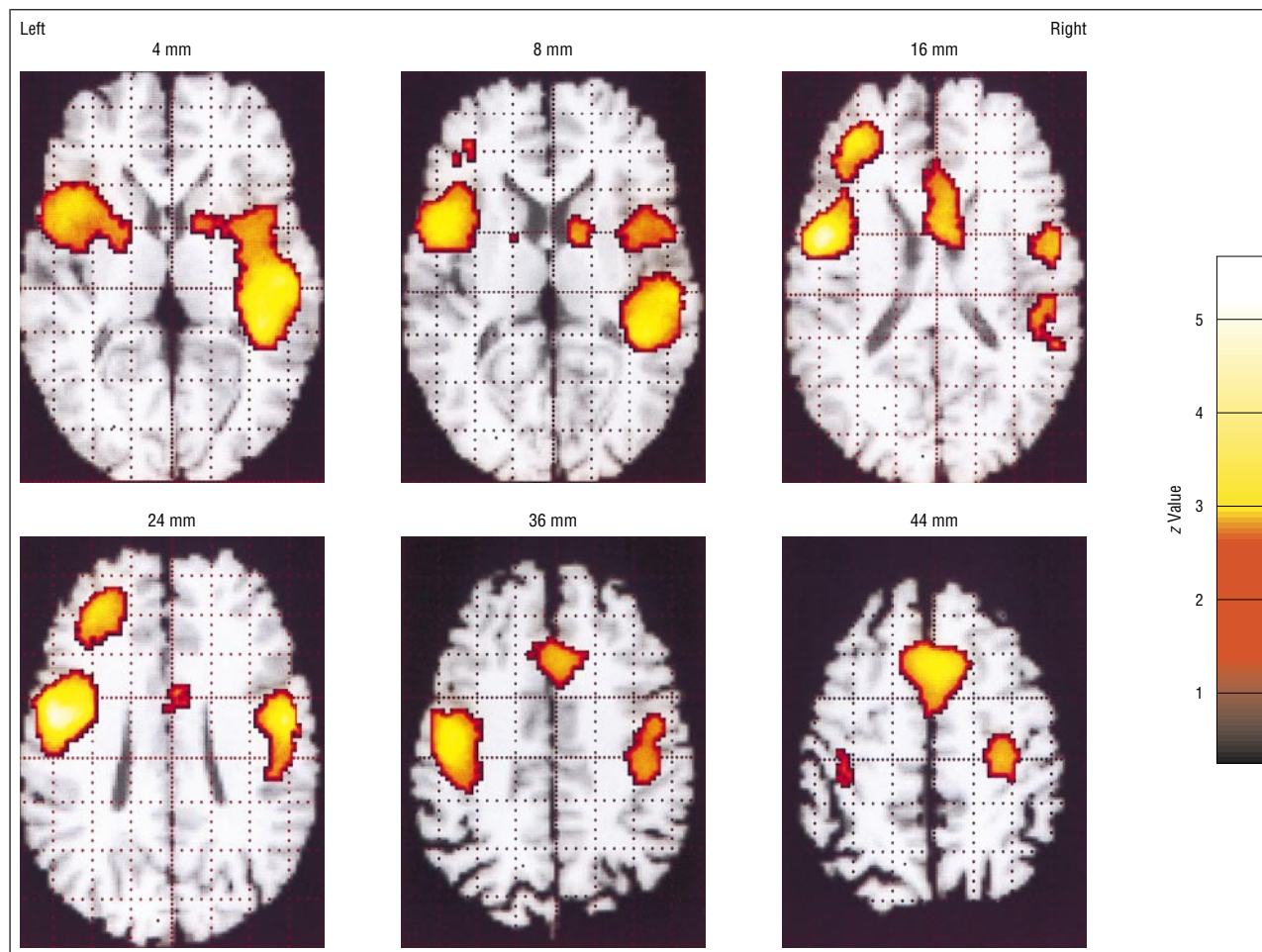


Figure 1. Stereotactic axial sections of brain areas with significantly increased activity during tics (motor and vocal) in 6 patients with Tourette syndrome. Functional positron emission tomography results (thresholded at $P < .005$, with spatial extent corrected for multiple comparisons at a threshold of $P < .05$) are displayed in color, superimposed on a single structural T1-weighted magnetic resonance imaging scan that has been transformed into the stereotactic coordinate space of Talairach and Tournoux³⁹ (for anatomical reference). Section numbers refer to the distance (in millimeters) from the anterior commissure–posterior commissure line, with positive numbers being superior to the line. The areas of maximal activation are described in the text and listed in Table 1.

be disrupted in TS. A failure of inhibition in motor cortex of TS patients, due to subcortical afferent disinhibition and/or to failure of intracortical inhibition, has been suggested by a transcranial magnetic stimulation study.⁴³ The findings of the current study implicate 3 of the cortico-striato-pallido-thalamo-cortical circuits in particular: the motor, dorsolateral prefrontal, and anterior cingulate circuits. These circuits are involved in the selection, programming, initiation, and control of movement.⁴⁴ Dopaminergic projections from the midbrain tegmentum, a region where activation was noted at a threshold of $P < .005$ (uncorrected), are involved in the modulation of these circuits.⁴¹ This modulation may provide a mechanism of symptom formation (excess dopamine) and treatment effect (dopamine blockade) in TS.²

For particular tics, the specific cortical and subcortical regions that are activated may determine the phenomenology of the behavior. In the individual analysis, coprolalia (which comprised more than 90% of the vocal tics) was associated with activation in the region of the Broca's area and the frontal operculum, known to be involved in the generation of speech. Activation was also noted in the head of the caudate, which has recently been

identified by lesion methods as a critical component of the network underlying language.⁴⁵ The other language regions noted (including posterior superior temporal gyrus, middle temporal gyrus, and supramarginal gyrus) may have been involved in the generation or the subsequent hearing of the self-generated linguistic material. Activation in the posterior cingulate gyrus has recently been described in association with emotional linguistic material.⁴⁶ The thalamic and cerebellar activations are consistent with the roles of these structures in modulating outflow of the cortical-subcortical circuits implicated. In contrast to the vocal tics, motor tics were associated with notable sensorimotor cortex activation. It is likely that activations of somatotopically specific subregions in sensorimotor cortices would be associated with movements in specific corresponding muscle groups.

Activity in anterior cingulate, premotor, and supplementary motor areas, and dorsolateral prefrontal cortex, detected in the current study, has been described in tasks involving conscious, volitional behavior, and is thought to be involved in the selection, preparation, and initiation of action.^{23,47-52} Activity in the supplementary motor area has also been noted in the performance of over-

learned (automatic) motor sequences.⁵³ Activation of medial premotor association cortices has been associated with self-generated movements and activation of lateral premotor association cortices has been associated with externally cued voluntary movements.⁵⁴ The striking activation of both medial and lateral premotor systems in this study suggests that both systems can be implicated in “unvoluntary” internally generated action. The involvement of the lateral premotor system may reflect the response to internal sensations, which are now known to be a common component of tics in TS.^{55,56} One study has reported a lack of normal premovement potentials associated with simple tics,⁵⁷ while another study found that premotor potentials were present during tics in some patients.⁵⁸ In either event, tics may differ from externally cued, planned movement in the timing, sequence, coherence, or distribution of premotor activity, and complex tics might be expected to involve more premotor activity than simple tics. A study of electroencephalogram microstates suggested differences between TS patients and normal subjects during simple and complex movements.⁵⁹ While the purpose of this study was to characterize the functional neuroanatomy of tics, future comparisons of tics vs volitional movements in TS patients, and of volitional movements in TS patients vs normal subjects, may help to clarify these issues.

The lesion and stimulation literature is also relevant to the interpretation of the findings in this study. Lesions or failure of activation of the medial frontal premotor system, prominently activated in this study, have been associated with the inability to initiate voluntary action.^{60,61} Conversely, stimulation of, or seizure activity in, these regions can produce complex vocal and motor automatisms (sometimes associated with urges and emotions) resembling tics. This is particularly the case with the anterior cingulate, which is part of the rostral limbic system, and integrates affective cues with executive functions for the selection of context-dependent behavior.^{23,62} The prominently activated insula is also involved in the integration of internal motivational states, with behavior appropriate for the extrapersonal world (entailing behavioral triggering or inhibition functions), in the imparting of affective tone to experience and behavior, and in somatosensory, linguistic, and self-generated motor functions.⁶³ Like the cingulate, it performs these roles by serving as a convergence point with widespread multimodal, limbic, and basal ganglia connections.⁶³ Dysfunction (including abnormal gating) in these phylogenetically older paralimbic regions may contribute to the primitive, uninhibited behavior of TS. The maxima of some of the activations in the insular region were centered on the claustrum. While such a small localization must be considered with caution, it is worth noting that the claustrum has connectivity with sensorimotor, premotor, and anterior cingulate regions, and is involved in the performance of movements.⁶⁴⁻⁶⁶

The predominantly dorsal location of anterior cingulate activation, rostral location of supplementary motor activation,⁶⁷ and dorsolateral location of prefrontal activation associated with tics in this study represents intermittent increased activity of executive components of the motor system (although supplementary motor cor-

Table 2. Local Statistical Maxima in the Pattern of Brain Activity During Tics in 6 Patients With Tourette Syndrome

Region (Brodmann Area)	x, y, z*	z Score
Left		
Precentral gyrus (4)	-46, -12, 28	5.82
Precentral gyrus (lateral 6)	-46, -4, 20	5.33
Middle frontal gyrus (lateral 6)	-44, 4, 12	4.93
Middle frontal gyrus (10)	-32, 40, 20	4.32
Superior frontal gyrus (9)	-26, 36, 28	3.76
Middle frontal gyrus (9/46)	-32, 32, 24	3.72
Clastrum/insula	-30, 10, 0	3.56
Inferior frontal gyrus (45)	-38, 26, 16	3.23
Putamen	-22, 2, 0	3.17
Inferior parietal lobule (40)	-34, -32, 40	3.02
Anterior cingulate gyrus (32)	-22, 20, 28	2.74
Right		
Precentral gyrus (4/6)	46, -8, 28	4.91
Caudate (tail), posterior insula†	36, -38, 4	4.72
Superior temporal gyrus (22)	46, -22, 4	4.72
	48, -36, 8	3.70
Insula	38, -26, 0	4.56
	38, 4, 8	3.13
Medial frontal gyrus (6)	0, 14, 44	4.43
Anterior cingulate (24)†	2, 4, 20	3.91
Anterior cingulate (32)	8, 16, 40	3.86
Inferior parietal lobule (40)	42, -28, 28	3.76
Caudate (head)	4, 12, 16	3.58
Postcentral gyrus (3)	28, -24, 44	3.47
Anterior thalamus/caudate (head)	10, 0, 8	3.26
Clastrum/insula	34, -2, 4	3.24

*Coordinates in millimeters relative to the anterior commissure: x is the lateral distance from the midline (positive = right); y, the anteroposterior distance from the anterior commissure (positive = anterior); and z, the height relative to the intercommissural line.

†Indicates the maximum coordinate in a brain region adjacent to a gray matter structure that is part of the same contiguous activation.

tex overall is considered premotor, and the cingulate also contains direct corticospinal projections²³). Executive dysfunction has been noted in neuropsychological tests of patients with TS.^{68,69} Tonic overactivity of frontal executive systems, coupled with hypoactivity in primary sensorimotor cortices, has been implicated in idiopathic dystonia, characterized by involuntary motor posturing and slowing.⁷⁰ Increased activity in orbitofrontal cortex and anterior cingulate cortex, and their subcortical connections (including the head of the caudate), has been implicated in obsessive-compulsive symptomatology,⁷¹ characterized by involuntary thoughts and complex actions, and seen with increased frequency in patients with TS.² Given the differential prefrontal projections to various regions of the striatum (premotor to putamen and prefrontal to head of caudate), it might be expected that putamen dysfunction would be associated with a greater degree of motor symptomatology, whereas caudate dysfunction would be associated with a greater degree of cognitive symptomatology.⁷²

The results of this “state” study of tics in TS may also be seen in the context of prior “trait” studies²⁵⁻³¹ of TS. When the variable results of the previous trait studies are taken together, they suggest a tonic dysregulation of a number of the regions in which increased activity was detected in this symptom-state examination.

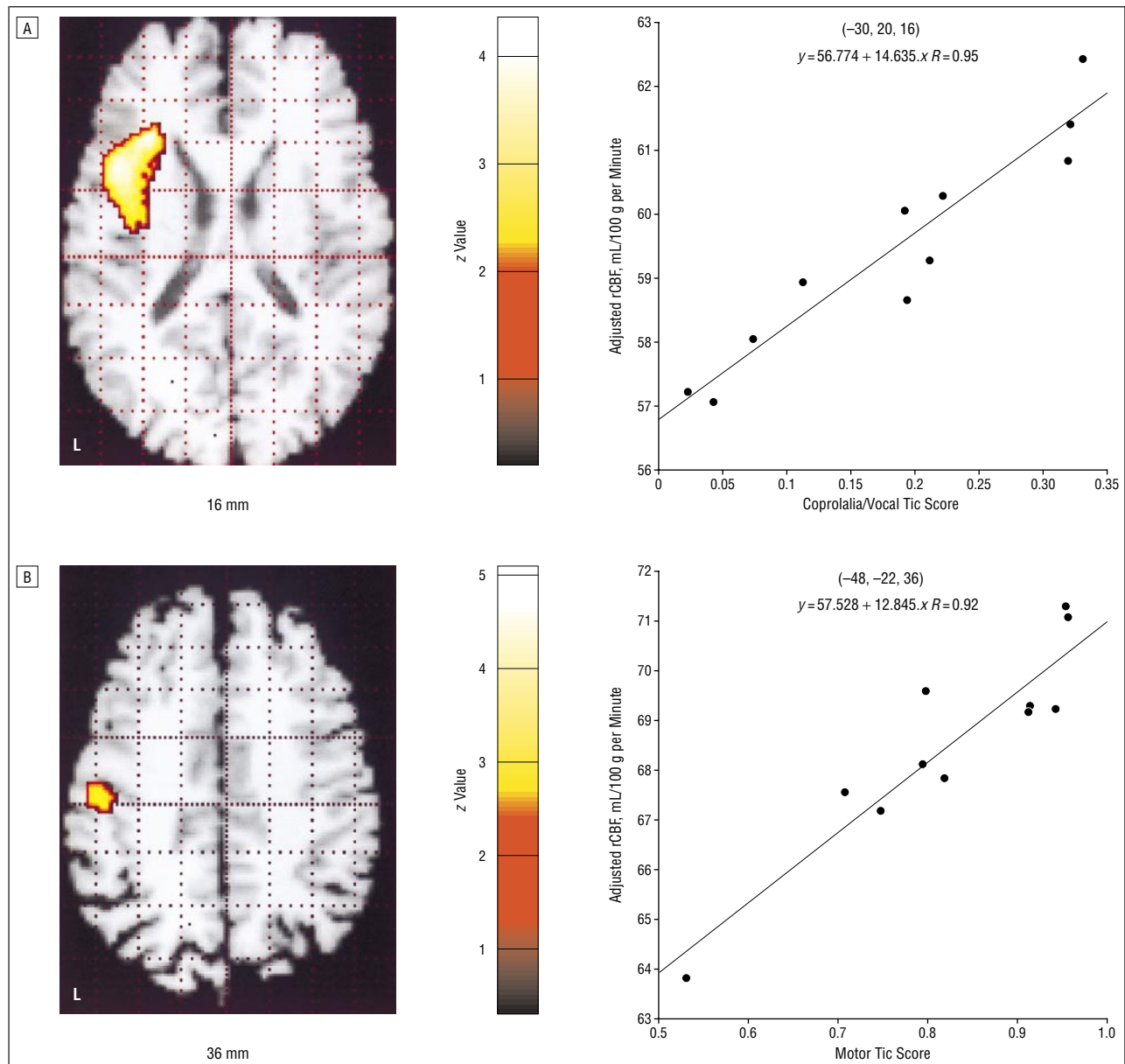


Figure 2. Correlations in a single patient with Tourette syndrome between regional cerebral blood flow (rCBF) and scan scores for coprolalia in the left frontal operculum/inferior frontal gyrus (A), and for motor tics in the left sensorimotor cortex (B). These activated regions (thresholded at $P < .001$, with spatial extent corrected for multiple comparisons at $P < .05$) are superimposed in color on axial slices from a stereotactically transformed structural magnetic resonance imaging template. L indicates left.

The decreased activity noted in some of the previous studies may reflect inhibition of tics during those study sessions³¹ (such inhibition is unlikely in the current study, as patients were reminded not to suppress tics before each scan and had frequent tics during each scan, with which brain activity was directly correlated). It is also possible that tonic decreased activity alternates with intermittent increased activity during tics in the regions implicated in TS. Although tics are not frank seizures, such a temporal pattern would be similar to that described in PET studies of epileptic foci,⁷³ and consistent with an imbalance of excitation and inhibition.

The results of this study may help to expand the interpretation of the results of a previous functional magnetic resonance imaging study that examined tic suppres-

sion in TS.³⁴ That study compared a condition in which tics were suppressed with a condition in which tics were expressed. The authors interpreted their findings with an emphasis on the issue of suppression, and make the reasonable suggestion that failure to inhibit tics in TS may result from an impaired ability to alter subcortical neuronal activity. While they noted that the higher rate of spontaneous tics in their control condition was a possible confounding factor, they felt that this was unlikely because they expected that the higher rate of tics would produce a greater change in magnetic resonance imaging signal intensity during successful tic suppression, and correlate positively (not negatively, as observed) with severity of tic symptoms (measured outside of the scanner). However, this would not be the case in regions active during both tics

and (possibly to a different degree in) their suppression. In the current study, tics were not suppressed, and were counted and characterized during the scans and differences in numbers of tics, and possibly urge, are not an issue. The results of these 2 studies can therefore be taken together, possibly suggesting that anterior cingulate and midfrontal activity is common to both tics and their suppression, and that putamen and sensorimotor cortex (motor outflow) activity is higher during tics and lower during suppression. While the pattern of increased activity noted in the current study could be primary, it is also quite possible that it could result from failure of inhibition.

Although these statistically significant results represent a sampling of hundreds of tics in 72 images from multiple subjects, the population studied is still relatively small, the analysis applies for just this group of subjects, and further studies will be necessary to replicate, extend, and assess the generalizability of these findings. Possible medication effect in 4 of the subjects also has to be considered as a potential limitation, although a number of points make this issue less likely to affect the results: the target symptom (tics), and therefore the neural firing underlying it, was active despite medication in the 4 medicated patients (2 were unmedicated); the analysis determines the variance induced by tics in a constant pharmacodynamic/pharmacokinetic setting over the course of the study session; and subject-specific effects, including medication and dosage (chlorpromazine equivalents), were partialled out in the analysis. Despite the 2 videotapes and throat microphone, it is possible that extremely subtle tics may have been missed, although patients with known severe, stereotypical tics were studied. Regarding timing, it should be kept in mind that the temporal discrimination achieved with this technique is not due to direct temporal resolution, the timing measures were to the nearest second, possible subcomponents of tics cannot be resolved, and it is not possible to say where the activation in the identified systems begins, or whether it occurs in parallel. Future analyses and studies can examine these issues, as well as similarities and differences between subtypes of tics, within and between individual unmedicated patients.

In conclusion, activity was noted specifically during tics in motor/vocalization, paralimbic, premotor, and executive frontal-subcortical brain systems. Autonomous activity in these regions may account for the striking motor and vocal acts of TS patients, and may contribute to the "unvoluntary" experience of an irresistible urge that often accompanies these acts. Indeed, tics may represent a paradoxical state in which brain regions important for motivational aspects of behavior, and normally associated with a subjective sense of volition as they initiate action, are not operating under the volitional control of the patient. This suggested systems-level pathophysiology of TS is consistent with observations of behavioral changes associated with lesions and stimulation in medial frontal regions, and these findings may contribute to a framework for future studies.

Accepted for publication February 11, 2000.

Supported in part by the DeWitt-Wallace Fund, New York Community Trust, New York (Drs Stern and Silber-

sweig) and the Wellcome Trust, London, England (Drs Dolan, Frackowiak, Frith, and Holmes).

Presented in part at the Second International Conference on Functional Mapping of the Human Brain, Boston, Mass, June 21, 1996.

We thank our colleagues in the MRC Cyclotron Unit (London, England) Physics and Methods sections for all of their assistance, the radiographers for their help in scanning, and the patients for participating in this study.

Reprints: Emily Stern, MD, Functional Neuroimaging Laboratory, Department of Psychiatry, Box 140, Room 1304, Weill Medical College of Cornell University, 525 E 68th St, New York, NY 10021.

REFERENCES

1. Robertson MM, Stern JS. The Gilles de la Tourette syndrome. *Crit Rev Neurobiol.* 1997;11:1-19.
2. Robertson MM. The Gilles de la Tourette syndrome: the current status. *Br J Psychiatry.* 1989;154:147-169.
3. Alsobrook JP II, Pauls DL. The genetics of Tourette syndrome. *Neurol Clin.* 1997; 15:381-393.
4. Brett PM, Curtis D, Robertson MM, Gurling HM. Neuroreceptor subunit genes and the genetic susceptibility to Gilles de la Tourette syndrome. *Biol Psychiatry.* 1997;42:941-947.
5. Allen AJ, Leonard HL, Swedo SE. Case study: a new infection-triggered, auto-immune subtype of pediatric OCD and Tourette's syndrome. *J Am Acad Child Adolesc Psychiatry.* 1995;34:307-311.
6. Murphy TK, Goodman WK, Fudge MW, Williams RC Jr, Ayoub EM, Dalal M, Lewis MH, Zabriskie JB. B lymphocyte antigen D8/17: a peripheral marker for childhood-onset obsessive-compulsive disorder and Tourette's syndrome? *Am J Psychiatry.* 1997;154:402-407.
7. Lange AE. Clinical phenomenology of tic disorders: selected aspects. In: Chase TN, Friedhoff AJ, Cohen DJ, eds. *Tourette Syndrome: Genetics, Neurobiology, and Treatment.* New York, NY: Raven Press; 1992:25-32.
8. Pulst SM, Walshe TM, Romero JA. Carbon monoxide poisoning with features of Gilles de la Tourette syndrome. *Arch Neurol.* 1983;40:443-444.
9. Wohlfart G, Ingvar DH, Hellberg AM. Compulsory shouting (Benedek's "klazomania") associated with oculogyric spasms in chronic epidemic encephalitis. *Acta Psychiatr Scand.* 1961;36:369-377.
10. Malison RT, McDougle CJ, van Dyck CH, Seahill L, Baldwin RM, Seibyl JP, Price LH, Leckman JF, Innis RB. [123I]Beta-CIT SPECT imaging of striatal dopamine transporter binding in Tourette's disorder. *Am J Psychiatry.* 1995;152:1359-1361.
11. Turjanski N, Sawle GV, Playford ED, Weeks R, Lammersma AA, Lees AJ, Brooks DJ. PET studies of the presynaptic and postsynaptic dopaminergic system in Tourette's syndrome. *J Neurol Neurosurg Psychiatry.* 1994;57:688-692.
12. Singer HS. Neurochemical analysis of postmortem cortical and striatal brain tissue in patients with Tourette syndrome. *Adv Neurol.* 1992;58:135-144.
13. Singer HS, Hahn IH, Moran TH. Abnormal dopamine uptake sites in postmortem striatum from patients with Tourette's syndrome. *Ann Neurol.* 1991;30:558-562.
14. Wolf SS, Jones DW, Knable MB, Gorey JG, Lee KS, Hyde TM, Coppola R, Weinberger DR. Tourette syndrome: prediction of phenotypic variation in monozygotic twins by caudate nucleus D2 receptor binding. *Science.* 1996;273:1225-1227.
15. Wong DF, Singer HS, Brandt J, Shaya E, Chen C, Brown J, Kimball AW, Gjedde A, Dannals RF, Ravert HT, Wilson PD, Wagner HN Jr. D2-like dopamine receptor density in Tourette syndrome measured by PET. *J Nucl Med.* 1997;38:1243-1247.
16. Haber SN, Kowall NW, Vonsattel JP, Bird ED, Richardson EP Jr. Gilles de la Tourette's syndrome: a postmortem neuropathological and immunohistochemical study. *J Neurol Sci.* 1986;75:225-241.
17. Singer HS, Hahn IH, Krowiak E, Nelson E, Moran T. Tourette's syndrome: a neurochemical analysis of postmortem cortical brain tissue. *Ann Neurol.* 1990;27: 443-446.
18. Singer HS, Dickson J, Martinie D, Levine M. Second messenger systems in Tourette's syndrome. *J Neurol Sci.* 1995;128:78-83.
19. Peterson B, Riddle MA, Cohen DJ, Katz LD, Smith JC, Hardin MT, Leckman JF. Reduced basal ganglia volumes in Tourette's syndrome using three-dimensional reconstruction techniques from magnetic resonance images. *Neurology.* 1993;43:941-949.
20. Singer HS, Reiss AL, Brown JE, Aylward EH, Shih B, Chee E, Harris EL, Reader

- MJ, Chase GA, Bryan RA. Volumetric MRI changes in basal ganglia of children with Tourette's syndrome. *Neurology*. 1993;43:950-956.
21. Hyde TM, Stacey ME, Coppola R, Handel SF, Rickler KC, Weinberger DR. Cerebral morphometric abnormalities in Tourette's syndrome: a quantitative MRI study of monozygotic twins. *Neurology*. 1995;45:1176-1182.
 22. Moriarty J, Varma AR, Stevens J, Fish M, Trimble MR, Robertson MM. A volumetric MRI study of Gilles de la Tourette's syndrome. *Neurology*. 1997;49:410-415.
 23. Devinsky O, Morrell MJ, Vogt BA. Contributions of anterior cingulate cortex to behaviour. *Brain*. 1995;118:279-306.
 24. Devinsky O. Neuroanatomy of Gilles de la Tourette's syndrome: possible mid-brain involvement. *Arch Neurol*. 1983;40:508-514.
 25. Chase TN, Geoffrey V, Gillespie M, Burrows GH. Structural and functional studies of Gilles de la Tourette syndrome. *Rev Neurol (Paris)*. 1986;142:851-855.
 26. George MS, Trimble MR, Costa DC, Robertson MM, Ring HA, Eil PJ. Elevated frontal cerebral blood flow in Gilles de la Tourette syndrome: a 99Tcm-HMPAO SPECT study. *Psychiatry Res*. 1992;45:143-151.
 27. Moriarty J, Costa DC, Schmitz B, Trimble MR, Eil PJ, Robertson MM. Brain perfusion abnormalities in Gilles de la Tourette's syndrome. *Br J Psychiatry*. 1995;167:249-254.
 28. Riddle MA, Rasmussen AM, Woods SW, Hoffer PB. SPECT imaging of cerebral blood flow in Tourette syndrome. *Adv Neurol*. 1992;58:207-211.
 29. Sawle GV, Lees AJ, Hymas NF, Brooks DJ, Frackowiak RS. The metabolic effects of limbic leucotomy in Gilles de la Tourette syndrome. *J Neurol Neurosurg Psychiatry*. 1993;56:1016-1019.
 30. Stoetter B, Braun AR, Randolph C, Gernert J, Carson RE, Herscovitch O, Chase TN. Functional neuroanatomy of Tourette syndrome: limbic-motor interactions studied with FDG PET. In: Chase TN, Friedhoff HA, Cohen DJ, eds. *Tourette Syndrome: Genetics, Neurobiology, and Treatment*. New York, NY: Raven Press; 1992: 213-226.
 31. Braun AR, Stoetter B, Randolph C, Hsiao JK, Vlader K, Gernert J, Carson RE, Herscovitch P, Chase TN. The functional neuroanatomy of Tourette's syndrome: an FDG-PET study. I: regional changes in cerebral glucose metabolism differentiating patients and controls. *Neuropsychopharmacology*. 1993;9:277-291.
 32. Klieger PS, Fett KA, Dimitropoulos T, Karlan R. Asymmetry of basal ganglia perfusion in Tourette's syndrome shown by technetium-99m-HMPAO SPECT. *J Nucl Med*. 1997;38:188-191.
 33. Eidelberg D, Moeller JR, Antonini A, Kazumata K, Dhawan V, Budman C, Feigin A. The metabolic anatomy of Tourette's syndrome. *Neurology*. 1997;48:927-934.
 34. Peterson BS, Skudlarski P, Anderson AW, Zhang H, Gatenby GC, Lacadie CM, Leckman JF, Gore JC. A functional magnetic resonance imaging study of tic suppression in Tourette syndrome. *Arch Gen Psychiatry*. 1998;55:326-333.
 35. Silbersweig DA, Stern E, Frith CD, Cahill C, Schnorr L, Grootoank S, Spinks T, Clark J, Frackowiak R, Jones T. Detection of thirty-second cognitive activations in single subjects with positron emission tomography: a new low-dose H₂(15)O regional cerebral blood flow three-dimensional imaging technique. *J Cereb Blood Flow Metab*. 1993;13:617-629.
 36. Silbersweig DA, Stern E, Schnorr L, Frith CD, Ashburner J, Cahill C, Frankowiak RS, Jones T. Imaging transient, randomly occurring neuropsychological events in single subjects with positron emission tomography: an event-related count rate correlational analysis. *J Cereb Blood Flow Metab*. 1994;14:771-782.
 37. Silbersweig DA, Stern E, Frith C, Cahill C, Holmes A, Grootoank S, Seaward J, McKenna P, Chua SE, Schnorr L, Jones T, Frackowiak RSJ. A functional neuroanatomy of hallucinations in schizophrenia. *Nature*. 1995;378:176-179.
 38. American Psychiatric Association. *Diagnostic and Statistical Manual of Mental Disorders, Fourth Edition*. Washington, DC: American Psychiatric Association; 1994.
 39. Talairach J, Tournoux P. *Co-Planar Stereotaxic Atlas of the Human Brain*. Stuttgart, Germany: Thieme Medical Publishers; 1988.
 40. Friston KJ, Holmes AP, Worsley KJ, Poline JP, Frith CD, Frackowiak RS. Statistical parametric maps in functional imaging: a general linear approach. *Hum Brain Mapp*. 1995;2:189-210.
 41. Alexander GE, De Long MR, Strick PL. Parallel organization of functionally segregated circuits linking basal ganglia and cortex. *Annu Rev Neurosci*. 1986;9: 357-381.
 42. Parent A, Hazrati LN. Functional anatomy of the basal ganglia, II: the place of subthalamic nucleus and external pallidum in basal ganglia circuitry. *Brain Res Brain Res Rev*. 1995;20:128-154.
 43. Ziemann U, Paulus W, Rothenberger A. Decreased motor inhibition in Tourette's disorder: evidence from transcranial magnetic stimulation. *Am J Psychiatry*. 1997;154:1277-1284.
 44. Parent A, Hazrati LN. Functional anatomy of the basal ganglia, I: the cortico-basal ganglia-thalamo-cortical loop. *Brain Res Brain Res Rev*. 1995;20:91-127.
 45. Damasio H, Damasio AR. *Lesion Analysis in Neuropsychology*. New York, NY: Oxford University Press; 1989:38-39.
 46. Madoock RJ. The retrosplenial cortex and emotion: new insights from functional neuroimaging of the human brain. *Trends Neurosci*. 1999;22:310-316.
 47. Roland PE, Larsen B, Lassen NA, Skinhoj E. Supplementary motor area and other cortical areas in organization of voluntary movements in man. *J Neurophysiol*. 1980;43:118-136.
 48. Deiber MP, Passingham RE, Colebatch JG, Friston KJ, Nixon PD, Frackowiak RS. Cortical areas and the selection of movement: a study with positron emission tomography. *Exp Brain Res*. 1991;84:393-402.
 49. Frith CD, Friston K, Liddle PF, Frackowiak RSJ. Willed action and the prefrontal cortex in man: a study with PET. *Proc R Soc Lond B Biol Sci*. 1991;244:241-246.
 50. Posner MI. Attention: the mechanisms of consciousness. *Proc Natl Acad Sci U S A*. 1994;91:7398-7403.
 51. Goldman-Rakic PS. Changing concepts of cortical connectivity: parallel distributed cortical networks. In: Rakic P, Singer W, eds. *Neurobiology of Neocortex*. New York, NY: John Wiley & Sons Inc; 1988:177-202.
 52. Buckner RL, Raichle ME, Petersen SE. Dissociation of human prefrontal cortical areas across different speech production tasks and gender groups. *J Neurophysiol*. 1995;74:2163-2173.
 53. Jenkins IH, Brooks DJ, Nixon PD, Frackowiak RS, Passingham RE. Motor sequence learning: a study with positron emission tomography. *J Neurosci*. 1994; 14:3775-3790.
 54. Colebatch JG, Deiber MP, Passingham RE, Friston KJ, Frackowiak RS. Regional cerebral blood flow during voluntary arm and hand movements in human subjects. *J Neurophysiol*. 1991;65:1392-1401.
 55. Scahill LD, Leckman JF, Marek KL. Sensory phenomena in Tourette's syndrome. *Adv Neurol*. 1995;65:273-280.
 56. Chee KY, Sachdev P. A controlled study of sensory tics in Gilles de la Tourette syndrome and obsessive-compulsive disorder using a structured interview. *J Neurol Neurosurg Psychiatry*. 1997;62:188-192.
 57. Obeso JA, Rothwell JC, Marsden CD. Simple tics in Gilles de la Tourette's syndrome are not prefaced by a normal pre-movement potential. *J Neurol Neurosurg Psychiatry*. 1981;44:735-738.
 58. Karp BI, Porter S, Toro C, Hallett M. Simple motor tics may be preceded by a premotor potential. *J Neurol Neurosurg Psychiatry*. 1996;61:103-106.
 59. Stevens A, Gunther W, Lutzenberger W, Bartels M, Muller N. Abnormal topography of EEG microstates in Gilles de la Tourette syndrome. *Eur Arch Psychiatry Clin Neurosci*. 1996;246:310-316.
 60. Laplane D, Talairach J. Clinical consequences of corticectomies involving the supplementary motor area in man. *J Neurol Sci*. 1977;34:301-314.
 61. Playford ED, Jenkins IH, Passingham RE, Nutt J, Frackowiak RS, Brooks DJ. Impaired mesial frontal and putamen activation in Parkinson's disease: a positron emission tomography study. *Ann Neurol*. 1992;32:151-161.
 62. Vogt BA, Finch DM, Olson CR. Functional heterogeneity in cingulate cortex: the anterior executive and posterior evaluative regions. *Cereb Cortex*. 1992;2:435-443.
 63. Mesulam MM. The insula of Reil in monkey and man: cytoarchitectonics, connectivity and function. In: Peters A, Jones EG, eds. *The Cerebral Cortex*. New York, NY: Plenum Press; 1984:179-226.
 64. Kowianski P, Dziewiatkowski J, Berdel B, Lipowska M, Morys J. The cortico-claustral connections in the rat studied by means of the fluorescent retrograde axonal transport method. *Folia Morphol (Warsz)*. 1998;57:85-92.
 65. Buchanan SL, Thompson RH, Maxwell BL, Powell DA. Efferent connections of the medial prefrontal cortex in the rabbit. *Exp Brain Res*. 1994;100:469-483.
 66. Shima K, Hoshi E, Tanji J. Neuronal activity in the claustrum of the monkey during performance of multiple movements. *J Neurophysiol*. 1996;76:2115-2119.
 67. Stephan KM, Fink GR, Passingham RE, Silbersweig D, Ceballos-Baumann AO, Frith CD, Frackowiak RS. Functional anatomy of the mental representation of upper extremity movements in healthy subjects. *J Neurophysiol*. 1995;73:373-386.
 68. Harris EL, Schuerholz LJ, Singer HS, Reader MJ, Brown JE, Cox C, Mohr J, Chase GA, Denckla MB. Executive function in children with Tourette syndrome and/or attention deficit hyperactivity disorder. *J Int Neuropsychol Soc*. 1995;1:511-516.
 69. Schuerholz LJ, Baumgardner TL, Singer HS, Reiss AL, Denckla MB. Neuropsychological status of children with Tourette's syndrome with and without attention deficit hyperactivity disorder. *Neurology*. 1996;46:958-965.
 70. Ceballos-Baumann AO, Passingham RE, Warner T, Playford ED, Marsden CD, Brooks DJ. Overactive prefrontal and underactive motor cortical areas in idiopathic dystonia. *Ann Neurol*. 1995;37:363-372.
 71. Saxena S, Brody AL, Schwartz JM, Baxter LR Jr. Neuroimaging and frontal-subcortical circuitry in obsessive-compulsive disorder. *Br J Psychiatry*. 1998; 35:26-37.
 72. Cummings JL, Benson F. Subcortical mechanisms and human thought. In: Cummings JL, ed. *Subcortical Dementia*. New York, NY: Oxford University Press; 1990: 251-259.
 73. Kuhl DE, Engel J Jr, Phelps ME, Selin C. Epileptic patterns of local cerebral metabolism and perfusion in humans determined by emission computed tomography of 18FDG and 13NH₃. *Ann Neurol*. 1980;8:348-360.