

The Mind's Eye—Precuneus Activation in Memory-Related Imagery

P. C. FLETCHER,*† C. D. FRITH,*‡ S. C. BAKER,* T. SHALLICE,‡ R. S. J. FRACKOWIAK,* AND R. J. DOLAN*†¹

*Wellcome Department of Cognitive Neurology, Institute of Neurology, Queen Square, London, WC1N 3BG and MRC Cyclotron Unit, Hammersmith Hospital, Duane Road, London W12 0HS, United Kingdom; †Royal Free Hospital School of Medicine, Roland Hill Street, London, NW3, United Kingdom; and ‡Department of Psychology, University College London, Gower Street, London, WC1E 6BT, United Kingdom

Received April 17, 1995

We examined brain activity associated with visual imagery at episodic memory retrieval using positron emission tomography (PET). Twelve measurements of regional cerebral blood flow (rCBF) were taken in six right-handed, healthy, male volunteers. During six measurements, they were engaged in the cued recall of *imageable* verbal paired associates. During the other six measurements, they recalled *nonimageable* paired associates. Memory performance was equalized across all word lists. The subjects' use of an increased degree of visual imagery during the recall of imageable paired associates was confirmed using subjective rating scales after each scan. Memory-related imagery was associated with significant activation of a medial parietal area, the precuneus. This finding confirms a previously stated hypothesis about the precuneus and provides strong evidence that it is a key part of the neural substrate of visual imagery occurring in conscious memory recall. © 1995 Academic Press, Inc.

INTRODUCTION

Cognitive operations such as memory, planning, and problem solving involve mental imagery. Conscious visual imagery is typically present during episodic recall (Tulving, 1983; Furlong, 1951). Episodic memory refers to memory for episodes, memory which has autobiographical reference (Tulving, 1983). It can be distinguished from semantic memory which refers to our knowledge about the world. Semantic memory has cognitive but not autobiographical reference. In an earlier functional imaging experiment, we measured rCBF in volunteers during cued recall of word pairs (each pair comprising a category paired with a relevant exemplar, e.g., "poet . . . Browning") which they had been presented with 5 min prior to scanning. This was deemed to be an episodic memory task as it necessitated the

recall of a specific exemplar in response to a category cue. The subjects' ability to respond depended upon them being able to recall which exemplar had been paired with a given category during the prescan period. A control, semantic memory task involved presentation of previously unseen category cues during scanning. The subject was required to respond with any appropriate exemplar, no episodic recall being necessary. In this study, we noted activation of the precuneus during episodic, but not semantic, memory recall tasks (Shallice *et al.*, 1994; Fletcher *et al.*, 1995).

The present study explicitly tested our hypothesis that imagery in episodic recall leads to precuneus activation. We used the same paradigm for episodic memory retrieval, i.e., cued recall of paired associates. In this experiment, however, we did not include a semantic memory task. Instead, two types of episodic retrieval were examined: The recall of strongly imageable paired associates and the recall of weakly imageable paired associates. Within both sets, there was a graded variation of the strength of semantic relationship between the pairs. The usefulness of this variation is described below. In essence, the term semantic distance, as used in this study, refers to the strength of association between the members of a given pair. A smaller semantic distance indicates a stronger association (e.g., king . . . queen). A greater distance indicates a weaker association (e.g., vegetable . . . carrot). As an index of the strength of association between items, we used a previous study measuring the likelihood that subjects, when cued with the first item, would respond with the second (Palermo and Jenkins, 1964).

METHOD

Six right-handed male subjects took part in the study, which was approved by the local hospital ethics committee and ARSAC (UK). Each subject received six lists of strongly imageable and six lists of weakly imageable paired associates. Words varied in terms of imageability according to the Quinlan Oxford Psycho-

¹ To whom correspondence and reprint requests should be addressed at Wellcome Department of Cognitive Neurology, Institute of Neurology, Queen Square, London, WC1N 3BG, United Kingdom.

linguistic database (Quinlan, 1992). Words with an imagery rating >450 were defined as imageable (e.g., "car . . . truck"). Words with an imagery rating <300 were defined as nonimageable (e.g., "come . . . go").

Lists were presented 5 min prior to scanning and the interval between presentation and the rCBF measurement was filled. To control for semantic distance between the items in the pairs, words used were rated on scale of 1 (close relationship) to 6 (distant) (Palermo and Jenkins, 1964) and equal numbers of pairs of each value were used for the high and low imagery conditions. Highly imageable items should be more easily recalled (Baddeley, 1991) and, on the basis of pilot testing, subjects received two or more presentations of the more difficult lists (i.e., those of low imageability and those of greater semantic distance) in order to equalize recall performance across all 12 conditions. This meant that, within the six imageable study sets and the six nonimageable study sets, there was systematic variability in the amount of prescan rehearsal so that subsequent variability of performance during the scanning period was not a confounding factor. This aspect of the study design is summarized in Table 1. It produced a range of variability in the degree of lists novelty which could subsequently be covaried out in the data analysis. The order of lists was varied to minimize habituation effects.

PET Scanning

Scans were obtained using a CTI Model 953B PET Scanner (CTI, Knoxville, TN) with collimating septa retracted. Volunteers received a 20s intravenous bolus of $H_2^{15}O$ at a concentration of 55 MBq ml^{-1} and a flow rate of 10 $ml\ min^{-1}$ through a forearm cannula.

Data Analysis

The data were analyzed with statistical parametric mapping (using software from the Wellcome Depart-

ment of Cognitive Neurology, London, UK) implemented in Matlab (Mathworks Inc., Sherborn MA). Statistical parametric mapping combines the general linear model (to create the statistical parametric map or SPM) and the theory of Gaussian fields to make statistical inferences about regional effects (Friston *et al.*, 1991, 1994; Worsley *et al.*, 1992).

The scans from each subject were realigned using the first as reference. The six parameters of this rigid body transformation were estimated using a least squares approach (Friston *et al.*, 1995a). Following realignment, all images were transformed into a standard space (Talairach and Tournoux, 1988). This normalizing spatial transformation matches each scan to a reference template image that already conforms to the standard space (Friston *et al.*, 1995a). As a final preprocessing step, the images were smoothed using an isotropic Gaussian kernel. The condition, subject, and covariate effects were estimated according to the general linear model at each voxel (Friston *et al.*, 1995b). To test hypotheses about regionally specific condition effects, the estimates were compared using linear compounds or contrasts. The resulting set of voxel values for each contrast constitute a statistical parametric map of the *t* statistic, SPMt. The SPMt were transformed to the unit normal distribution (SPMZ) and thresholded at 3.09 (or $P = 0.001$ uncorrected).

RESULTS

Psychological Performance

Performance data and subjective ratings of imagery during recall tasks are summarized in Table 2. Ratings of imagery differ greatly across the two types of list. No significant difference in performance was found.

PET Results

In view of our specific anatomical hypothesis, we constrained our initial analysis to regions that were previously demonstrated to be involved in episodic memory recall (Fig. 1a). This approach, of interrogating a limited subset of voxels, constitutes a statistically more rigorous analysis of the current data than an examination of the whole voxel population. The similarity of the paradigm for episodic retrieval (i.e., cued word recall) in both the previous and the current experiment means that the mask defines an appropriate subset of voxels for the comparison.

In the comparison of scans recorded during recall of imageable versus nonimageable paired associates there was a highly significant activation of the precuneus (Fig. 1b). This significant activation was also evident in an unmasked comparison. In the unmasked comparison additional activations were evident in the right fusiform gyrus and the middle/superior temporal gyri bilaterally. The coordinates of these foci of activa-

TABLE 1

Strongly imageable paired associates		Weakly imageable paired associates	
Semantic distance	No. of prescan presentations ^a	Semantic distance	No. of prescan presentations ^a
1	1	1	1
2	1	2	2
3	2	3	3
4	2	4	3
5	3	5	4
6	4	6	8

^a Scanning data were analyzed treating this range of values as a covariate whose influence could be removed. The number of prescan presentations to equalize performance across the range of strongly/weakly imageable, semantically distant/close pairs was empirically determined by pilot testing.

TABLE 2
Performance and Imagery Ratings

List ^a	Performance			Subjective rating ^b		
	High imagery	Low imagery		High imagery	Low imagery	
1	10.7 ± 1.0	11.3 ± 0.8	NS	5 ± 1.2	1.6 ± 0.9	<i>P</i> < 0.01
2	10 ± 1.8	8.7 ± 1.4	NS	5 ± 2.2	2 ± 1	<i>P</i> < 0.05
3	9.2 ± 1.9	9.2 ± 1.9	NS	5.4 ± 1.3	3 ± 1.9	<i>P</i> < 0.05
4	10.2 ± 1.8	9.3 ± 0.8	NS	5.2 ± 1.9	2.6 ± 1.5	<i>P</i> < 0.05
5	8.8 ± 2.1	9.2 ± 1	NS	4.4 ± 0.9	2.8 ± 1.8	<i>P</i> < 0.05
6	8.8 ± 1.2	9.5 ± 2.1	NS	5.6 ± 1.7	1.4 ± 0.5	<i>P</i> < 0.01

^a Pairs in each list were matched for the strength of association between members of the pair⁴. The lists varied from 1 (strong relatedness) to 6 (weak relatedness). Performance across varying semantic distance was equalized by giving subjects repeat presentations of the more weakly related pairs.

^b Imagery was rated in two ways at the completion of each of the 12 scans: Subjects were asked to rate, on a scale of 1 to 7, the strength of imagery used during the recall of the list of paired associates. Subjects were asked to rate, on a scale of 1 to 7, the frequency with which they used imagery as a mnemonic strategy during recall. In the table, an average of the two ratings has been recorded.

tion are summarized in Table 3. A right prefrontal activation, evident in our previous study of episodic recall (Shallice *et al.*, 1994), was not present in any of the current comparisons. This confirms that our experimental design achieved equal engagement of episodic retrieval processes mediated by this region for both the imageable and the nonimageable items.

Activation of the precuneus was present in the Imageable vs NonImageable comparison after covarying out the effects on rCBF of list novelty.

DISCUSSION

Both tasks involved the cued recall of paired associates, which, as we have previously shown, activates the right prefrontal cortex and the precuneus (Shallice *et al.*, 1994). The present study sought to test the hypothesis that precuneus activation arises from the use of visual imagery to aid memory retrieval.

Imageable and semantically close items are more easily recalled than nonimageable and semantically distant items. However, differences in precuneus or other regional CBF between the conditions cannot be confounded by differential performance, since this was equalized by repeat pretest presentations of lists. Nor could differences in list novelty explain the finding for the reasons stated above.

Our crucial finding is the activation of precuneus resulting from a difference in imagery used during retrieval. The precuneus is a medial parietal brain region situated superior and posterior to the retrosplenial area of the cingulate cortex. Its anatomical connections are widespread and include the prefrontal cortex (Goldman-Rakic, 1988; Petrides and Pandya, 1984), the temporal and occipital cortices, and the thalamus (Blum *et al.*, 1950). Activation confirms our prediction, based on previous studies of an involvement of precu-

neus in imagery processes (Grasby *et al.*, 1993; Shallice *et al.*, 1994). The precuneus has also been activated in PET memory experiments reported by other groups (Petrides *et al.*, 1993; Tulving *et al.*, 1994). These experiments all addressed episodic memory which almost invariably engages imagery.

Neurological case studies imply a distinct neural architecture for visual imagery and visual perception, a contention which finds support in the neurological literature (Roland and Gulyás, 1994). Clinical case reports provide evidence that the processes of visual imagery, visual knowledge, and visual perception are dissociable (Levine *et al.*, 1985; Behrmann *et al.*, 1992; Riddoch, 1990; Farah *et al.*, 1988). Impairment of visual imagery can be seen in patients with selective brain injury. Consistent with our evidence of precuneus activation is the finding that deficits of imagery are associated with posterior cortical lesions.

A critical question about visual imagery is whether visual image generation also requires activation of areas involved in visual perception. Although visual imagery is defined as the generation of mental representations that share many features with veridical visual percepts (Kosslyn, 1994), there are important distinctions between the two processes. For example, imagery requires conscious manipulation or "top-down" processing, whereas perceptual experience is to a large extent obligatory or "bottom-up." Our finding of activation of the precuneus, without activation of early visual processing areas, implies that image generation does not necessarily require activation of primary perceptual areas. However, the observed activation of the fusiform gyri, in addition to the precuneus, observed in our more extensive exploration of the unmasked data, suggests that extrastriate visual areas have a role in visual imagery. Results from our previous study of episodic memory retrieval, which involved imageable words in both experimental and control tasks, did not activate fusiform or parietotemporal re-

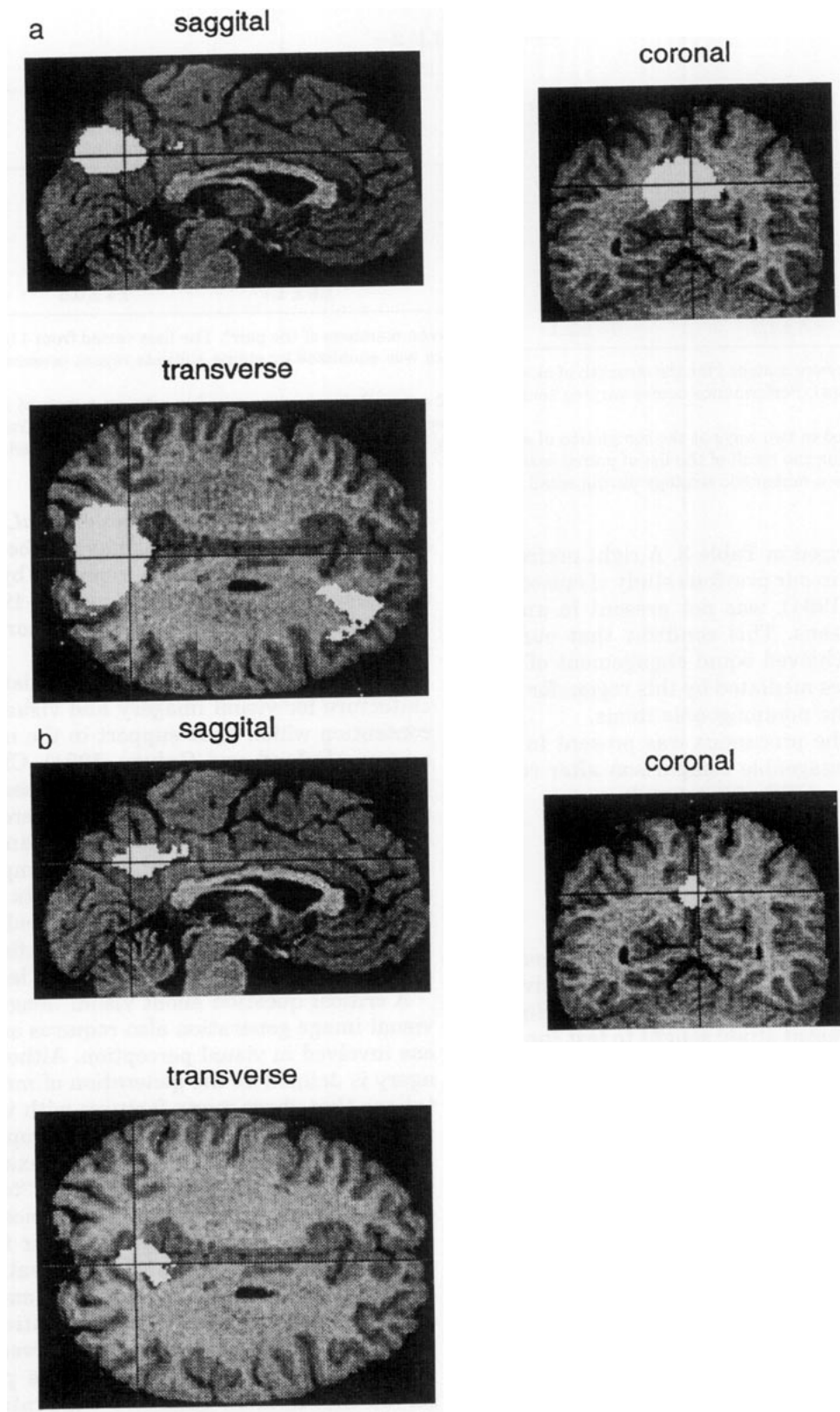


FIG. 1. Regions significantly activated during: (a) the cued retrieval of paired associates from episodic memory compared to retrieval from semantic memory ($P < 0.001$). Data come from a previous experiment (Shallice *et al.*, 1994) and show activation of the right prefrontal cortex and the precuneus. (b) The region within this system which is significantly activated when we compare the retrieval of highly imageable paired associates from episodic memory to the retrieval of poorly imaged paired associates: the precuneus ($P < 0.001$). The images are SPMS displayed from the right (sagittal), the back (coronal), and the top (transverse) of the brain. Areas of activation are superimposed onto averaged MRI scans rendered into the same stereotactic space (Talairach *et al.*, 1988).

TABLE 3
High vs Low Imagery

Area	x^a	y^a	z^a	Z score
Precuneus	6	-46	36	3.47
	2	-58	32	3.32
	-2	-54	32	3.21
<i>R. superior temporal gyrus</i>	42	-58	16	3.36
<i>L. anterior cingulate</i>	-12	38	0	3.7
<i>R. fusiform gyrus</i>	42	-26	-16	3.72

Note. Areas which showed activation in the unmasked but not in the masked comparison are shown in italics. The precuneus was seen to be significantly activated in both the masked and the unmasked comparisons.

^a x , y , z are coordinates relative to standard stereotactic space (Talairach *et al.*, 1988). The table shows locations and Z values after covarying out the effects of item novelty.

gions, despite subjects' reports that they utilized imagery as a recall strategy in the retrieval condition. One NEW possibility, therefore, is that these regions are automatically activated by imageable words, but that the precuneus is required for conscious visual imagery (in this case, in the context of retrieval) functioning as "the mind's eye."

Some, but not all, previous functional imaging studies of complex, multicomponent tasks which involve imagery report activation of parietooccipital and temporooccipital cortex but not of primary visual areas (Roland and Gulyás, 1994). Activation of early visual processing areas has been reported particularly in studies where a feature of the experimental paradigms is selective attention to components of the generated images (Roland and Friberg, 1985; Kosslyn *et al.*, 1993). The contrasting findings may depend upon whether the images are perceptually or memory based (Jeannerod, 1994). The present study was purely memory based and did not require attention to any component of the generated image during recall. Imagery is not a unitary process (Kosslyn, 1988) and we would predict that attention to, for example, spatial features or other specific components of a generated image would coactivate associated functionally specialized prestriate regions. Thus we would caution that the activation of the precuneus in the present study does not imply that it is the sole region involved in mental imagery. Our findings do suggest that generation of a coherent image is instantiated through activation of the precuneus which, in this respect, may subserve the function of a visual imagery buffer (Farah, 1984).

REFERENCES

- Baddeley, A. D. 1991. *Human Memory: Theory and Practice*, pp. 97-116. Erlbaum, Hove and London.
- Behrmann, M., Winocur, G., and Moscovitch, M. 1992. Dissociation between mental imagery and object recognition in a brain-damaged patient. *Nature* **359**: 636-637.
- Blum, J. S., Chow, K. L., and Pribram, K. H. 1950. A behavioural analysis of the organization of the parieto-temporo-preoccipital cortex. *J. Comp. Neurol.* **93**: 53-100.
- Farah, M. 1984. The neurological basis of mental imagery: A componential analysis. *Cognition* **18**: 245-272.
- Farah, M. J., Levine, D. N., and Calvanio, R. 1988. A case study of mental imagery deficiency. *Brain Cog.* **8**: 147-164.
- Fletcher, P. C., Frith, C. D., Grasby, P. M., Shallice, T., Frackowiak, R. S. J., and Dolan, R. J. 1995. Brain systems for encoding and retrieval of auditory-verbal memory: An in vivo study in humans. *Brain* **118**: 401-416.
- Friston, K. J., Frith, C. D., Liddle, P. F., and Frackowiak, R. S. J. 1991. Comparing functional (PET) images: The assessment of significant change. *J. Cereb. Blood Flow Metab.* **11**: 690-699.
- Friston, K. J., Worsley, K. J., Frackowiak, R. S. J., Mazziotta, J. C., and Evans, A. C. 1994. Assessing the significance of focal activations using their spatial extent. *Human Brain Mapping* **1**: 214-220.
- Friston, K. J., Ashburner, J., Poline, J. B., Frith, C. D., Heather, J. D., and Frackowiak, R. S. J. 1995a. Spatial realignment and normalization of images. Submitted for publication.
- Friston, K. J., Holmes, A. P., Worsley, K. J., Poline, J. B., Frith, C. D., and Frackowiak, R. S. J. 1995b. Statistical parametric maps in functional imaging: A general approach. Submitted for publication.
- Furlong, E. 1951. *A Study in Memory*. T. Nelson, London.
- Goldman-Rakic, P. S. 1988. Topography of cognition: Parallel distributed networks in primate association cortex. *Annu Rev. Neurosci.* **11**: 137-156.
- Grasby, P. M., Frith, C. D., Friston, K. J., Bench, C., Frackowiak, R. S. J., and Dolan, R. J. 1993. Functional mapping of brain areas implicated in auditory-verbal memory function. *Brain* **116**: 1-20.
- Jeannerod, M. 1994. The representing brain: Neural correlates of motor intention and imagery. *Behav. Brain Sci.* **17**: 187-245.
- Kosslyn, S. M. 1988. Aspects of a cognitive neuroscience of mental imagery. *Science* **240**: 1621-1626.
- Kosslyn, S. M. 1994. *Image and Brain*. M.I.T. Press, Boston.
- Kosslyn, S. M., Alpert, N. M., Thompson, W. L., *et al.* 1993. Visual mental imagery activates topographically organized visual cortex: PET investigations. *J. Cog. Neurosci.* **5**: 263-287.
- Levine, D. N., Warach, J., and Farah, M. J. 1985. Two visual systems in mental imagery: Dissociation of "what" and "where" in imagery disorders due to bilateral posterior cerebral lesions. *Neurology* **35**: 1010-1018.
- Palermo, D. S., and Jenkins, J. J. 1964. *Word Association Norms: Grade School Through College*. Univ. of Minnesota Press, Minneapolis.
- Petrides, M., and Pandya, D. N. 1984. Projections to the frontal cortex from the posterior parietal region in the rhesus monkey. *J. Comp. Neurol.* **228**: 105-116.
- Petrides, M., Alivisatos, B., Meyer, E., and Evans, A. C. 1993. Functional activation of the human frontal cortex during the performance of verbal working memory tasks. *Proc. Natl. Acad. Sci. USA* **90**: 878-882.
- Quinlan, P. T. 1992. *The Oxford Psycholinguistic Database*. Oxford Univ. Press, Oxford.
- Riddoch, M. J. 1990. Neglect and the peripheral dyslexias. *Cog. Neuropsychol.* **7**(5/6): 369-390.

- Roland, P. E., and Friberg, L. 1985. Localization of cortical areas activated by thinking. *J. Neurophysiol.* **53**: 1219–1243.
- Roland, P. E., and Gulyás, B. 1994. Visual imagery and visual representation. *TINS* **17**(7): 281–287.
- Shallice, T., Fletcher, P., Frith, C. D., Grasby, P., Frackowiak, R. S. J., and Dolan, R. J. 1994. Brain regions associated with acquisition and retrieval of verbal episodic memory. *Nature* **368**: 633–635.
- Talairach, J., and Tournoux, P. 1988. *Co-planar Stereotactic Atlas of the Human Brain*. Thieme Verlag, Stuttgart.
- Tulving, E. 1983. *Elements of Episodic Memory*. Oxford Science Publications, Oxford.
- Tulving, E., Kapur, S., Markowitsch, H. J., Craik, F. I. M., Habib, R., and Houle, S. 1994. Neuroanatomical correlates of retrieval in episodic memory: Auditory sentence recognition. *Proc. Natl. Acad. Sci. USA* **91**: 2012–2015.
- Worsley, K. J., Evans, A. C., Marrett, S., and Neelin, P. 1992. A three-dimensional statistical analysis for rCBF activations studies in human brain. *J. Cereb. Blood Flow Metab.* **12**: 900–918.