



# Reorganization and Plasticity of the Language Network in Patients with Cerebral Gliomas

Laura Nieberlein<sup>a,\*</sup>, Stefan Rampp<sup>b,d</sup>, Alexander Gussev<sup>c</sup>, Julian Prell<sup>b</sup>, Gesa Hartwigsen<sup>a,e</sup>

<sup>a</sup> Lise Meitner Research Group Cognition and Plasticity, Max Planck Institute for Human Cognitive and Brain Sciences, Leipzig, Germany

<sup>b</sup> Department of Neurosurgery, University Hospital Halle (Saale), Germany

<sup>c</sup> Department of Medical Physics, University Hospital Halle (Saale), Germany

<sup>d</sup> Department of Neurosurgery, University Hospital Erlangen, Germany

<sup>e</sup> Wilhelm Wundt Institute for Psychology, Leipzig University, Germany

## ARTICLE INFO

### Keywords:

Tumor  
Brain lesion  
Resection  
Speech  
Brain surgery  
fMRI  
MEG  
EEG  
Direct electrical brain stimulation  
Transcranial magnetic stimulation

## ABSTRACT

Language is organized in large-scale networks in the human brain that show a strong potential for flexible interactions and adaptation. Neuroplasticity is the central mechanism that allows such dynamic modulation to changing conditions across the life span and is particularly important for network reorganization after brain lesions. Most studies on language reorganization focused on language recovery after stroke. Yet, a strong degree of adaptive neuroplasticity can also be observed in patients with brain tumors in language-eloquent brain areas.

This review discusses key mechanisms for neural reorganization in patients with brain tumors. Our main aim is to elucidate the underlying mechanisms for intra- and interhemispheric plasticity in the language network in these patients. The following reorganization patterns are discussed: 1) Persisting function within the tumor; 2) Reorganization in perilesional regions; 3) Reorganization in a distributed network of the affected hemisphere; 4) Reorganization to the contralesional hemisphere.

In this context, we shed light on language-related reorganization patterns in frontal and temporo-parietal areas and discuss their functional relevance. We also address tumor-related changes in structural and functional connectivity between eloquent brain regions. Thereby, we aim to expand the general understanding of the plastic potential of the neural language network and facilitate clinical decision-making processes for effective, function-preserving tumor treatment.

## 1. Introduction

Language is a key human faculty. Successful communication via language requires efficient interactions between specialized sub-networks. The relevance and complexity of human language becomes apparent when brain lesions threaten this capacity. How brain tumors can affect the language network has been little investigated to date. Nevertheless, such studies reveal unique insight into the brain's potential for neuroplasticity since patients often show no or only mild functional impairment due to functional reorganization. Tumor surgery faces the challenge to remove as much of the tumor as possible while sparing the underlying brain functions. A better understanding of the reorganization mechanisms would lead to improved operative outcomes and may increase the patients' quality of life.

Here, we provide a short overview of the language network and its

potential for plasticity. Against this background, we discuss the current literature on functional reorganization in the language network as well as tumor-related changes in structural and functional connectivity in glioma patients.

### 1.1. Overview of the language network

Language processing comprises the analysis of sound, meaning and structure of spoken words as well as the articulation of thoughts (Price, 2000). Current language models propose functional interactions of distributed temporal, frontal, and parietal brain regions within a predominantly left-lateralized neural network (see Fig. 1). This network is organized along at least two processing systems, which are underpinned by anatomically distinct fiber connections (e.g., Catani et al., 2005; Croxson et al., 2005; De Schotten et al., 2011; Friederici et al., 2006;

\* Corresponding author.

E-mail address: [nieberlein@cbs.mpg.de](mailto:nieberlein@cbs.mpg.de) (L. Nieberlein).

Saur et al., 2008). The left-lateralized dorsal stream runs along the arcuate fasciculus and superior longitudinal fasciculus (AF/SLF system) and connects the temporo-parietal cortex with the premotor cortex to convert sound representations into motor-articulatory output. The bilateral ventral stream proceeds from the temporal cortex along the medial longitudinal fasciculus (MdLF) to the anterior temporal lobe (ATL) and connects to the prefrontal cortex via the extreme capsule (MdLF/EmC system). It is associated with mapping sound representations onto meaning (Friederici, 2012; Hickok & Poeppel, 2007; Rauschecker & Scott, 2009; Saur et al., 2008; Wise, 2003). Both streams are thought to work in parallel (e.g., Hickok & Poeppel, 2007). The degree of their involvement depends on the specific task.

The domain-specific language network also interacts with domain-general networks for cognitive control and attention (Brownsett et al., 2014; Davis & Cabeza, 2015; Geranmayeh et al., 2014b). This interplay of domain-general and domain-specific networks in human language processing implies that damage can lead to multi-faceted impairments and (temporary) loss of function. At the same time, the widespread distribution of different functions harbors the potential for plastic reorganization within and across the remaining network(s), as intact network structures might partially compensate for the impairment (Saur & Hartwigsen, 2012).

### 1.2. Neuroplasticity in the language network after stroke

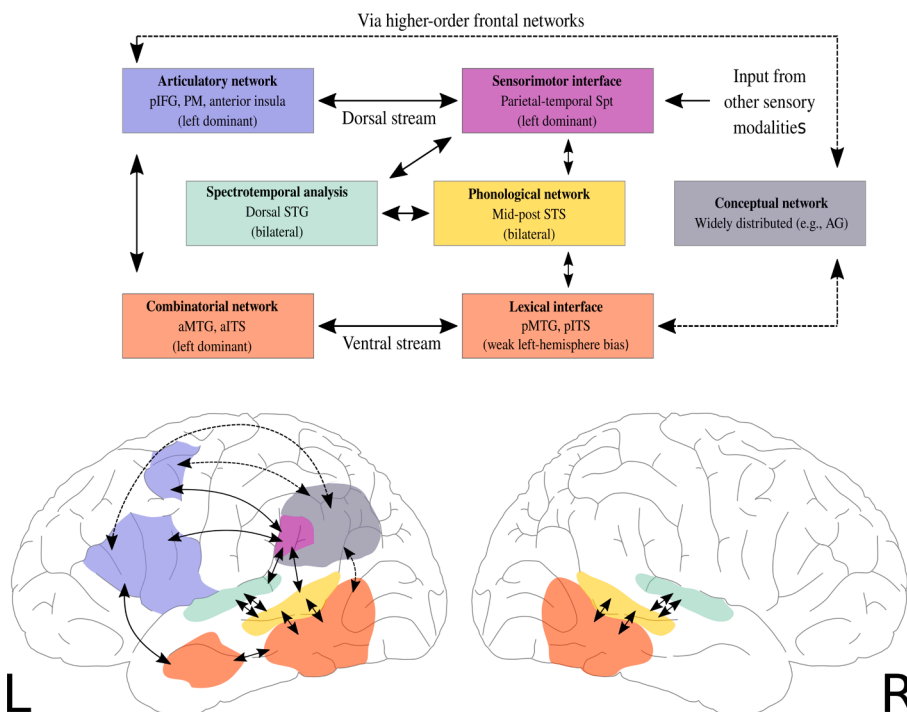
Neuroplasticity allows flexible adaptation to changing conditions over the life span. It is particularly important for reorganization processes which enable recovery of function after brain lesions. Most existing studies on reorganization in the language network so far examined patients with post-stroke aphasia (e.g., Crinion & Leff, 2007; Hamilton et al., 2011; Hartwigsen & Saur, 2019; Turkeltaub et al., 2012). These studies show that language recovery is a dynamic process that involves different reorganization mechanisms in different phases (Hartwigsen & Saur, 2019). The strongest changes are observed during the acute and early subacute phase (e.g., Hillis & Heidler, 2002). Indeed, most patients show strong spontaneous recovery within the first few weeks after stroke, which is often supported by language therapy. Language performance then stabilizes (Petersen et al., 1988), with most patients

exhibiting some aphasic symptoms even after one year (Pedersen et al., 2004). However, improvement can still be achieved in the chronic phase (e.g., Breitenstein et al., 2017; Pulvermüller et al., 2001; Szafarski et al., 2008). Several longitudinal neuroimaging studies provide insight into the dynamics of recruitment across the time course of recovery (e.g., Saur, 2006; Stockert et al., 2020). These studies report an early upregulation of frontal areas in the right hemisphere in the subacute phase. This is followed by a later normalization of activity in the chronic phase, including decreases of right-hemispheric activity and increases in perilesional left-hemispheric areas. Notably, network reorganization after stroke involves both the specialized language network as well as domain-general networks (Brownsett et al., 2014; Crinion & Leff, 2007; Geranmayeh et al., 2014a; Stockert et al., 2016).

### 1.3. Neuroplasticity in the language network in tumor patients

Relative to stroke-induced lesions of vascular origin, cerebral tumors challenge the brain's potential for adaptive plasticity in a different way. Especially low-grade tumors progress over a longer time. Therefore, they might allow for a higher amount of large-scale functional reorganization by activating latent functional parts of the larger language network (e.g., Duffau et al., 2003; Krishna et al., 2021; Traut et al., 2019). This is supported by the fact that low-grade glioma patients often show little or no functional impairment at the time of diagnosis (e.g., Gil-Robles et al., 2008; Mandonnet et al., 2003; Satoer et al., 2017). In contrast, high-grade gliomas, which grow faster, tend to cause more severe and earlier impairment (Bizzi et al., 2012; Campanella et al., 2009; Noll et al., 2015; Zhang et al., 2018).

In general, gliomas can disturb the language network in three ways: 1) Critical brain structures can be infiltrated by the tumor; 2) Subcortical fiber connections can be disrupted or 3) displaced by the tumor (Krishna et al., 2021; Witwer et al., 2002). Furthermore, while stroke-induced lesions often affect several brain structures, glioma patients have relatively circumscribed lesions (e.g., Tomasino et al., 2015; Tomasino et al., 2019). Yet, most gliomas (WHO grade II-IV) are infiltrative lesions with often unclear boundaries. Therefore, the determination of tumor extent, especially in those with infiltrative growth, can be challenging (e.g., Duffau, 2009b). Additionally, tumors go along with specific lesion-



**Fig. 1. Dual-stream model of language processing.** Green: dorsal superior temporal gyrus associated with the spectro-temporal analysis of the incoming auditory speech signal. Yellow: middle and posterior superior temporal sulcus for low-level phonological processing. Purple and pink: areas of the dorsal stream for mapping sound onto articulation. Red: areas of the ventral stream for mapping sound onto meaning. See text for details. AG = angular gyrus, a/pITS = anterior/posterior inferior temporal sulcus, a/pMTG = anterior/posterior middle temporal gyrus, pIFG = posterior inferior frontal gyrus, PM = premotor cortex, Spt = area Sylvian parietal temporal, STG = superior temporal sulcus; (For interpretation of the references to color in this figure legend, the reader is referred to the web version of this article.) Adapted from Hickok & Poeppel (2007)

related biochemical processes and alterations of physical processes occurring in perilesional areas, such as inflammation, reduced vascular reserve and micro-invasion (Vajkoczy & Menger, 2004). These factors are assumed to impact neural plasticity (Cargnelutti et al., 2020a). Depending on the tumor grade and the location in relation to eloquent brain regions, patients may show aphasic symptoms already at the beginning of the diagnosis (e.g., Banerjee et al., 2015; Wood et al., 2011) or in the later course of the disease, often with a delay of months or years after the tumor started to grow (e.g., Duffau, 2005; Duffau, 2008; Meyers et al., 2000; Pallud et al., 2013).

Functional reorganization in patients with gliomas occurs not only in the preoperative phase, triggered by tumor growth, but also after surgery (see Fig. 2). Most patients with tumors within or in vicinity to the language network experience a transient, postsurgical language impairment. These temporary impairments may not only occur due to the edema, but also because of the resection of functionally relevant regions within or adjacent to the tumor (e.g., Atlas et al., 1996; Coget et al., 2018; Wunderlich et al., 1998). Ilmberger et al. (2008) identified risk factors for postoperative language impairment, such as preoperative aphasia, intraoperative complications, functional regions within the tumor or a non-frontal tumor location. Although most patients recovered from aphasia after several months, increasing age and preoperative language impairment were predictors for a higher risk of permanent aphasia. Furthermore, several studies indicate that the preservation of subcortical fiber connections (e.g., the AF and the SLF) is essential for language function (e.g., Caverzasi et al., 2016; Tuncer et al., 2021). However, many studies show that even severe postoperative aphasic symptoms often resolve within 1–3 months (e.g., Antonsson et al., 2018; Duffau et al., 2003; Duffau et al., 2009; Krishna et al., 2021; Sanai et al., 2008; Satoer et al., 2014, 2017; Sierpowska et al., 2020). This suggests that, since reorganization processes already start preoperatively, some loss of function can be compensated by other brain regions over time. Additionally, surgery can prompt biochemical processes, such as the unmasking of redundant patterns through reduction of intracortical inhibition (Duffau, 2001; Duffau et al., 2003; Gil-Robles et al., 2008; Saito et al., 2014). Interestingly, although aphasia usually resolves within the first months post-surgery, long-term studies show that neural reorganization sometimes continues for an even longer period of time (e.g., Duffau, 2006). In addition to the influence of the tumor and surgery, therapeutic interventions like radio- (Butler et al., 2006) or

chemotherapy (Briones & Woods, 2014; Gibson et al., 2019) can cause aphasic symptoms or lead to cognitive decline. Nevertheless, their impact is rarely investigated.

#### 1.4. Aim of the review

This review covers complementary studies on tumor-induced plasticity in the language network using brain imaging techniques such as functional magnetic resonance imaging (fMRI), positron emission tomography (PET), electroencephalography (EEG)/magnetoencephalography (MEG) as well as brain stimulation approaches such as transcranial magnetic stimulation (TMS) and intraoperative direct electrical brain stimulation (DES) (see Fig. 3).

Several previous reviews discussed neural plasticity in tumor patients. These previous attempts include comparisons between pre- and intraoperative mapping techniques for motor and language functions in patients with gliomas (Cirillo et al., 2019), investigations of white matter connectivity, and the role of the contralesional hemisphere in language function (Cargnelutti et al., 2020a), as well as mechanisms of aphasia recovery in glioma patients (Krishna et al., 2021). Another review focused on the comparisons of plasticity mechanisms in the language network across different focal lesions (Pasquini et al., 2022).

Despite these previous efforts, several questions about the mechanisms and patterns of functional reorganization in the language network in patients with cerebral gliomas remain to be addressed. The existing studies strongly vary with respect to several factors, including tumor grade, location, resection volume, adjuvant treatment, age of patients, sample size, and investigation method. The strong variability hinders strong general statements about plasticity in glioma patients. The present review article has two main goals. First, by summarizing the existing literature on language reorganization in patients with brain tumors, we discuss methodological and subject specific differences between studies and draw more general conclusions that may inform future clinical decision making. Secondly, we highlight potential differences of brain reorganization for specific language functions and discuss them in the context of interactions within- and between large-scale neural networks.

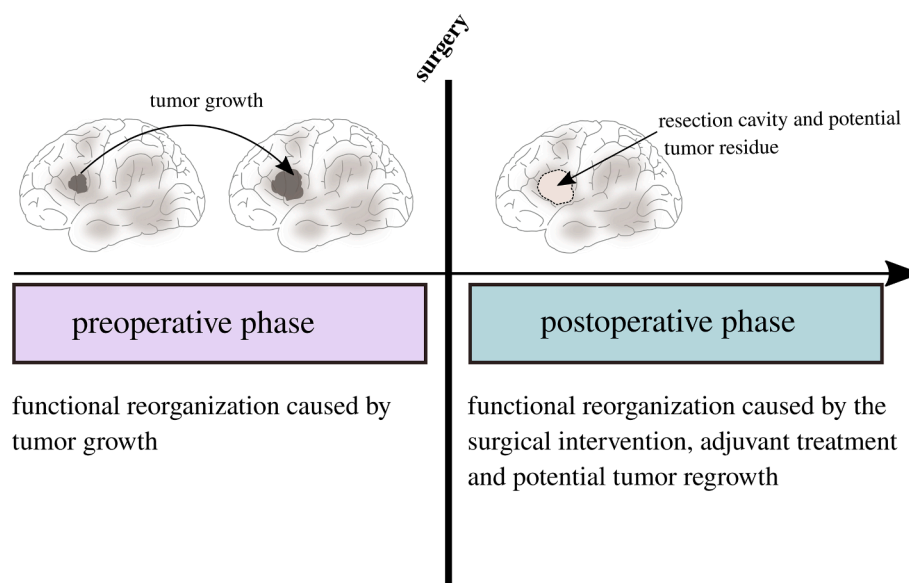
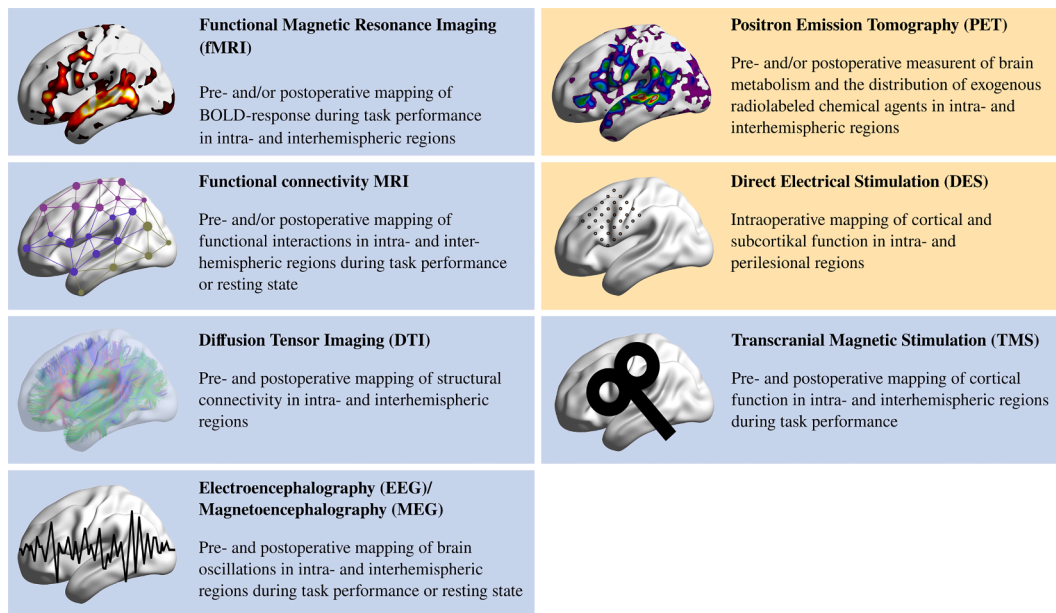


Fig. 2. Schematic visualization of differences between pre- and postoperative neural reorganization in patients with cerebral gliomas. The preoperative phase is shown on the left (violet). The postoperative phase is shown on the right (turquoise). Blurred, grey regions symbolize functional regions of the typical left-hemispheric language network.



**Fig. 3. Conceptual visualization of methods for mapping neural reorganization.** Non-invasive methods are shown in blue. Invasive methods are shown in yellow.

## 2. Methods

The search methods for the present review follow the Preferred Reporting Items for Systematic Reviews and Meta Analyses (PRISMA) guidelines (Moher et al., 2009, 2015; Page et al., 2021; see Fig. 4). For the section about cortical plasticity in the language network, studies were chosen according to the following eligibility criteria:

1. The study used pre- and/or postoperative functional neuroimaging (e.g., functional magnetic resonance imaging (fMRI), positron emission tomography (PET), electroencephalography (EEG), magnetoencephalography (MEG)) and/or pre- and/or postoperative non-invasive brain stimulation (e.g., TMS) and/or intraoperative direct electrical stimulation (DES) to map language function and investigate neural plasticity with either a between or within-subject design (see Fig. 3 for an overview of mapping methods). Results were interpreted as plasticity if 1) a given functional activation was dislocated with respect to its normal anatomical location, 2) functional reorganization was detected in the absence of language deficits, 3) pre- and postoperative functional maps differed (sometimes with repeated surgeries) (see Cargnelutti et al., 2020a).
2. Subjects had a diagnosis of a primary cerebral tumor (glioma) affecting the left, language-dominant hemisphere. Patients with tumors of all sizes, histopathologies and WHO-grades were included.
3. The study used at least one productive or comprehensive language paradigm to map language function.

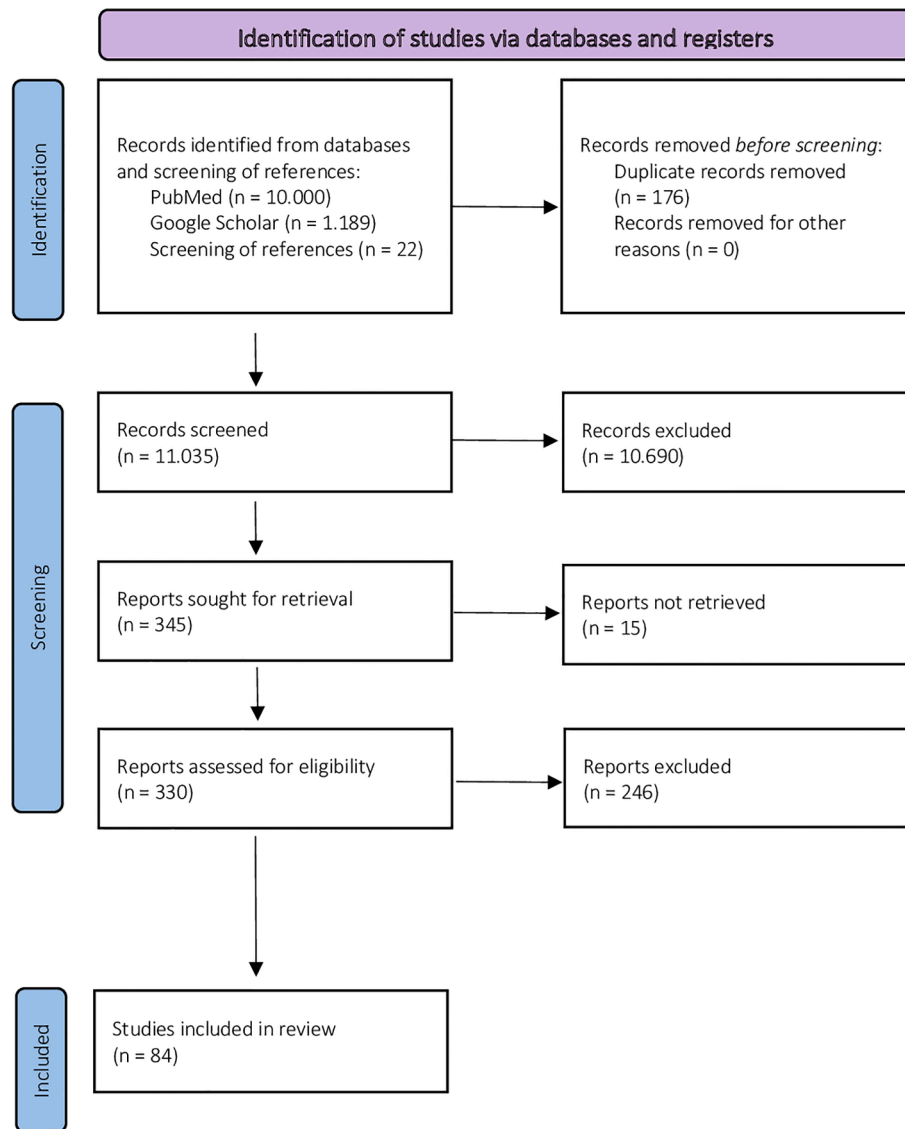
For the section on structural connectivity in glioma patients, we additionally included studies using only anatomical magnetic resonance imaging (MRI) and diffusion tensor imaging (DTI) (Jehna et al., 2017; Kinoshita et al., 2014; Zheng et al., 2013). None of these studies included a language paradigm. To review the literature on functional connectivity in glioma patients, we included both task-based and resting state paradigms.

All publications (regardless of publication date) were included if they met the eligibility criteria. Studies were collected from the literature databases PubMed (<https://www.pubmed.de>) and Google Scholar (<https://scholar.google.com>). Searches included the key words “tumor” AND “language” AND “plasticity” OR “reorganization”. Additionally, previous reviews (Cargnelutti et al., 2020a; Cirillo et al., 2019; Krishna

et al., 2021; Pasquini et al., 2022) and references from included studies were screened for further articles. The search in PubMed yielded a total of 35,178 results. Google Scholar found 87,100 articles, based on our search terms. However, only the first 10,000 results on PubMed and the first 1,189 results on Google Scholar could be displayed. Search results of both databases included 176 duplicates, which were removed. The remaining 11,113 studies plus 22 studies that were found in the references of previous reviews, were screened for matching the inclusion criteria. Screening resulted in the exclusion of 10,690 studies. The remaining 345 studies were sought for retrieval. 15 studies had to be excluded because they could not be retrieved or because their content was far from our research question. In a next step, the remaining 330 studies were assessed for eligibility by two independent researchers. 246 articles were excluded, since they a) did not report outcomes in glioma patients, b) examined children only, c) did not address the language network, d) did not use any of the above-mentioned methods, e) were pure mapping studies that did not investigate neural plasticity mechanisms, or f) were review or opinion papers which did not describe own data. Finally, 84 studies were included in the current review. We also included three eligible preprints that were found on Google Scholar to avoid publication bias. Of all included studies, 57 studies dealt with cortical plasticity in patients with cerebral tumors. Since the literature (e.g., Desmurget et al., 2007) suggests four main patterns of tumor-induced cortical plasticity (1) Persistence of function within the tumor, 2) Reorganization in perilesional regions, 3) Reorganization in a distributed network of the affected hemisphere; 4) Reorganization in the contralesional hemisphere; see paragraph 3 for details), those studies were assigned to one or more of these patterns, depending on the evidence provided by each study. Details for all studies that comprise evidence for cortical plasticity are provided in Table 1. The remaining 27 studies dealt with subcortical plasticity and changes in structural ( $n = 15$ ) and functional ( $n = 12$ ) connectivity due to brain tumors. Details for these studies are provided in Table 2. Cut-off date for the publication of studies was June 2022.

## 3. Patterns of cortical plasticity in the lesioned language network

In the following paragraphs, general mechanisms of tumor-induced cortical plasticity and adaptation in the language network will be



**Fig. 4.** PRISMA flowchart displaying the process of literature search and screening (see Moher et al., 2009, 2015; Page et al., 2021). Cut-off date for the publication of studies was June 2022.

discussed. Based on the current state of research, four main hierarchical patterns of adaptation to gliomas can be identified (see Fig. 5): 1) Persistence of function within the tumor, 2) Reorganization in perilesional regions, 3) Reorganization in a distributed network of the affected hemisphere, 4) Reorganization in the contralesional hemisphere (e.g., Desmurget et al., 2007; Duffau et al., 2003; Duffau, 2005; Duffau, 2008). The included studies were grouped according to these patterns. Note that this classification is an oversimplification and does not always occur in a sequential order. Accordingly, some studies provide evidence for more than one pattern, sometimes even within the same individuals, and are therefore mentioned several times. Relevant study details are summarized in Table 1. Note that we mainly focus on studies with larger sample sizes ( $n > 10$ ) in the text.

### 3.1. Persisting function within the tumor

Since tumors often progress by slowly infiltrating the brain, the affected regions usually do not lose function at once. Instead, threatened language function can persist within the tumor for some time. Especially in the periphery of the tumor (infiltration zone), residual function might be explained by the co-occurrence of tumor cells and healthy cells. When

damage becomes too critical, other brain regions usually take over compensatory function (e.g., Duffau et al., 2002; Ille et al., 2019; Southwell et al., 2016). Even though persisting function within the tumor is not exactly a mechanism of plasticity, transition to functional reshaping mostly occurs in a fluid manner and cannot be neglected when aiming to understand the principles of functional reorganization in tumor patients. Furthermore, functional regions within the tumor have an important impact on the surgical success. Usually, persisting function results in an incomplete resection (Ojemann et al., 1996) since a more radical procedure might cause severe permanent speech and language disorders and would significantly reduce the patient's quality of life. Intralesional function is also a risk factor for postoperative aphasia (Ilmberger et al., 2008). Across the last years, fractionated surgeries, especially for low grade gliomas, have become increasingly popular (e.g., Duffau et al., 2002; Gil-Robles et al., 2008; Picart et al., 2019; Saito et al., 2014), since time between resections often allows for functional reorganization and intralesional regions that were critical during the first resection already gave up function a few months later before the second surgery (e.g., Gil-Robles et al., 2008; Saito et al., 2014; Sarubbo et al., 2012a; Sarubbo et al., 2012b). Such reorganization may probably even be promoted by the first surgery (Duffau, 2005; Duffau et al.,

**Table 1**  
Studies that report cortical plasticity in patients with cerebral gliomas.

Study	N	Plasticity mechanism	Tumor location	Tumor grade	Methods	Surgery	Task
<a href="#">Southwell et al. (2016)</a> , Journal of Neurosurgery	561 patients	Persisting function, perilesional and intrahemispheric reorganization	Frontal, parietal, temporal or insula	All kinds of gliomas	Intraoperative DES	Repeated surgeries in 18 cases	Object naming, reading, counting, calculation
<a href="#">Deng et al. (2015)</a> , Journal of Neurosurgery	101 patients	Contralesional reorganization	Left frontal, temporal, or parietal lobe	38 glioma patients, 63 patients with arteriovenous malformations	Preoperative fMRI	Single surgery	Silent reading
<a href="#">Wang et al. (2020)</a> , Preprint	90 patients	Contralesional reorganization	Left perisylvian regions	All kinds of gliomas	Preoperative rTMS	Single surgery	Picture naming
<a href="#">Duffau et al. (2003)</a> , Journal of Neurology, Neurosurgery & Psychiatry	77 patients	Persisting function, Perilesional Reorganization	primary and/or secondary sensorimotor and/or language areas	Low grade gliomas (WHO grade II)	Pre- and postoperative MRI, intraoperative DES	Single surgery	Not described
<a href="#">Traut et al. (2019)</a> , Human Brain Mapping	73 patients	Contralesional reorganization	Various locations	All kinds of gliomas	Preoperative MEG	Repeated surgeries	Verb generation
<a href="#">Nadkarni et al. (2015)</a> , Preprint	67 tumor patients, 27 stroke patients	Contralesional reorganization	Left hemispheric regions	All kinds of gliomas	Preoperative fMRI	Single surgery	Antonym-word generation, letter-word generation, text-reading, text-listening
<a href="#">Thiel et al. (2001)</a> , Annals of Neurology	61 patients, 12 healthy subjects	Perilesional, intrahemispheric and contralesional reorganization	Various locations	Low-grade gliomas, 8 patients with lesions other than gliomas	Preoperative PET	Single surgery	Verb generation
<a href="#">Poczyńska et al. (2021)</a> , Journal of Neurosurgery	60 patients (left: n = 30, right: n = 30)	Negative finding of contralesional reorganization	Left and right hemispheric, anterior, and posterior lesions	All kinds of gliomas	Preoperative fMRI	Single surgery	Object naming, verb generation, silent reading, silent auditory naming
<a href="#">Partovi et al. (2012)</a> , American Journal of Neuroradiology	57 patients, 14 healthy subjects	Contralesional reorganization	Left Broca's or Wernicke's area	All kinds of gliomas	Preoperative fMRI	Single surgery	Sentence and word generation
<a href="#">Gohel et al. (2019)</a> , American Journal of Neuroradiology	51 patients	Contralesional reorganization	Various locations (left: n = 28; right: n = 23)	All kinds of gliomas	Preoperative fMRI	Single surgery	Resting state
<a href="#">Rösler et al. (2014)</a> , Clinical Neurophysiology	50 patients, 15 healthy subjects	Contralesional reorganization	Left hemispheric regions	All kinds of gliomas	Preoperative rTMS	Single surgery	Picture naming
<a href="#">Wang et al. (2013)</a> , PLOS ONE	43 patients	Contralesional reorganization	Left frontal cortex, left temporal cortex, right hemisphere	All kinds of gliomas	Preoperative fMRI	Single surgery	Picture naming
<a href="#">Duffau et al. (2006)</a> , Clinical Neurology and Neurosurgery	42 patients	Persisting function, Perilesional Reorganization	Left Insula	Low-grade gliomas	Intraoperative DES	Single surgery	Not described
<a href="#">Picart et al. (2019)</a> , Neurosurgery	42 patients (high level of plasticity: n = 23; low level of plasticity: 19)	Persisting function	Supratentorial regions	Gliomas (WHO grade II-III)	Intraoperative DES	Repeated surgeries	Not described
<a href="#">Skirboll et al. (1996)</a> , Neurosurgery	38 patients	Persisting function	Various locations	All kinds of gliomas	Intraoperative DES	Single surgery	Counting, object naming, reading
<a href="#">Latini et al. (2021)</a> , Journal of Clinical Medicine	36 patients	Persisting function, Perilesional Reorganization	different locations in both hemispheres (left: n = 34, right: n = 2)	Low-grade gliomas	Preoperative MRI and DTI, intraoperative DES	Single surgery	Confrontation naming, language comprehension, phonological and semantic word fluency, reading, writing and phonological ability
<a href="#">Gunal et al. (2018)</a> , Surgical Neurology International	23 patients	Perilesional, intrahemispheric and contralesional reorganization	Left inferior frontal gyrus	All kinds of gliomas	Preoperative fMRI	Single surgery	Picture naming
<a href="#">Buklina et al. (2013)</a> , Journal of Neurosurgery	21 patients	Contralesional reorganization	Different locations (Mainly frontal, frontotemporal, and temporal)	All kinds of gliomas	Preoperative fMRI	Single surgery	Reversal naming of months
<a href="#">Buklina et al. (2017)</a> , Burdenko's Journal of Neurosurgery	20 patients	Contralesional reorganization	Left frontal and temporal regions	All kinds of gliomas	Pre- and postoperative fMRI	Single surgery (n = 15), repeated surgery (n = 5)	Reversal naming of months, phonemic fluency, verb generation, formation of sentences, story listening

(continued on next page)

Table 1 (continued)

Study	N	Plasticity mechanism	Tumor location	Tumor grade	Methods	Surgery	Task
Ille et al. (2019), Frontiers in Oncology	18 patients	Persisting function, perilesional and contralesional reorganization	Left hemispheric perisylvian regions	All kinds of gliomas	Pre- and postoperative rTMS	Repeated surgeries in 15 cases	Object naming
Zimmermann et al. (2020), World Neurosurgery	18 patients, 3 healthy subjects	Intrahemispheric and contralesional reorganization	Left hemispheric regions	All kinds of gliomas	Pre- and postoperative fMRI and MEG	Single surgery	Verb conjugation, building sentences
Avramescu-Murphy et al. (2016), Clinical Neuroradiology	17 patients	Mainly intrahemispheric reorganization	Frontotemporal and lower parietal lobes in both hemispheres	All kinds of gliomas, 1 metastasis	Pre- and postoperative fMRI, intraoperative DES	Single surgery	Semantic matching, color matching
Thiel et al. (2006), Brain and Language	17 patients, 8 healthy subjects	Contralesional reorganization	Left hemispheric regions	All kinds of gliomas	Pre- or postoperative PET and rTMS	Single surgery	Verb generation
Lubrano et al. (2010), Neurosurgery	16 patients	Persisting function, Perilesional Reorganization	Left inferior frontal cortex	Diffuse gliomas (n = 10) and cavernomas or well circumscribed lesions (n = 6)	Intraoperative DES	Single surgery	Object naming
Thiel et al. (1998), NeuroImage	16 patients (right- handed: n = 10; left- handed: n = 6)	Intrahemispheric reorganization	Various locations	All kinds of gliomas	Preoperative PET	Single surgery	Word repetition, verb generation
Krieg et al. (2013), PLOS ONE	15 patients, 50 healthy subjects	Contralesional reorganization	Left hemispheric language regions	All kinds of gliomas	Preoperative rTMS	Single surgery	Object naming
Ojemann et al. (1996), Neurosurgery	14 patients, 9 of them with language eloquent lesions	Persisting function	Frontal lobe, temporal lobe, motor cortex, somatosensory cortex	All kinds of gliomas	Intraoperative DES	Single surgery	Object naming
Piai et al. (2019), Preprint	14 patients	Contralesional reorganization	Left hemispheric regions	All kinds of gliomas	Preoperative MEG	Single surgery	Picture word interference task
Thiel et al. (2005), Annals of Neurology	14 patients, 5 healthy subjects	Contralesional reorganization	Various locations	All kinds of gliomas	Preoperative PET and rTMS	Single surgery	Verb generation
Grummich et al. (2005), Neuroscience Letters	12 patients	Contralesional reorganization	Adjacent to Broca's or Wernicke's region	All kinds of gliomas	Preoperative MEG	Single surgery	Silent picture naming, silent reading, counting
Kośła et al. (2012), Polish Journal of Radiology	11 patients	Contralesional reorganization	Left Broca's or Wernicke's area	All kinds of gliomas	Preoperative fMRI	Single surgery	Word generation
Gębska-Kośła et al. (2017), Neurologia i Neurochirurgia Polska	10 patients	Contralesional reorganization	near or in left Broca's (n = 5) or Wernicke's (N = 5) region	All kinds of gliomas	Pre- and postoperative fMRI	Single surgery	Word generation (names), rest as control condition
Van Geemen et al. (2014), Human Brain Mapping	8 patients	Persisting function	Left ventral premotor cortex	Low-grade gliomas	Intraoperative DES	Single surgery	Counting, picture naming
Benzagmout et al. (2007), Neurosurgery	7 patients	Persisting function, Perilesional Reorganization	Left Broca's area	Low-grade gliomas	Preoperative fMRI, intraoperative DES	Single surgery	Repetition, story listening, fluency, counting, picture naming
Meyer et al. (2003), European Journal of Nuclear Medicine and Molecular Imaging	7 patients	Perilesional, intrahemispheric and contralesional reorganization	Left frontal (n = 6) or temporal (n = 1) regions	All kinds of gliomas	Preoperative PET	Single surgery	Verb generation, rest as control condition
Sarubbo et al. (2012b), Acta Neurochirurgica	4 patients	Persisting function, Perilesional Reorganization	Left temporal regions	1 low-grade glioma, 3 high- grade gliomas	Intraoperative DES	Repeated surgeries	Not described
Satoe et al. (2017), Case Reports in Neurological Medicine	4 patients	Perilesional reorganization	left hemispheric regions (Broca's area, Wernicke's area, arcuate fasciculus)	Low-grade gliomas (n = 2) and high- grade gliomas (N = 2)	Preoperative fMRI, intraoperative DES	Single surgery	Object naming, repetition, spontaneous speech
Wu et al. (2008), Chinese Medical Journal	4 patients, 4 healthy subjects	Persisting Function, perilesional and contralesional reorganization	Broca's area	Low-grade gliomas	Preoperative fMRI and DTI, intraoperative DES	Repeated surgeries	Auditory word judgement, auditory word repetition, picture naming, counting
	3 patients			Low-grade gliomas	Intraoperative DES		

(continued on next page)

Table 1 (continued)

Study	N	Plasticity mechanism	Tumor location	Tumor grade	Methods	Surgery	Task
Duffau et al. (2002), Journal of Neurology, Neurosurgery & Psychiatry		Persisting function, Perilesional Reorganization	Left temporal, left precentral, right postcentral			Single surgery	Counting, picture naming
Lazar et al. (2000), Neuropsychologia	3 patients	Contralesional reorganization	Left frontal lobe	Arteriovenous malformations	Preoperative fMRI	Single surgery	Verbal fluency, comprehension, naming, reading, repetition
Gil-Robles et al. (2008), Journal of Neurosurgery	2 patients	Persisting function, perilesional, intrahemispheric and contralesional reorganization	Left premotor area	Low-grade gliomas	Pre- and postoperative fMRI, intraoperative DES	Repeated surgeries	Semantic fluency
Pillai (2010), American Journal of Neuroradiology	2 patients	Contralesional reorganization	Case1: left parietal; Case2: left frontotemporal	All kinds of gliomas	Pre- and postoperative (Case1: after 5.5 and 15.5 months; Case2: after 5.5 and 31 months) fMRI	Single surgery	Case1: Semantic association task; Case2: Phonological task
Spena et al. (2015), Neurocase	1 patient	Perilesional reorganization	Left posterior frontal lobe	Anaplastic glioma	Intraoperative DES, pre- and postoperative fMRI	Single surgery	Verb generation, counting
Acioly et al. (2014), Journal of neurological surgery	1 patient	Contralesional reorganization	Left frontal lobe	Low-grade glioma (WHO grade II)	Preoperative fMRI, intraoperative DES	Single surgery	Verbal fluency, Picture naming
Barcia et al. (2012), NeuroReport	1 patient	Persisting function, Intrahemispheric and contralesional reorganization	Left Broca's area	Glioma (WHO grade III)	chFCS, preoperative fMRI	Repeated surgeries	Phonemic fluency, Verb generation
De Witte et al. (2014), Clinical Neurology and Neurosurgery	1 patient	Contralesional reorganization	Lower posterior frontal lobe at the cavity of a former resection	High-grade glioma (WHO grade III-IV) → tumor recurrence from a former low-grade glioma	Intraoperative DES, postoperative fMRI and DTI	Repeated surgeries	DES: counting, automatic sequences, word repetition, picture naming, word reading, verb generation, action naming; fMRI: noun-verb-association task vs rest
Duffau et al. (2001a), Neurophysiology, Basic and Clinical	1 patient	Perilesional, intrahemispheric and contralesional reorganization	Left Insula	Glioma	Preoperative fMRI, intraoperative DES	Single surgery	fMRI: semantic fluency, covert sentence repetition, story listening; DES: counting, picture naming
Duffau et al. (2001b), Stereotactic and Functional Neurosurgery	1 patient	Persisting function, Intrahemispheric reorganization	Supramarginal gyrus	Low-grade glioma	Intraoperative DES	Single surgery	Counting, naming
Holodny et al. (2002), Journal of computer assisted tomography	1 patient	Contralesional reorganization	Left inferior frontal gyrus	Glioma (WHO grade II/IV)	Preoperative fMRI	Single surgery	Silent word generation, single word semantic decision
Kawashima et al. (2013), Clinical Neurology and Neurosurgery	1 patient	Contralesional reorganization	Left frontal operculum	High-grade glioma	Pre- and postoperative rTMS	Repeated surgeries	Object naming
Kośla et al. (2015), Polish Journal of Radiology	1 patient	Contralesional reorganization	Left frontal lobe with topographical relationship to Broca's area	Low-grade glioma	Pre- and postoperative fMRI (after 3, 32 and 41 months)	Single surgery	Word generation
Li et al. (2019), Frontiers in Neurology	1 patient	Contralesional reorganization	Left fronto-temporal insula	Low-grade glioma	Pre- and postoperative fMRI, intraoperative DES	Repeated surgeries	Verbal fluency, semantic fluency
Petrovich et al. (2004), American Journal of Neuroradiology	1 patient	Contralesional reorganization	Temporo-parietal region	Glioma	Preoperative fMRI, intraoperative DES	Single surgery	Homonym judgment, synonym generation, picture naming
Plaza et al. (2009), Neurocase	1 patient	Perilesional reorganization	Left inferior frontal gyrus	Low-grade glioma	Intraoperative DES	Single surgery	Counting, picture naming
Rosenberg et al. (2008), Neurocase	1 patient	Contralesional reorganization	Left fronto-temporal area	Low-grade glioma	Preoperative fMRI	Single surgery	Verb generation
Saito et al. (2014), Neurologia medico-chirurgica	1 patient	Persisting function, perilesional and intrahemispheric reorganization	Left inferior frontal gyrus	Low-grade glioma (WHO grade II)	Intraoperative DES, intraoperative MRI	Repeated surgeries	Object naming, reading

(continued on next page)

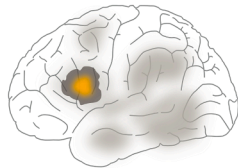


Table 1 (continued)

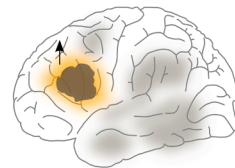
Study	N	Plasticity mechanism	Tumor location	Tumor grade	Methods	Surgery	Task
Sarubbo et al. (2012a), Neurosurgical Review	1 patient	Persisting function, perilesional, intrahemispheric and contralesional reorganization	Left Wernicke's area	Low-grade glioma (WHO grade II)	Pre- and postoperative fMRI, intraoperative DES	Repeated surgeries	Picture naming, silent reading, semantic matching

**Abbreviations:** cHFCS: continuous High-Frequency Cortical Electrical Stimulation; DES: Direct electrical Stimulation; DTI: Diffusion Tensor Imaging; (f)MRI: (functional) Magnetic Resonance Imaging; MEG: Magnetoencephalography; PET: Positron Emission Tomography; rTMS: repetitive Transcranial Magnetic Stimulation; WHO: World Health Organization.

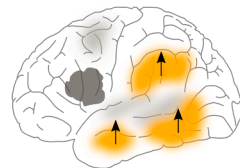
### 1. Persisting function within the lesion



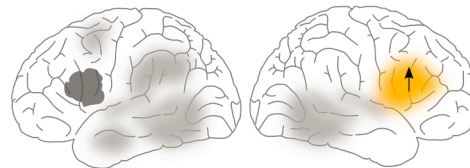
### 2. Perilesional Reorganization



### 3. Intrahemispheric, distributed Reorganization



### 4. Contralesional Reorganization



**Fig. 5. Schematic illustration of plasticity mechanisms in the language network.** The tumor (shown in dark grey) is located in the left IFG here. Light grey areas symbolize functional regions of the “normal” language network. Patterns of functional reorganization are shown in yellow with black arrows indicating the upregulation of activity in these regions.

2002).

Intralesional function has been reported regardless of tumor location, degree of infiltration, swelling, necrosis and mass-related shift (Skirboll et al., 1996). Furthermore, tumors of all grades can show persisting language activity within the lesion. However, some factors that influence the risk for persisting function within the tumor can be traced.

Since DES is one of the methods that most reliably detects intralesional language function, many studies report respective findings that were found intraoperatively. For example, some DES-studies showed that larger tumors (Latini et al., 2021; Southwell et al., 2016) often go along with more functional spots within the lesion. Consequently, slower tumor growth might favor reorganization while faster growing lesions are more prone to persisting function. This is supported by a study on repeated surgery, since large preoperative lesions correlated with more persisting intralesional function even during a later, repeated surgery (Southwell et al., 2016).

Using intraoperative DES, Picart et al. (2019) observed that a high degree of plasticity was related to rather sharply defined tumors, while patients with more diffuse gliomas showed less functional reorganization and more persisting function within the lesion. Additionally, diffuse tumors more often affected subcortical white matter, which also limited neuroplasticity. Consequently, surgery of sharply defined tumors caused less harm to functional regions and patients recovered faster than those with more diffuse lesions.

A study using preoperative MRI and DTI as well as intraoperative DES in diffuse low-grade glioma patients found that age had a strong influence on brain plasticity, since higher age was directly correlated with intralesional eloquent spots during awake surgery (Latini et al., 2021). This finding is in line with other studies reporting a lower degree of myelin/white matter plasticity in elderly people (Fuchs & Flügge,

2014; Wang & Young, 2014). Moreover, Latini et al. (2021) found that persisting function within the tumor on the subcortical level was correlated with an increased risk for neuropsychological impairment and epilepsy. Furthermore, the number of intralesional cortical eloquent spots was negatively correlated with the number of perilesional cortical eloquent spots. This is in line with other research arguing that intralesional persisting function and perilesional function reflect different stages of an adaptive process during glioma growth, which rarely occur in parallel (Duffau, 2020; Kong et al., 2016; Southwell et al., 2016).

Notably, brain regions differ in their potential for plastic reorganization and their likelihood to show persisting function. One of the brain regions most studied in terms of language processing is Broca's area in the left inferior frontal gyrus (IFG). Contrary to what has long been assumed, this region seems to have a relatively high potential for neuronal reorganization, so that even large tumors in this region could be surgically removed without causing permanent functional deficits (e.g., Plaza et al., 2009). Persisting function is therefore rare in the IFG, especially in the case of low-grade gliomas with slow growth as shown with DES (e.g., Duffau et al., 2003) and fMRI (e.g., Benzagmout et al., 2007).

The neighboring left ventral premotor cortex (PMv), on the other hand, seems to have a rather low plastic potential, probably due to its dependence on the underlying SLF (e.g., Ius et al., 2011; Martino et al., 2009; van Geemen et al., 2014).

The plastic capacities of the insula also seem to be limited, at least if the tumor has also infiltrated adjacent regions in the frontal and temporal operculum (Duffau et al., 2003, 2006; but see next section). This was shown by a relatively large DES study. In eight of 42 patients, in addition to the insula, the frontal operculae were also infiltrated by the tumor. These cases all showed persisting language function within the insula, presumably because the operculae were unable to fully

compensate for the function (Duffau et al., 2006).

Some DES studies with small sample sizes also found persisting language function in patients with gliomas in the left temporal lobe (Duffau et al., 2002, 2003; Sarubbo et al., 2012a, 2012b). Yet, in those patients who underwent repeated surgeries, complete resection was usually possible in the second operation, since language functions had been successfully reorganized outside the lesion (Duffau et al., 2002, 2003; Sarubbo et al. 2012a).

In summary, functional regions within the lesion often complicate tumor resection and sometimes make repeated surgeries necessary. Factors like older age, large tumor volume and higher tumor grades increase the risk of persisting function within tumors. Furthermore, the degree of plasticity and reorganization seems to differ substantially between language areas and is strongly dependent on subcortical connections.

### 3.2. Perilesional reorganization

Functional reorganization in perilesional regions is frequently observed in patients with cerebral tumors. Such reorganization can occur both preoperatively (e.g., Gunal et al., 2018; Thiel et al., 2001) in brain regions adjacent to the tumor and postoperatively (e.g., Duffau et al., 2003; Ille et al., 2019; Lizarazu et al., 2020) at the edges of the resection cavity or around a tumor residue. As shown by Latini et al. (2021), patients with eloquent spots in perilesional regions usually show relatively good behavioral language and neuropsychological abilities, compared to patients with persisting function within the lesion. The authors therefore assume that peritumoral cortices within the same functional hub are often recruited as a first mechanism of functional reorganization.

One of the first studies that detected preoperative perilesional reorganization outside the classic language regions was conducted by Thiel et al. (2001). Here, 61 patients with left-hemispheric brain tumors and 12 healthy control subjects were examined with PET during a verb generation task. Most patients were affected by low-grade gliomas and showed no or little language deficits. In contrast to the healthy control group, patients frequently showed frontolateral language activation not only in “classic” Broca’s region (BA 44/45), but also in adjacent IFG areas (BA 46 and BA 47). Likewise, perilesional reorganization and unimpaired language abilities in patients with gliomas affecting the IFG were found in DES studies (e.g., Duffau et al., 2003; Lubrano et al., 2010). For example, Lubrano et al. (2010) reported that only 5 of 20 glioma patients showed language-positive regions within classic Broca’s area (BA 44/45). Instead, most of the language-positive spots were located in perilesional regions, particularly in the pars orbitalis and the premotor cortex. More insight into the plasticity patterns in patients with tumors affecting the IFG is provided by an fMRI study (Gunal et al., 2018). Here, patients were divided into two groups, depending on the presence of clinical language impairment. None of the patients exhibited significant BOLD-activity in Broca’s area. In patients with unimpaired language functions, however, activations were found in adjacent regions (BA 13 and 47) as well as in the contralesional frontal cortex (BA 9). Patients with language impairment showed neither activity in adjacent brain regions nor in the right Broca’s homologue. The authors concluded that lower-grade tumors, which were predominantly found in patients with unimpaired language, allowed more extensive neuronal plasticity due to their slower and less aggressive growth. In contrast, the faster growth of higher-grade tumors could have restricted reorganization processes.

A brain region that is frequently affected by brain tumors is the insula (Duffau & Capelle, 2004). Using intraoperative DES, Duffau et al. (2006) demonstrated that functional language impairment resulting from circumscribed tumors affecting the insula is often compensated by perilesional reorganization patterns, especially in the frontal and temporal operculum.

Several studies also provide evidence for postoperative perilesional

reorganization in the language network. Southwell et al. (2016) used DES in 18 glioma patients who underwent repeated surgeries. Particularly tumors with smaller volumes appeared to be associated with functional changes over time. In most cases, this was characterized by a loss of function in intra- and perilesional areas. Since these patients showed intact or stable language functions, it can be assumed that functional reorganization happened in brain regions remote from the lesion. These results are also in line with Ille et al. (2019) who conducted rTMS language mapping in 18 glioma patients who underwent surgery twice. Patients who showed strong language function near the tumor during the first session presented with significantly more language negative sites in the tumor area during the second measurement, compared to patients in whom language function was not even preoperatively located near the tumor. Consequently, these results argue for perilesional reorganization to be a rather early compensatory mechanism, which is often followed by compensation through more remote brain regions. Furthermore, most changes in cortical language function were observed in patients with a follow-up time of more than 13 months and tumors with lower WHO grades.

In summary, perilesional reorganization can be found pre- and postoperatively for tumors with varying cortical locations as well as different tumor grades. However, despite partly divergent findings and small sample sizes, compensatory function in perilesional areas seems to be a rather early mechanism that replaces functional spots within the lesion in an effective way, since patients in this stage tend to have no or only slight language impairment.

### 3.3. Reorganization in a distributed left-hemispheric network

Besides perilesional reorganization, more distributed regions of the affected hemisphere can be recruited to compensate for the lesion. However, preoperative evidence is only provided by a few studies with small sample sizes. Using PET, Meyer et al. (2003) report increased language activation in the superior temporal gyrus in patients with tumors located in Broca’s area. Additionally, they found an opposite pattern in a case with a tumor infiltrating left temporo-parietal regions, with increased activity in left Broca’s area. More evidence for preoperative reorganization in distributed, intrahemispheric regions comes from a DES/fMRI-study that investigated tumors affecting the insula (Duffau et al., 2001a). In that study, compensatory activation was found in Broca’s area, the left superior temporal gyrus, and the left putamen. In addition, some preoperative PET studies report activity in “atypical” language regions, such as in BA 46, BA 47 and the SMA (see Desmurget et al., 2007; Meyer et al., 2003; Thiel et al., 1998).

Several indications of language reorganization in distributed intrahemispheric regions were also found postoperatively or between repeated tumor resections. Avramescu-Murphy et al. (2016) found evidence for postoperative language reorganization in the dominant and non-dominant hemisphere. 17 patients with different gliomas in the frontotemporal and lower (bilateral) parietal lobes were investigated with pre- and postoperative fMRI as well as intraoperative DES. Postoperative fMRI showed increased activation and a shift of functional spots in all but one patient. The strongest changes were found within the language dominant hemisphere, independent of tumor location. Remarkably, while tumor resections in the dominant hemisphere led to a shift from frontal to temporal activations, resections in the non-dominant hemisphere induced a shift from temporal to frontal regions. The observed increase in postoperative activation within the dominant hemisphere was interpreted as recovery from tumor-induced suppression of functional regions. Likewise, an fMRI study by Gil-Robles et al. (2008) in two patients with low grade gliomas in the left premotor area found increased language activation in the left IFG, the left frontal operculum and in bilateral parietal regions in the postoperative measurement. A single case study in a patient with a low-grade glioma in the left IFG revealed new language activation in the ventral precentral gyrus in the postoperative fMRI session (Saito et al., 2014). Another case

report on a patient with a low-grade glioma in left Wernicke's area showed several ipsilateral regions in the postoperative session which contributed to the compensation of language functions, including the left IFG and the AF (Sarubbo et al., 2012a).

In summary, language reorganization in distributed intrahemispheric regions occurs both pre- and postoperatively in patients with frontal as well as temporal tumors. In particular, the size and aggressiveness of a tumor seems to determine whether and, if so, which plasticity mechanisms take place. For example, intraoperative DES suggests that reorganization in more distant brain regions can occur preoperatively, especially with large tumors, while smaller tumors allow reorganization in perilesional regions (Southwell et al., 2016).

### 3.4. Right-hemispheric reorganization

The strongest evidence is available for contralesional reorganization, since tumor growth often promotes laterality changes, which are more or less independent of preclinical language dominance (e.g., Traut et al., 2019). Preoperative translocation to homologous right-hemispheric regions can often be observed even though the left hemisphere is still active (e.g., Holodny et al., 2002; Li et al., 2019; Petrovich et al., 2004; Thiel et al., 2006).

Much of the current evidence comes from fMRI studies. For example, one study in 23 patients with tumors in the left IFG reported language activity in regions adjacent to the tumor and/or in the right Broca homologue for all non-aphasic patients (Gunal et al., 2018). These results suggest that contralesional reorganization is beneficial for the maintenance of function.

Another study differentiated between patients with tumors in Broca's and Wernicke's area (Kořla et al., 2012). Most patients with low-grade gliomas in the left frontal lobe showed activation in the right Broca homologue. Moreover, activation in left Wernicke's area and its right homologue was found regardless of tumor size or histopathology. Further evidence for a functional shift of language activation in the contralateral hemisphere comes from a preoperative fMRI study by Partovi et al. (2012), in which 57 patients with left-hemispheric brain tumors affecting either Broca's or Wernicke's area were examined. Compared to healthy controls, patients with frontal lesions showed a reduced laterality index (LI) during word generation, while no significant difference was found for sentence generation. The opposite picture emerged for patients with temporal lesions. Here, the LI was reduced in the sentence generation task, but not in the word generation task. Thus, the results not only support the notion of contralesional reorganization in patients with frontal as well as temporal tumors, but also indicate functional specialization in these compensatory regions, depending on the specific language task or function.

The impact of tumor location on right-hemispheric reorganization was investigated by Wang et al. (2013). Here, 43 patients with cerebral tumors underwent preoperative fMRI. Patients were divided into three groups based on tumor location (left frontal, left temporal and right hemispheric). Significant functional changes in language processing were found for left-sided tumors only. Interestingly, left frontal tumors affected both left Broca's and Wernicke's area while temporal tumors mainly influenced Wernicke's area. Furthermore, compensatory activation increases were measured in the right frontal cortex. Contralesional reorganization is further supported by an fMRI-study with broader inclusion criteria (Buklina et al., 2013).

Nevertheless, findings concerning contralesional language reorganization based on the LI remain contradictory. A resting-state fMRI study found lower language LIs in patients with left anterior (compared to posterior) tumors (Gohel et al., 2019), while other studies observed a trend towards the opposite pattern (Deng et al., 2015), or no difference in language laterality between anterior and posterior lesions (Nadkarni et al., 2015). Furthermore, Polczyńska et al. (2021) emphasize that decreased language dominance in tumor patients, based on the LI, is not necessarily a sign of functional reorganization. In their study, 60

patients with left-hemispheric or right-hemispheric tumors underwent preoperative fMRI. Both groups were subdivided in 15 cases with anterior or posterior lesions each. Although tumors located in the left anterior hemisphere significantly reduced the estimates of language dominance when derived from the signal in Broca's area, this finding did not go along with a lower risk of post-surgical language-impairment. The authors emphasize that decreased language lateralization can not only occur due to increased activity in the non-affected hemisphere, but also due to weaker activations in language areas close to the lesion. This study did not show significant activation changes in the right hemisphere that would suggest contralesional compensation or disinhibition to be the primary cause of the altered language laterality in patients with tumors in the language-dominant hemisphere. The strong variability between studies likely results from methodological differences such as employed language task, variation in the patient groups, and lesion locations.

In addition, Deng et al. (2015) compared patients with arteriovenous malformations (AVM) (n = 63) and gliomas (n = 38). Both groups showed right-hemispheric activation when performing a silent reading task. However, while patients with AVMs showed a clear pattern of reorganization in right homologue regions (either Broca's or Wernicke's region depending on the tumor location), such a clear dissociation could not be found in patients with gliomas.

PET studies further support contralateral reorganization in brain tumors. Thiel et al. (2001) examined 61 patients, who were predominantly affected by low-grade gliomas. In addition to intrahemispheric reorganization patterns, they found fronto-lateral language activation in the non-dominant hemisphere in patients with frontal or posterior temporal lesions. Two combined PET-TMS studies further support the notion of compensatory reorganization in the right hemisphere (Thiel et al., 2005; Thiel et al., 2006). The first study investigated language lateralization in the IFG during verb generation in 14 glioma patients and five healthy control subjects. All participants were susceptible to TMS over the left IFG. However, some patients also showed functional deterioration when stimulated over the right IFG. Additionally, the second study showed that the rightward shift of language function was positively correlated with disease duration and language performance. The authors concluded that only slow growing lesions allow successful integration of the right hemisphere. Krieg et al. (2013) performed preoperative rTMS mapping during object naming in 15 patients with tumors in left-hemispheric language regions and 50 healthy controls. Patients showed overall significantly lower hemispheric dominance than healthy controls, suggesting more right-lateralized language function. However, there were no significant differences between targeted subregions, which may be attributed to the small sample size. Rösler et al. (2014) report a similar picture. Here, rTMS mapping was carried out in 50 patients with left-hemispheric gliomas and 15 healthy volunteers. While healthy subjects produced more errors when stimulated on the left side, patients showed a more bilateral error pattern. Interestingly, the nature of errors also differed between the two groups. While healthy subjects mainly produced dysarthric errors, patients tended to show more semantic errors. A recent study on 90 patients combined preoperative rTMS with machine learning to classify the observed patterns of functional reorganization (Wang et al., 2020). 32.2 % of patients were diagnosed as aphasic according to a test battery. Aphasic patients showed an increased vulnerability of the right IFG to rTMS during picture naming, which argues for the functional relevance of this area for language reorganization. However, classification based on a support vector machine revealed no clear effect of tumor location.

Further evidence for preoperative contralesional reorganization comes from MEG (Piai et al., 2019). Here, 14 patients with tumors in the language-dominant hemisphere performed a picture word interference task during MEG. At the behavioral level, all but one patient showed the typical interference effects. However, in contrast to healthy participants, this effect had a right-hemispherical source. The results thus support reorganization of language functions in the right hemisphere. Similar

results were found in an MEG-study with 12 patients harboring gliomas adjacent to left Broca's or Wernicke's region (Grummich et al., 2005). Here, nine of 12 patients showed strong bilateral MEG activity in language regions during different language tasks.

Comparisons of pre- and postoperative language lateralization further support right-hemispheric reorganization. For example, Duffau et al. (2001a) describe a case with a glioma in the left insula. Resection of the insula was possible without inducing language disturbance. The patient even recovered from preoperative aphasia. fMRI and DES showed that the left STG, left putamen and right insula were involved in functional reorganization. Another fMRI study (Gębska-Kośla et al., 2017) investigated 10 patients with low- and high-grade gliomas both pre- and postoperatively. In 5 patients each, the brain tumor was located near Broca's or Wernicke's area, respectively. All patients showed preoperative activity in left Broca's area. Interestingly, all patients without language impairment had additional activity in the right Broca homologue. Postoperatively, bilateral Broca's activity increased in two patients. In two other patients, activation increase in one of the two Broca's areas was accompanied by an activation decrease in the contralateral homologue. In all patients with temporal tumors, activity was found in right Wernicke's area both pre- and postoperatively. In two aphasic patients, activity decreased postoperatively in both Broca's areas and instead increased in one of the two Wernicke's areas. These results provide evidence for right-hemispheric language reorganization when the tumor is located in left frontal regions. In cases with temporal tumor location, the results are less clear.

Buklina et al. (2017) provide evidence for postoperative right-hemispheric reorganization in both patients with frontal ( $n = 12$ ) and temporal ( $n = 8$ ) tumor location. Simultaneous activation in right Broca's and right Wernicke's area was more often detected in patients with left frontal lesions. Activation in right homologues was found in all patients for up to one year after surgery and often went along with no or only mild aphasic symptoms. However, they did not find a correlation between language recovery and brain activation.

In a recent study (Zimmermann et al., 2020), fMRI and MEG were combined to investigate pre- and postoperative reorganization processes in patients with left-hemispheric brain tumors. Both methods found signs of reorganization in 29 % (5 of 17) of patients. These patients had intact language functions and showed no clear language activity in at least one of the examined subregions in the dominant hemisphere. Instead, signals were measured in contralateral regions. However, this shift of functional language regions to the right hemisphere was limited to patients with oligodendrogliomas and astrocytomas. Patients with glioblastomas or non-gliomatous lesions showed no signs of contralateral reorganization.

A few studies used non-invasive brain stimulation to map contralateral reorganization in a pre- and post-operative comparison (e.g., Ille et al., 2019; Kawashima et al., 2013). For example, Ille et al. (2019) conducted repeated rTMS prior to consecutive surgeries in patients affected by gliomas in left perisylvian regions. While the number of language positive sites in the vicinity of the tumor decreased over time, a shift of language function to the right hemisphere was measured in many cases.

A large MEG study with 73 glioma patients who underwent repeated tumor resections by Traut et al. (2019) further supports right-hemispheric reorganization in patients with gliomas. These authors found that patients with tumors in the language-dominant hemisphere experienced a pronounced laterality shift during MEG. This shift particularly affected patients with a preoperatively high LL, while patients with a preoperatively more bilateral language organization showed less postoperative signs of further reorganization.

To summarize, there is strong evidence for right-hemispheric reorganization in patients with tumors in left-hemispheric language areas. However, the adaptive vs maladaptive role of the right hemisphere for language reorganization is debated, since it does not always go along with optimal performance in glioma patients (e.g., Krieg et al., 2013;

Meyer et al., 2003). This parallels the debate about right-hemispheric reorganization in patients with post-stroke aphasia. Furthermore, not all brain regions have an equally strong potential for effective reorganization in right homologues (e.g., Turkeltaub et al., 2011). Nevertheless, especially tumors in frontal regions seem to frequently cause contralateral reorganization. The larger number of patients who show intact language abilities in combination with right-hemispheric activity strongly speaks for a functional rather than a dysfunctional role of language homologues in the right hemisphere.

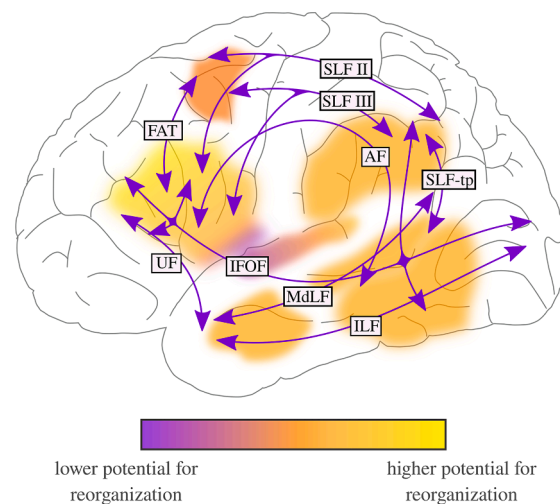
#### 4. Network connectivity and subcortical plasticity

An increasing number of studies emphasizes the contribution of subcortical areas and fiber connections to language reorganization. An overview of the reorganization potential of cortical and subcortical regions within the language network is given in Fig. 6. Structural connections not only allow the interaction within and between brain networks, but also restrict functional reorganization after damage (e.g., Duffau, 2009a; Duffau & Taillandier, 2015). There is converging evidence for a key role of structural and functional connectivity for language reorganization in patients with cerebral tumors, as will be discussed in the following sections (see Table 2 for details of each study).

##### 4.1. Structural connectivity

Diffuse gliomas migrate along white matter pathways and invade them five times more often than grey matter regions (Smits et al., 2015; Szalicsnyo et al., 2013). Given the relatively low plastic potential of the white matter (e.g., Picart et al., 2019), subcortical tumors often also limit functional reorganization. Several studies demonstrated that healthy people usually show a low inter-subject variability of white matter pathways (e.g., Cargnelutti et al., 2020a; Gil-Robles et al., 2008). Additionally, glioma resection is significantly more often subtotal if the tumor infiltrated subcortical connections compared to cortically located lesions (e.g., Herbet et al., 2016; Ius et al., 2011), since damage of white matter pathways is associated with functional impairment (e.g., Sierpowska et al., 2015). For example, Caverzasi et al. (2016) showed that the AF and the temporoparietal component of the SLF (SLF-tp), which form the dorsal language pathway, are particularly relevant for the preservation of language functions. Additionally, Tuncer et al. (2021) found that lesions underlying the temporo-parieto-occipital junction (temporo-parietal AF, middle IFOF, middle ILF) and the temporal stem/peri-insular white matter (middle IFOF, anterior ILF, temporal UF, temporal AF) are associated with a high risk of permanent aphasia. Ius et al. (2011) introduced one of the first atlases of functional resectability based on the DES results of 58 patients with glioma. They defined a core of essential, non-compensable (and therefore non-resectable) brain structures as the "minimal common brain". As shown by Latini et al. (2021), the infiltration of the subcortical insula and the basal ganglia, which are considered as part of this "minimal common brain" is correlated with significantly higher risk for neuropsychological and language impairment since tumors in these regions attack subcortical fiber connections, which support large networks and critical functional hubs (e.g., Duffau, 2014; Duffau, 2020; Ghinda & Duffau, 2017; Kong et al., 2016; Latini et al., 2021). The notion of a minimal common brain is supported by several other studies (e.g., Herbet et al., 2016; Sarubbo et al., 2015), although these reports point towards a certain degree of subcortical plasticity (see also Cargnelutti et al., 2020a). As discussed in the following section, connectivity changes in glioma patients can be detected by a variety of methods such as DES (e.g., Papagno et al., 2011; Papagno et al., 2014), DTI (e.g., Jehna et al., 2017; Kinoshita et al., 2014), MEG (e.g., Amoroso et al., 2021) and rTMS (e.g., Sollmann et al., 2017).

Earlier work shows that cortical language reorganization always occurs along the same white-matter pathways that originally connected areas within the respective network (Papagno et al., 2011; Papagno



**Fig. 6. Schematic illustration of the potential for reorganization of cortical and subcortical brain regions.** The blurry spots show the main cortical regions of the language network. The subcortical fiber connections are represented by arrows. Yellow regions represent higher reorganization potential. Purple regions represent lower reorganization potential. Note that this is a highly simplified illustration and that the potential for reorganization is dependent on multiple factors. In addition, the level of evidence varies for the individual brain regions. AF = arcuate fasciculus; FAT = frontal aslant tract; IFOF = inferior fronto-occipital fasciculus; ILF = inferior longitudinal fasciculus; MdLF = medial longitudinal fasciculus; SLF = superior longitudinal fasciculus; SLF II = superior longitudinal fasciculus, branch 2; SLF III = superior longitudinal fasciculus, branch 3; SLF-tp = superior longitudinal fasciculus, temporo-parietal part; UF = uncinata fasciculus.

et al., 2014). These authors investigated factors limiting cortical reorganization in 38 tumor patients with DES during object naming, with a focus on long-distance subcortical connectivity between relevant cortical regions. DES led to category-specific naming difficulties not only during the stimulation of cortical regions, but also during the stimulation of the underlying subcortical white matter pathways. DES further identified domain-specific cortical regions that presumably reflected reorganization processes. These regions were strategically located such that they remained connected to the underlying subcortical tracts (Papagno et al., 2011). In a follow-up with 17 patients who underwent resection of a glioma either in the frontal or temporal pole, only the patients in whom parts of the uncinata fasciculus had to be resected had long-lasting naming difficulties. Tumor location did not have a significant effect on the postoperative functional outcome (Papagno et al., 2014). These results provide evidence for the critical role of subcortical pathways in object naming and implicate that subcortical connectivity has a major impact on cortical reorganization.

Kinoshita et al. (2014) examined if the preoperative status of the arcuate fasciculus can be used as a predictor for postoperative language recovery. 12 patients with left hemispheric tumors underwent preoperative DTI as well as pre- and postoperative language testing. The authors found a positive relationship between higher preoperative structural integrity values (fractional anisotropy, FA) of the left AF and postoperative improvement in the overall language score. Thus, to some degree, higher preoperative FA values of the left AF seem to predict postoperative language recovery.

Comparable results are provided by Jehna et al. (2017). Here, probabilistic fiber tracking was used to investigate how language performance in 27 patients with gliomas in the language-dominant hemisphere is related to structural perisylvian pathways. While patients without clinical language impairment tended to have a more symmetrical or right lateralized AF, aphasic patients more often showed a left-lateralized posterior segment of the respective fascicle. These results may suggest that in patients without language impairment, the contralateral AF took over a compensatory function. However, it is worth to note that while patients with little or no language impairment were mostly affected by low-grade gliomas, patients with language disorders more often suffered from higher-grade tumors. Moreover, tumor location differed significantly between patient groups which may account for greater functional impairment. Additionally, Cargnelutti et al.

(2020b) compared reading performance and structural tract integrity in 13 low grade glioma patients one week and four months post-operatively. Behaviorally, reading scores of all patients improved over time. Furthermore, a significant increase in the length of streamlines of the direct AF segments in both hemispheres was observed after four months. Although behavioral and structural results were not significantly correlated, the results suggest some potential for reorganization of the AF. However, these results should be interpreted with caution since the change in streamline length and FA values could simply reflect the demasking of formerly hidden fibers due to postoperative edema and other surgical tissue effects. Complementing these results, Zheng et al. (2013) found increased anisotropy in the left inferior longitudinal fasciculus (ILF) and inferior fronto-occipital fasciculus (IFOF) in patients with left frontal low grade gliomas and preserved language functions, compared to controls. These results suggest that improved communication along these pathways may support compensation. Furthermore, Herbet et al. (2018) showed that information transfer via the ILF can be rerouted under certain circumstances, namely when the temporal pole is so severely damaged that it abandons its function. These results are further in line with former studies (e.g., Duffau et al., 2009; Ius et al., 2011), which demonstrated that compensation of the ILF is possible, as long as only the anterior and not the posterior portion is infiltrated by the tumor.

Further evidence for changes in structural connectivity are provided by a recent MEG-study (Amoruso et al., 2021). Patients with tumors in left ventral ( $n = 6$ ) or dorsal brain regions ( $n = 6$ ) were compared with 20 controls in a longitudinal design comprising two sessions of picture naming during MEG for each patient (preoperatively and 3 months postoperatively). MEG in healthy controls showed segregated beta power decreases in left ventral and dorsal pathways in a time window associated with lexico-semantic processing. Longitudinal patient data showed beta-compensation, which seemed to mimic category-based segregation in controls, since ventral and dorsal damage led to selective compensation for object and action naming, respectively. All patients exhibited preoperative changes in structural connectivity, evident as laterality differences of the IFOF, AF and SLF relative to controls, which probably reflects plasticity triggered by tumor growth. Post-operatively, some patients still showed a rightward shift of SLF lateralization, which was correlated with changes in beta power lateralization towards the contralesional hemisphere. Longitudinal beta modulations

**Table 2**  
Studies that report changes in structural or functional connectivity in patients with cerebral gliomas.

Structural Connectivity							
Study	N	Main findings	Tumor location	Tumor grade	Methods	Surgery	Task
Ius et al. (2011), NeuroImage	58 patients	Atlas of functional resectability	Various locations	Low-grade gliomas	Intraoperative DES, postoperative MRI	Single surgery	Picture naming
Picart et al. (2019), Neurosurgery	42 patients	Neuroplasticity was most effective in patients with sharply bordered tumors. Tumor invasion of white matter tracts was the main limitation of neuroplasticity	Supratentorial regions	Gliomas (WHO grade II-III)	Intraoperative DES	Repeated surgeries	Not described
Papagno et al. (2011), NeuroImage	38 patients	Cortical language reorganization happens along the same white-matter pathways that originally connected areas within the respective network	Various locations	All kinds of gliomas	Intraoperative DES	Single surgery	Object naming
Sollmann et al. (2017), Journal of Neurosurgery	38 patients	Interhemispheric connectivity detected by preoperative TMS-based DTI-FT might be a risk factor for surgery-related aphasia	Left hemispheric perisylvian regions	All kinds of gliomas	Preoperative rTMS-based DTI-FT	Single surgery	Object naming
Jehna et al. (2017), Journal of Neurosurgery	27 patients	Supportive role of right-hemispheric pathways (focus on AF) in patients with left-sided tumors	Left hemispheric regions	Low-grade gliomas	Preoperative MRI and DTI-FT	Single surgery	No task
Duffau et al. (2009), Neurosurgical Focus	24 patients	Indirect evidence for the compensation of UF and ILF	Dominant insula	Low-grade gliomas	Intraoperative DES	Repeated surgeries in 3 cases	Counting, picture naming
Papagno et al. (2014), Brain Structure and Function	17 patients	Patients, in which parts of the UF were resected, recovered in verbal fluency and object naming, but not in naming of famous faces	Left frontal or temporal regions	All kinds of gliomas	Postoperative MRI and DTI-FT	Single surgery	Word generation (semantic), object naming, naming of famous faces
Cargnelutti et al. (2020b), Frontiers in Neurology	13 patients	Significant increase in length of streamlines of the direct AF segments in both hemispheres during postoperative follow-up	Left hemispheric regions	Low-grade gliomas	Pre- and postoperative DTI-FA	Single surgery	No task
Kinoshita et al. (2014), Clinical Neurology and Neurosurgery	12 patients	Relationship between preoperatively increasing FA-values of the left AF and postoperative language improvement	Left hemispheric regions	All kinds of gliomas	Preoperative MRI and DTI-FA	Single surgery	No task
Herbet et al. (2018), Cognitive Neuropsychology	11 patients	In case the anterior temporal lobe loses its function, the ILF seems to be rerouted	Anterior temporal lobe or temporal lobe	Low-grade gliomas	Intraoperative DES	Single surgery	Counting, picture naming, PPTT, reading of words and pseudowords
Zheng et al. (2013), Neural Regeneration Research	10 patients, 10 healthy subjects	Patients showed higher FA and LI values in the left ILF and higher LI values in the left IFOF than controls > might be a sign of plasticity in the ventral language pathway	Regions affecting dorsal language pathways	Low-grade gliomas	Preoperative MRI and DTI-FA	Single surgery	No task
Amoruso et al. (2021), Human Brain Mapping	6 patients, 20 healthy subjects	Patients showed changes in oscillatory activity and structural connectivity compared to controls	Left hemispheric ventral (n = 3) and dorsal (n = 3) regions	Low-grade gliomas	Pre- and postoperative MEG and MRI	Single surgery	Object vs action naming
Sierpowska et al. (2015), Brain and Language	1 patient	Disruption of the left frontal aslant white matter tract leads to morphological overregularization strategy	Left premotor-frontal area	Glioma (WHO grade III)	Pre- and postoperative fMRI and DTI, intraoperative DES	Single surgery	Verb generation
Functional Connectivity							
Study	N	Main findings	Tumor location	Tumor grade	Methods	Surgery	Task
Yuan et al. (2020), Cortex	130 patients (LGG: n = 77; HGG: n = 53)	Tumor grade related network reorganization of both language and control networks underlie the different levels of language impairments	Left hemispheric regions	All kinds of gliomas	Preoperative fMRI	Single surgery	Resting state
Jin et al. (2021), Frontiers in Oncology	109 patients, 42 healthy subjects	Left-hemispheric gliomas had a bigger and more distributed impact on FC than right-hemispheric gliomas	Language areas	All kinds of gliomas	Preoperative fMRI	Single surgery	Resting state
Tarapore et al. (2012), Neurosurgery	79 patients	Increased FC was a risk factor for postoperative aphasia	Various locations	All kinds of gliomas	Preoperative MRI and MEG, intraoperative DES Preoperative fMRI	Single surgery	Resting state Verbal fluency

(continued on next page)

Table 2 (continued)

Structural Connectivity							
Study	N	Main findings	Tumor location	Tumor grade	Methods	Surgery	Task
Voets et al. (2019), <i>NeuroImage: Clinical</i>	44 patients, 23 healthy subjects	Patients showed highly variable and atypical connectivity “fingerprints” compared to controls	Language dominant hemisphere	All kinds of gliomas		Single surgery	
Briganti et al. (2012), <i>American Journal of Neuroradiology</i>	39 patients, 13 healthy subjects	FC connectivity is influenced by tumor position. However, changes in FC are not locally restricted, but they affect even remote and contralateral areas	Left hemispheric regions	All kinds of gliomas	Preoperative fMRI	Single surgery	verb generation, resting state
Van Dokkum et al. (2019), <i>NeuroImage: Clinical</i>	39 patients, 19 healthy subjects	Adaptive plasticity occurs across different networks to compensate for a lesion	Left hemispheric language regions	Low-grade gliomas	Intraoperative DES, pre- and postoperative fMRI	Single surgery	Resting state
Deverduin et al. (2019), <i>Brain Imaging and Behaviour</i>	32 patients, 19 healthy subjects	Patients recruited alternative networks than healthy controls	Left hemispheric regions	Low-grade gliomas	Pre- and postoperative fMRI	Single surgery	Picture naming
Lee et al. (2021), <i>Journal of Neurosurgery</i>	26 patients	Resection of DES-negative sites, which showed high FC in MEG, resulted in transient postoperative language impairment	Left hemispheric regions	All kinds of gliomas	Preoperative MEG, intraoperative DES	Single surgery	Resting state
Voets et al. (2021), <i>NeuroImage: Clinical</i>	19 patients, 17 healthy subjects	Connectivity fingerprints of dorsal and ventral language systems can be affected independently of each other.	Frontal and/or temporal lobe within the language dominant hemisphere	All kinds of gliomas	Pre- and postoperative fMRI	Single surgery	Letter fluency, PPTT
Douw et al. (2008), <i>Experimental Neurology</i>	15 patients	Complex changes in FC after surgery which could be interpreted as a tendency toward “normalization”	Various locations (left: n = 9; right: n = 6)	All kinds of gliomas	Pre- and postoperative MEG	Single surgery	Resting state
Lizarazu et al. (2020), <i>Brain and Language</i>	12 patients	Increased FC in peritumoral regions in both postoperative sessions	Left hemispheric language regions	Low-grade gliomas	Pre- and postoperative (2x) MEG	Single surgery	Resting state
Li et al. (2019), <i>Frontiers in Neurology</i>	1 patient	Right Broca’s area was functionally connected to the same areas as left Broca’s area typically does in healthy controls. Connection between right Broca’s area and left Wernicke’s area was indirect, mediated by pre-SMA and MFG	Left fronto-temporal insula	Low-grade glioma	Pre- and postoperative fMRI, intraoperative DES	Repeated surgeries	Verbal fluency, semantic fluency

**Abbreviations:** AF: Arcuate Fasciculus; DES: Direct electrical Stimulation; DTI: Diffusion Tensor Imaging; DTI-FA: Fractional Anisotropy; DTI-FT: Fiber Tracking; FC: Functional Connectivity; (f)MRI: (functional) Magnetic Resonance Imaging; IFOF: Inferior Fronto-Occipital Fasciculus; ILF: Inferior Longitudinal Fasciculus; LI: Laterality Index; MEG: Magnetoencephalography; MFG: Middle Frontal Gyrus; PPTT: Pyramids and Palm Trees Test; rTMS: repetitive Transcranial Magnetic Stimulation; SMA: Supplementary Motor Area; UF: Uncinate Fasciculus; WHO: World Health Organization.

in patients with ventral lesions were located in areas of the semantic control network (Noonan et al., 2013; Wright et al., 2012) which showed activation in controls during object naming. These results might reflect compensation by spared regions within the language network. Patients with dorsal lesions showed longitudinal beta power modulations in bilateral frontal regions which might reflect language reorganization due to demasking of a homologous network.

In summary, the subcortical potential for plasticity is limited and cortical reorganization follows the course of relatively fixed white matter pathways. However, changes in intra- as well as inter-hemispheric connectivity can support the maintenance of language function.

#### 4.2. Functional connectivity

An increasing number of fMRI and MEG studies focusses on functional connectivity in patients with cerebral tumors. For example, Briganti et al. (2012) showed that functional connectivity is influenced by the preoperative tumor location. Using fMRI, they examined 39 patients with left hemispheric anterior and posterior gliomas and 13 healthy control subjects during verb generation and rest. Results showed that functional connectivity of the language network was significantly reduced in tumor patients compared to healthy control subjects, which was driven by patients with posterior gliomas. These patients also

showed significantly stronger decreases in functional connectivity compared to patients with anterior gliomas. Functional connectivity was particularly affected within left hemispheric regions and between both temporoparietal junctions, implicating that tumors primarily impair connectivity in the ipsilateral hemisphere.

A recent study by Jin et al. (2021) further supports the assumption that tumor location influences functional connectivity. Here, 109 patients with gliomas in language-related regions and 42 healthy control subjects were examined with preoperative resting-state fMRI. Patients showed significantly reduced functional connectivity in the language network, which strongly depended on tumor location: Left-hemispheric gliomas had a significantly greater impact on functional connectivity than right hemispheric gliomas.

Other work points towards differences in tumor type on network integrity for language and cognitive control functions (Yuan et al., 2020). In that study, 130 patients with left cerebral gliomas were investigated, including 77 patients with low-grade glioma (WHO grade I/II), 53 patients with high-grade glioma (WHO grade III/IV) as well as 38 healthy controls. In patients, tumor grade was negatively correlated with language scores and language network integrity during resting-state fMRI. Compared to healthy controls, patients with low-grade gliomas exhibited slight language deficits, changes in resting state functional connectivity of the language network (decreases and increases), and nearly normal connectivity in cognitive control networks. Patients

with high-grade gliomas, on the other hand, had significantly lower language scores than those with low-grade gliomas and more severe disruptions of the language and control networks. Furthermore, decreased resting-state connectivity of the language network was positively correlated with language scores in patients with high-grade gliomas. Consequently, tumor grade-related network reorganization of language and control networks appears to be associated with different levels of language impairments. Differences in network connectivity relative to healthy controls were stronger in high-grade glioma patients than in low-grade glioma patients, while tumor location and volume had minimal effects on linguistic abilities. These results seem to contrast other studies. For example, [Smits et al. \(2015\)](#) found that tumor location, but not tumor volume, correlated with neurological function in patients with low-grade gliomas, and [Deverdun et al. \(2019\)](#) reported that tumor location in the left posterior middle temporal gyrus was inversely correlated with language deficits in low-grade glioma patients. These differences may be explained by a relatively rough group allocation in [Yuan et al. \(2020\)](#), which may have disguised tumor location effects.

[Voets et al. \(2019\)](#) compared functional connectivity patterns (“connectivity fingerprints”) of healthy people and patients with tumors in the language-dominant hemisphere during a verbal fluency task. Patients showed highly variable and atypical fingerprints of brain plasticity, which were mainly influenced by tumor grade and tumor location. About 50 % of the patients showed statistically atypical connectivity patterns in the pars opercularis. The LIs also varied among patients, with 14 % of patients showing bilateral or right hemispheric dominance. Interestingly, ipsilateral putamen, right pars opercularis and right ventral premotor cortex were significant predictors of group (patient vs control). Tumor grade predicted connectivity between left pars opercularis and ipsilateral caudatum, although it did not explain increased contralateral coupling.

[Tarapore et al. \(2012\)](#) used preoperative resting state MEG to investigate functional connectivity in 79 patients with gliomas in motor, sensory or language regions. They found a correlation between the connectivity values of the resected tissue and the neurological impairment one week and six months postoperatively. More precisely, patients with increased functional connectivity values had a higher risk of postoperative impairment compared to those with decreased connectivity values.

A couple of studies investigated functional connectivity in a pre- vs postoperative comparison. For example, [Voets et al. \(2021\)](#) used different language tasks during fMRI in 19 patients with gliomas in the language dominant hemisphere and 17 controls. Preoperatively, patients showed slower phonological fluency performance than controls, while no differences in semantic accuracy were found. While controls improved over time, patients’ performance did not change postoperatively. Task-related connectivity fingerprints were highly reproducible in controls, while patients showed more unique patterns. Preoperatively, fluency fingerprints deviated significantly from the typical network in 11/19 patients and semantic fingerprints deviated in 5/19 patients. Postoperatively, in 9 of 19 patients (47.4 %, 3 low-grade, 6 high-grade) fluency related fingerprints and in 3 of 19 patients (15.8 %, all ‘high grade’) semantic fingerprints differed from the normal task-network. Again, no consistent reorganization pattern was found. While these results do not allow clear conclusions on process-specific reorganization patterns, they suggest that surgery can affect word-generation (dorsal) and semantic-association (ventral) systems independently and to different extents. The presence of language impairments, at diagnosis or after surgery, was the strongest predictor of altered network connectivity. In contrast, tumor grade did not have a significant influence on the likelihood of atypical fingerprints, presumably because of the small sample size. However, histological grading influenced sub-components of each task fingerprint. While 21 % of patients showed atypical language networks in the postoperative measurement, language networks “normalized” in 10 % of patients. In some cases, fingerprints

were always “normal” compared to controls, but still differed in the pre- and postoperative measurement. Approximately half of the patients who had an atypical network before surgery remained atypical after surgery. Some patients showed post-operative normalization of preoperatively atypical networks while others exhibited new reorganization patterns after surgery for uncertain reasons.

Complementing these results, [Deverdun et al. \(2019\)](#) investigated pre- to postoperative functional connectivity changes in patients with diffuse low-grade gliomas ( $n = 32$ ), compared to healthy controls ( $n = 19$ ) during lexical access. The results showed significant differences in functional and anatomical connectivity. Impaired picture naming performance in patients went along with decreased activations in the left parahippocampal gyrus in the preoperative phase and increased post-operative involvement of the left lingual gyrus. Likewise, connectivity patterns were also altered. However, since altered functional connectivity was associated with impaired language performance, it remains unclear if these changes reflect an attempt for (unsuccessful) compensation or maladaptive plasticity.

[Van Dokkum et al. \(2019\)](#) used resting state fMRI to identify functional connectivity in glioma patients before and three months after surgery and compared the connectivity patterns with those of healthy controls. Better task performance during behavioral language testing was associated with the integrity of the semantic network in patients. Furthermore, a stronger involvement of the fronto-parietal attention network may have compensated for impaired language functions in glioma patients.

Finally, three studies used MEG to investigate pre- to postoperative changes in functional connectivity. [Douw et al. \(2008\)](#) compared pre- to postoperative changes in functional connectivity in 15 patients with brain tumors (9 left, 6 right) with MEG at rest. The phase lag index (PLI) was used to reveal synchronous intra- and interhemispheric neural activity. After tumor resection, functional connectivity changed in a complex way, depending on the frequency band and whether inter- and/or intrahemispheric connectivity was considered. Postoperative analyses revealed a significant decrease in interhemispheric theta synchronization, which may have reflected a tendency towards a normalized state of theta activity after tumor resection. [Lizarazu et al. \(2020\)](#) investigated functional connectivity changes from the pre- to the post-operative phase (after three and six months) in patients with left-sided, low-grade gliomas. Regardless of the tumor location, all patients showed alpha connectivity enhancement in perilesional regions already-three months after surgery, which was interpreted as functional language reorganization. The same reorganization patterns were still present six months postoperatively. In contrast, no significant increases in functional connectivity were found in contralesional regions. As a potential explanation, the authors argue that contralesional reorganization may already have taken place preoperatively ([Lizarazu et al., 2020](#)). A longitudinal study by [Lee et al. \(2021\)](#) investigated 26 patients with left-sided low- and high-grade gliomas in various brain regions with resting-state MEG and intraoperative DES. Additionally, subjects performed language evaluation at multiple time points. Resection of DES-negative sites which showed high functional connectivity resulted in an early transient postoperative language decline, which resolved after three months in all but two cases. Postoperative naming and syntactic impairment were linearly correlated with the percentage of resected high functional connectivity sites. These results implicate that DES does not always detect areas of high functional connectivity. The authors assume that DES-positive sites might have greater functional connectivity to the surrounding cortex (see also [Rolston & Chang, 2018](#)), which may be particularly relevant for the employed language tasks. Overall, the results show that aphasia after glioma resection is often transient and can even resolve after the resection of nodes with high functional connectivity. Additionally, unaffected hub nodes may represent compensatory regions for language processing ([Lee et al., 2021](#)).

In summary, functional connectivity changes in patients with left-



hemispheric gliomas can be observed pre- and postoperatively. Although connectivity patterns differ strongly between patients, tumor grade as well as tumor localization are some of the most relevant influencing factors. However, since language impairment seems to be a predictor for altered functional network connectivity, some changes in functional connectivity might rather be maladaptive than supportive for language function, and the exact contribution of such changes remains unclear.

## 5. Conclusions and future directions

Overall, patients with language eloquent cerebral gliomas seem to have a relatively high potential for neuroplasticity, since many of them show no or only slight preoperative language impairment and gliomas can often be resected without causing permanent harm. Based on the afore discussed evidence, functional reorganization usually proceeds in a hierarchical order by first recruiting peri- and intralesional regions and later contralesional regions for compensation (e.g., [Cargnelutti et al., 2020a](#)). However, these mechanisms are mainly observed in slow growing, well-circumscribed lesions which predominantly affect cortical brain areas. High-grade tumors, which infiltrate the brain more aggressively, provide less time for reorganization and lead to a faster exhaustion of the potential for neural plasticity. Additionally, age seems to be a risk factor for less effective functional reshaping (e.g., [Latini et al., 2021](#)). With respect to different language functions, few studies showed that these can be functionally reorganized independently of each other (e.g., [Papagno et al., 2014](#)).

Tumor surgery often promotes further functional reorganization, as shown by repeated surgeries. Nevertheless, postsurgical reorganization seems to be strongly related to the amount of plasticity that was already exhausted preoperatively. Consequently, early resection of relatively small lesions allows more postoperative plasticity (e.g., [Košla et al., 2015](#); [Southwell et al., 2016](#)). However, the main limitation for functional reorganization is the infiltration of subcortical fiber connections, since cortical reorganization seems to depend on the integrity of a “minimal common brain” ([Jus et al., 2011](#)) and relies on relatively immutable white matter pathways (e.g., [Papagno et al., 2011](#)).

The existing studies show that, like stroke, gliomas affect entire neural networks and influence both domain-specific and domain-general functions. Compared to the plasticity mechanisms after stroke, however, reorganization in patients with gliomas differs significantly. While language recovery in stroke patients occurs in three phases (acute, post-acute, chronic) (e.g., [Hillis & Heidler, 2002](#); [Pedersen et al., 2004](#); [Petersen et al., 1988](#)), in tumor patients, a main distinction can be made between the preoperative and the postoperative phase (e.g., [Cargnelutti et al., 2020a](#)). Long-term reorganization processes are already taking place preoperatively due to tumor growth, which often help to preserve function (e.g., [Gil-Robles et al., 2008](#); [Mandonnet et al., 2003](#)). Postoperatively, tumor patients often show transient aphasic symptoms. As in the acute and post-acute phase after a stroke, most language recovery then takes place in the first weeks to months after the surgery (e.g., [Duffau et al., 2003](#); [Krishna et al., 2021](#); [Satoer et al., 2014](#)). However, since tumor resections are carried out in a controlled manner and function is preserved to the highest possible degree, most glioma patients, in contrast to stroke patients, recover completely from their aphasia (e.g., [Ojemann et al., 1996](#)). With respect to the debate about the role of the right hemisphere in language recovery after brain lesions, the tumor literature strongly argues for a compensatory and supportive role of right-hemispheric regions. Many studies reported about patients with only slightly or unimpaired language functions, who showed right-hemispheric brain activity (e.g., [Cargnelutti et al., 2020b](#); [Gunal et al., 2018](#); [Rosenberg et al., 2008](#)). Nevertheless, right-hemispheric reorganization seems to occur rather late in the course of the disease, when intrahemispheric plasticity is already utilized (e.g., [Cargnelutti et al., 2020a](#)).

We note that the above-discussed results need to be interpreted with

caution for several reasons. Most included studies are underpowered due to small sample sizes. Moreover, the high variability of patient and tumor characteristics makes it hard to draw general conclusions. Patients differ strongly concerning several parameters like tumor grade, tumor size and resection volume, age, stage of disease and surgical treatment. In many studies, patient data were reported pre- or postoperatively only. As shown in this review, all these factors seem to influence neural plasticity. Furthermore, adjuvant treatment like chemo- and radiotherapy, but also speech and language therapy were not consistent within and between studies, and many studies do not even report such factors. Therefore, possible effects of adjuvant treatment on language reorganization are largely unknown. Moreover, the use of different methods across studies biases the results. For example, DES is, due to its local and direct application, well suited to reveal intra- and perilesional function. Nevertheless, language function in more distributed intra- or interhemispheric regions cannot be detected by means of DES, since only a limited portion of the patient’s cortex is exposed during surgery (e.g., [Cirillo et al., 2019](#)). On the other hand, fMRI can uncover language activity and interactions in large-scale networks. However, it is more prone to false-negative activations in intralesional and perilesional regions due to neurovascular uncoupling (e.g., [Black et al., 2017](#)). Additionally, BOLD-activity detected by fMRI is not necessarily essential for language function. This is especially critical for tumor surgery since an optimal treatment always follows the goal of maximal resection while causing minimal functional impairment. To minimize these methodological biases, we included studies using different approaches in this review.

Another limitation is the lack of standardized paradigms to test language function in tumor patients. Most institutions use their own paradigms and sometimes these paradigms are not even consistent within studies. This complicates the interpretation of results and allows a relatively scarce mapping of language function in these patients only.

Future studies should include standardized paradigms in larger patient cohorts to increase the current knowledge about plasticity of the language network in patients with cerebral gliomas. This is particularly important since a better understanding of functional reorganization in this population is crucial for supplying patients with an optimal surgical as well as adjuvant treatment. Studies with larger participant numbers and well differentiated patient characteristics concerning age, tumor grade and tumor localization are needed. Moreover, studies should include age-matched healthy control groups. This is particularly important since gliomas are often diagnosed in middle- to older-aged people, an age-group which is even underrepresented in studies on unimpaired language processing.

Another aspect that has not been studied extensively to date is how gliomas affect language-related activity within the cerebellum. The cerebellum is known to show a crossed activation pattern with the contralateral cerebral hemisphere during language processing. However, there is some evidence that this crossed activation pattern can be altered in glioma patients ([Cho et al., 2018](#); [Zhang et al., 2018](#)). Furthermore, studies that combine different investigation methods are desirable to minimize methodological biases. We also plead for the use of more standardized paradigms to map language function. This would lead to a better comparability of results across different institutions and ensure uniform quality standards. The freely available paradigms provided by the American Society of Neuroradiology ([Black et al., 2017](#)) are a first step into this direction. Additionally, more fine-grained paradigms would be useful to investigate brain reorganization for specific language functions individually (e.g., by dissociating phonological and semantic processes in language comprehension and production). This is particularly important because many patients only show subtle impairments, some of which cannot even be detected in commonly used tests for aphasia diagnostics. However, also slight language impairments can critically affect a patient’s quality of life and might be decisive for successful rehabilitation. Consequently, more research about functional reorganization in tumor patients will not only extend our theoretical

knowledge about how language is processed in the lesioned brain, but it will also improve clinical treatment.

### Declaration of Competing Interest

The authors declare that they have no known competing financial interests or personal relationships that could have appeared to influence the work reported in this paper.

### Data availability

No data was used for the research described in the article.

### Acknowledgments

The present work was supported by the Max Planck Society and the University Hospital Halle (Saale). The authors declare no competing financial or nonfinancial interests. GH was supported by the Lise Meitner excellence program of the Max Planck Society and the Deutsche Forschungsgemeinschaft (HA 6314/3-1, HA 6314/4-1, HA6314/4-2).

### References

- Acioly, M., Gharabaghi, A., Zimmermann, C., Erb, M., Heckl, S., Tatagiba, M., 2014. Dissociated Language Functions: A Matter of Atypical Language Lateralization or Cerebral Plasticity? *Journal of Neurological Surgery Part A: Central European Neurosurgery* 75 (01), 064–069. <https://doi.org/10.1055/s-0033-1358610>.
- Amoruso, L., Geng, S., Molinaro, N., Timofeeva, P., Gisbert-Muñoz, S., Gil-Robles, S., Pomposo, I., Quiñones, L., Carreiras, M., 2021. Oscillatory and structural signatures of language plasticity in brain tumor patients: A longitudinal study. *Human Brain Mapping* 42 (6), 1777–1793. <https://doi.org/10.1002/hbm.25328>.
- Antonsson, M., Jakola, A., Longoni, F., Carstam, L., Hartelius, L., Thordstein, M., Tisell, M., 2018. Post-surgical effects on language in patients with presumed low-grade glioma. *Acta Neurologica Scandinavica* 137 (5), 469–480. <https://doi.org/10.1111/ane.12887>.
- Atlas, S.W., Howard, R.S., Maldjian, J., Alsop, D., Detre, J.A., Listerud, J., Stecker, M., 1996. Functional magnetic resonance imaging of regional brain activity in patients with intracerebral gliomas: findings and implications for clinical management. *Neurosurgery* 38 (2), 329–338.
- Avramescu-Murphy, M., Hatttingen, E., Forster, M.-T., Oszvald, A., Anti, S., Frisch, S., Russ, M.O., Jurcoane, A., 2016. Post-Surgical Language Reorganization Occurs in Tumors of the Dominant and Non-Dominant Hemisphere. *Clinical Neuroradiology* 27 (3), 299–309. <https://doi.org/10.1007/s00062-015-0496-6>.
- Banerjee, P., Leu, K., Harris, R.J., Cloughesy, T.F., Lai, A., Nghiemphu, P.L., Pope, W.B., Bookheimer, S.Y., Ellingson, B.M., 2015. Association between lesion location and language function in adult glioma using voxel-based lesion-symptom mapping. *NeuroImage: Clinical* 9, 617–624. <https://doi.org/10.1016/j.nicl.2015.10.010>.
- Barcia, J.A., Sanz, A., Balugo, P., Alonso-Lera, P., Brin, J.R., Yus, M., Gonzalez-Hidalgo, M., Acedo, V.M., Oliviero, A., 2012. High-frequency cortical subdural stimulation enhanced plasticity in surgery of a tumor in Broca's area. *NeuroReport* 23 (5), 304–309. <https://doi.org/10.1097/WNR.0b013e3283513307>.
- Benzagmout, M., Gatignol, P., Duffau, H., 2007. Resection of World Health Organization Grade II gliomas involving Broca's area: Methodological and functional considerations. *Neurosurgery* 61 (4), 741–753.
- Bizzi, A., Nava, S., Ferrè, F., Castelli, G., Aquino, D., Ciaraffa, F., Broggi, G., DiMeco, F., Piacentini, S., 2012. Aphasia induced by gliomas growing in the ventrolateral frontal region: Assessment with diffusion MR tractography, functional MRI imaging and neuropsychology. *Cortex* 48 (2), 255–272. <https://doi.org/10.1016/j.cortex.2011.11.015>.
- Black, D.F., Vachha, B., Mian, A., Faro, S.H., Maheshwari, M., Sair, H.I., Petrella, J.R., Pillai, J.J., Welker, K., 2017. American Society of Functional Neuroradiology-Recommended fMRI Paradigm Algorithms for Presurgical Language Assessment. *American Journal of Neuroradiology* 38 (10), E65–E73. <https://doi.org/10.3174/ajnr.A5345>.
- Breitenstein, C., Grewe, T., Flöel, A., Ziegler, W., Springer, L., Martus, P., Huber, W., Willmes, K., Ringelstein, E.B., Haeusler, K.G., Abel, S., Glindemann, R., Domahs, F., Regenbrecht, F., Schlenck, K.-J., Thomas, M., Obrig, H., de Langen, E., Rocker, R., Bamborschke, S., 2017. Intensive speech and language therapy in patients with chronic aphasia after stroke: A randomised, open-label, blinded-endpoint, controlled trial in a health-care setting. *The Lancet* 389 (10078), 1528–1538. [https://doi.org/10.1016/S0140-6736\(17\)30067-3](https://doi.org/10.1016/S0140-6736(17)30067-3).
- Briganti, C., Sestieri, C., Mattei, P.A., Esposito, R., Galzio, R.J., Tartaro, A., Romani, G.L., Caulo, M., 2012. Reorganization of Functional Connectivity of the Language Network in Patients with Brain Gliomas. *American Journal of Neuroradiology* 33 (10), 1983–1990. <https://doi.org/10.3174/ajnr.A3064>.
- Briones, T.L., Woods, J., 2014. Dysregulation in myelination mediated by persistent neuroinflammation: Possible mechanisms in chemotherapy-related cognitive impairment. *Brain, Behavior, and Immunity* 35, 23–32. <https://doi.org/10.1016/j.bbi.2013.07.175>.
- Brownsett, S.L.E., Warren, J.E., Geranmayeh, F., Woodhead, Z., Leech, R., Wise, R.J.S., 2014. Cognitive control and its impact on recovery from aphasic stroke. *Brain* 137 (1), 242–254. <https://doi.org/10.1093/brain/awt289>.
- Buklina, S. B., Batalov, A. I., Smirnov, A. S., Poddubskaya, A. A., Pitskhelauri, D. I., Kobayakov, G. L., Zhukov, V. Y., Goryaynov, S. A., Kulikov, A. S., Ogurtsova, A. A., Golanov, A. V., Varyukhina, M. D., & Pronin, I. N. (2017). Dynamics of the Functional MRI and Speech Function in Patients after Resection of Frontal and Temporal Lobe Tumors. *Burdenko Journal of Neurosurgery*, 81(3), 15-26. <https://doi.org/10.17116/engneiro201781315-26>.
- Buklina, S.B., Podoprigora, A.E., Pronin, I.N., Shishkina, L.V., Boldireva, G.N., Bondarenko, A.A., Fadeeva, L.M., Kornienko, V.N., Zhukov, V.Y., 2013. Functional MRI Studies of the Hemisphere Dominant for Speech in Patients with Brain Tumors. *Burdenko Journal of Neurosurgery* 5, 28–35.
- Butler, J.M., Rapp, S.R., Shaw, E.G., 2006. Managing the cognitive effects of brain tumor radiation therapy. *Current Treatment Options in Oncology* 7 (6), 517–523. <https://doi.org/10.1007/s11864-006-0026-5>.
- Campanella, F., Mondani, M., Skrap, M., Shallice, T., 2009. Semantic access dysphasia resulting from left temporal lobe tumours. *Brain* 132 (1), 87–102. <https://doi.org/10.1093/brain/awn302>.
- Cargnelutti, E., Ius, T., Skrap, M., Tomasino, B., 2020a. What do we know about pre- and postoperative plasticity in patients with glioma? A review of neuroimaging and intraoperative mapping studies. *NeuroImage: Clinical* 28, 102435. <https://doi.org/10.1016/j.nicl.2020.102435>.
- Cargnelutti, E., Maieron, M., Ius, T., Skrap, M., Tomasino, B., 2020b. Relation Between Reading Performance and White-Matter Alteration and Reorganization in Neurosurgical Patients. *Frontiers in Neurology* 11, 563259. <https://doi.org/10.3389/fneur.2020.563259>.
- Catani, M., Jones, D.K., ffytche, D. H., 2005. Perisylvian Language Networks of the Human Brain. *Annals of Neurology* 57 (1), 8–16. <https://doi.org/10.1002/ana.20319>.
- Caverzasi, E., Hervey-Jumper, S.L., Jordan, K.M., Lobach, I.V., Li, J., Panara, V., Racine, C.A., Sankaranarayanan, V., Amirbekian, B., Papinutto, N., Berger, M.S., Henry, R.G., 2016. Identifying preoperative language tracts and predicting postoperative functional recovery using HARDI q-ball fiber tractography in patients with gliomas. *Journal of neurosurgery* 125 (1), 33–45. <https://doi.org/10.3171/2015.6.JNS142203>.
- Cho, N.S., Peck, K.K., Zhang, Z., Holodny, A.I., 2018. Paradoxical Activation in the Cerebellum During Language fMRI in Patients with Brain Tumors: Possible Explanations Based on Neurovascular Uncoupling and Functional Reorganization. *The Cerebellum* 17 (3), 286–293. <https://doi.org/10.1007/s12311-017-0902-5>.
- Cirillo, S., Caulo, M., Pieri, V., Falini, A., Castellano, A., 2019. Role of Functional Imaging Techniques to Assess Motor and Language Cortical Plasticity in Glioma Patients: A Systematic Review. *Neural Plasticity* 2019, 1–16. <https://doi.org/10.1155/2019/4056436>.
- Coget, A., Deverdun, J., Bonafé, A., van Dokkum, L., Duffau, H., Molino, F., Le Bars, E., & de Champfleury, N. M. (2018). Transient immediate postoperative homotopic functional disconnectivity in low-grade glioma patients. *NeuroImage: Clinical*, 18, 656–662. <https://doi.org/10.1016/j.nicl.2018.02.023>.
- Crinion, J.T., Lefl, A.P., 2007. Recovery and treatment of aphasia after stroke: Functional imaging studies. *Current Opinion in Neurology* 20 (6), 667–673. <https://doi.org/10.1097/WCO.0b013e328282f1c6fa>.
- Croxson, P.L., Johansen-Berg, H., Behrens, T.E., Robson, M.D., Pinski, M.A., Gross, C.G., Richter, W., Richter, M.C., Kastner, S., Rushworth, M.F., 2005. Quantitative investigation of connections of the prefrontal cortex in the human and macaque using probabilistic diffusion tractography. *Journal of Neuroscience* 25 (39), 8854–8866. <https://doi.org/10.1523/JNEUROSCI.1311-05.2005>.
- Davis, S.W., Cabeza, R., 2015. Cross-Hemispheric Collaboration and Segregation Associated with Task Difficulty as Revealed by Structural and Functional Connectivity. *Journal of Neuroscience* 35 (21), 8191–8200. <https://doi.org/10.1523/JNEUROSCI.0464-15.2015>.
- De Schotten, M.T., Bizzi, A., Dell'Acqua, F., Allin, M., Walshe, M., Murray, R., Williams, S.C., Murphy, D.G.M., Catani, M., 2011. Atlasing location, asymmetry and inter-subject variability of white matter tracts in the human brain with MR diffusion tractography. *NeuroImage* 54 (1), 49–59. <https://doi.org/10.1016/j.neuroimage.2010.07.055>.
- De Witte, E., Van Hecke, W., Dua, G., De Surgeloose, D., Moens, M., Mariën, P., 2014. Atypical cerebral language dominance in a right-handed patient: An anatomoclinical study. *Clinical Neurology and Neurosurgery* 117, 12–21. <https://doi.org/10.1016/j.clineuro.2013.11.014>.
- Deng, X., Zhang, Y., Xu, L., Wang, B., Wang, S., Wu, J., Zhang, D., Wang, R., Wang, J., Zhao, J., 2015. Comparison of language cortex reorganization patterns between cerebral arteriovenous malformations and gliomas: A functional MRI study. *Journal of Neurosurgery* 122 (5), 996–1003. <https://doi.org/10.3171/2014.12.JNS14629>.
- Desmurget, M., Bonnetblanc, F., Duffau, H., 2007. Contrasting acute and slow-growing lesions: a new door to brain plasticity. *Brain* 130 (4), 898–914. <https://doi.org/10.1093/brain/awl300>.
- Deverdun, J., van Dokkum, L.E.H., Le Bars, E., Herbet, G., Mura, T., D'agata, B., Picot, M.-C., Menjot, N., Molino, F., Duffau, H., Moritz Gasser, S., 2019. Language reorganization after resection of low-grade gliomas: An fMRI task based connectivity study. *Brain imaging and behavior* 14 (5), 1779–1791. <https://doi.org/10.1007/s11682-019-00114-7>.
- Douw, L., Baayen, H., Bosma, I., Klein, M., Vandertop, P., Heimans, J., Stam, K., de Munck, J., Reijneveld, J., 2008. Treatment-related changes in functional connectivity in brain tumor patients: A magnetoencephalography study. *Experimental Neurology* 212 (2), 285–290. <https://doi.org/10.1016/j.expneurol.2008.03.013>.

- Duffau, H., 2001. Acute functional reorganisation of the human motor cortex during resection of central lesions: A study using intraoperative brain mapping. *Journal of Neurology, Neurosurgery & Psychiatry* 70 (4), 506–513. <https://doi.org/10.1136/jnnp.70.4.506>.
- Duffau, H., 2005. Lessons from brain mapping in surgery for low-grade glioma: Insights into associations between tumour and brain plasticity. *The Lancet Neurology* 4 (8), 476–486. [https://doi.org/10.1016/S1474-4422\(05\)70140-X](https://doi.org/10.1016/S1474-4422(05)70140-X).
- Duffau, H., 2006. Brain plasticity: From pathophysiological mechanisms to therapeutic applications. *Journal of Clinical Neuroscience* 13 (9), 885–897. <https://doi.org/10.1016/j.jocn.2005.11.045>.
- Duffau, H., 2008. Brain plasticity and tumors. In: *Advances and Technical Standards in Neurosurgery*. Springer, pp. 3–33. [https://doi.org/10.1007/978-3-211-72283-1\\_1](https://doi.org/10.1007/978-3-211-72283-1_1).
- Duffau, H., 2009a. Does post-lesional subcortical plasticity exist in the human brain? *Neuroscience Research* 65 (2), 131–135. <https://doi.org/10.1016/j.neures.2009.07.002>.
- Duffau, H., 2009b. Surgery of low-grade gliomas: Towards a 'functional neurooncology'. *Current Opinion in Oncology* 21 (6), 543–549. <https://doi.org/10.1097/CCO.0b013e3283305996>.
- Duffau, H., 2014. Diffuse low-grade gliomas and neuroplasticity. *Diagnostic and Interventional Imaging* 95 (10), 945–955. <https://doi.org/10.1016/j.diii.2014.08.001>.
- Duffau, H., 2020. Functional Mapping before and after Low-Grade Glioma Surgery: A New Way to Decipher Various Spatiotemporal Patterns of Individual Neuroplastic Potential in Brain Tumor Patients. *Cancers* 12 (9), 2611. <https://doi.org/10.3390/cancers12092611>.
- Duffau, H., Bauchet, L., Lehericy, S., Capelle, L., 2001a. Functional compensation of the left dominant insula for language. *Neuroreport* 12 (10), 2159–2163. <https://doi.org/10.1097/00001756-200107200-00023>.
- Duffau, H., Capelle, L., 2004. Preferential brain locations of low-grade gliomas: Comparison with glioblastomas and review of hypothesis. *Cancer* 100 (12), 2622–2626. <https://doi.org/10.1002/cncr.20297>.
- Duffau, H., Lopes, M., Denvil, D., Capelle, L., 2001b. Delayed onset of the supplementary motor area syndrome after surgical resection of the mesial frontal lobe: a time course study using intraoperative mapping in an awake patient. *Stereotactic and functional neurosurgery* 76 (2), 74–82. <https://doi.org/10.1159/000056496>.
- Duffau, H., Denvil, D., Capelle, L., 2002. Long term reshaping of language, sensory, and motor maps after glioma resection: a new parameter to integrate in the surgical strategy. *Journal of Neurology, Neurosurgery & Psychiatry* 72 (4), 511–516. <https://doi.org/10.1136/jnnp.72.4.511>.
- Duffau, H., Capelle, L., Denvil, D., Sichez, N., Gatignol, P., Lopes, M., M-C., Sichez, J-P. & Van Effenterre, R., 2003. Functional recovery after surgical resection of low grade gliomas in eloquent brain: Hypothesis of brain compensation. *Journal of Neurology, Neurosurgery & Psychiatry* 74 (7), 901–907. <https://doi.org/10.1136/jnnp.74.7.901>.
- Duffau, H., Moritz-Gasser, S., Gatignol, P., 2009. Functional outcome after language mapping for insular World Health Organization Grade II gliomas in the dominant hemisphere: Experience with 24 patients. *Neurosurgical Focus* 27 (2), E7. <https://doi.org/10.3171/2009.5.FOCUS938>.
- Duffau, H., Taillandier, L., 2015. New concepts in the management of diffuse low-grade glioma: proposal of a multistage and individualized therapeutic approach. *Neuro-Oncology* 17 (3), 332–342. <https://doi.org/10.1093/neuonc/nou153>.
- Duffau, H., Taillandier, L., Gatignol, P., Capelle, L., 2006. The insular lobe and brain plasticity: Lessons from tumor surgery. *Clinical Neurology and Neurosurgery* 108 (6), 543–548. <https://doi.org/10.1016/j.clineuro.2005.09.004>.
- Friederici, A.D., 2012. The cortical language circuit: From auditory perception to sentence comprehension. *Trends in Cognitive Sciences* 16 (5), 262–268. <https://doi.org/10.1016/j.tics.2012.04.001>.
- Friederici, A.D., Bahlmann, J., Heim, S., Schubotz, R.I., Anwander, A., 2006. The brain differentiates human and non-human grammars: functional localization and structural connectivity. *Proceedings of the National Academy of Sciences* 103 (7), 2458–2463. <https://doi.org/10.1073/pnas.0509389103>.
- Fuchs, E., Flügge, G., 2014. Adult Neuroplasticity: More Than 40 Years of Research. *Neural Plasticity* 2014, 1–10. <https://doi.org/10.1155/2014/541870>.
- Gębska-Kośla, K., Bryszewski, B., Jaskólski, D.J., Fortuniak, J., Niewodniczy, M., Stefańczyk, L., Majos, A., 2017. Reorganization of language centers in patients with brain tumors located in eloquent speech areas – A pre- and postoperative preliminary fMRI study. *Neurologia i Neurochirurgia Polska* 51 (5), 403–410. <https://doi.org/10.1016/j.pjnns.2017.07.010>.
- Geranmayeh, F., Brownsett, S.L.E., Wise, R.J.S., 2014a. Task-induced brain activity in aphasic stroke patients: What is driving recovery? *Brain* 137 (10), 2632–2648. <https://doi.org/10.1093/brain/awu163>.
- Geranmayeh, F., Wise, R.J.S., Mehta, A., Leech, R., 2014b. Overlapping Networks Engaged during Spoken Language Production and Its Cognitive Control. *Journal of Neuroscience* 34 (26), 8728–8740. <https://doi.org/10.1523/JNEUROSCI.0428-14.2014>.
- Ghinda, C.D., Duffau, H., 2017. Network Plasticity and Intraoperative Mapping for Personalized Multimodal Management of Diffuse Low-Grade Gliomas. *Frontiers in Surgery* 4, 3. <https://doi.org/10.3389/fsurg.2017.00003>.
- Gibson, E.M., Nagaraja, S., Ocampo, A., Tam, L.T., Wood, L.S., Pallegar, P.N., Greene, J. J., Geraghty, A.C., Goldstein, A.K., Ni, L., Woo, P.J., Barres, B.A., Liddelow, S., Vogel, H., Monje, M., 2019. Methotrexate Chemotherapy Induces Persistent Tri-gliial Dysregulation that Underlies Chemotherapy-Related Cognitive Impairment. *Cell* 176 (1–2), 43–55.e13. <https://doi.org/10.1016/j.cell.2018.10.049>.
- Gil-Robles, S., Gatignol, P., Lehericy, S., Duffau, H., 2008. Long-term brain plasticity allowing a multistage surgical approach to World Health Organization Grade II gliomas in eloquent areas. *Journal of Neurosurgery* 109 (4), 615–624. <https://doi.org/10.3171/JNS/2008/109/10/0615>.
- Gohel, X.S., Laino, X.M.E., Rajeev-Kumar, X.G., Jenabi, X.M., Peck, X.K., Hatzoglou, X.V., Tabar, X.V., Holodny, X.A.I., Vachha, X.B., 2019. Resting-State Functional Connectivity of the Middle Frontal Gyrus Can Predict Language Lateralization in Patients with Brain Tumors. *American Journal of Neuroradiology* 40 (2), 319–325. <https://doi.org/10.3174/ajnr.A5932>.
- Grummich, P., Nimsky, C., Fahlbusch, R., Ganslandt, O., 2005. Observation of unaveraged giant MEG activity from language areas during speech tasks in patients harboring brain lesions very close to essential language areas: Expression of brain plasticity in language processing networks? *Neuroscience Letters* 380 (1–2), 143–148. <https://doi.org/10.1016/j.neulet.2005.01.045>.
- Gunal, V., Savardekar, A., Devi, B.I., Bharath, R., 2018. Preoperative functional magnetic resonance imaging in patients undergoing surgery for tumors around left (dominant) inferior frontal gyrus region. *Surgical Neurology International* 9 (1), 126. [https://doi.org/10.4103/sni.sni\\_414\\_17](https://doi.org/10.4103/sni.sni_414_17).
- Hamilton, R.H., Chrysikou, E.G., Coslett, B., 2011. Mechanisms of aphasia recovery after stroke and the role of noninvasive brain stimulation. *Brain and Language* 118 (1–2), 40–50. <https://doi.org/10.1016/j.bandl.2011.02.005>.
- Hartwigsen, G., Saur, D., 2019. Neuroimaging of stroke recovery from aphasia – Insights into plasticity of the human language network. *NeuroImage* 190, 14–31. <https://doi.org/10.1016/j.neuroimage.2017.11.056>.
- Herbet, G., Maheu, M., Costi, E., Lafargue, G., Duffau, H., 2016. Mapping neuroplastic potential in brain-damaged patients. *Brain* 139 (3), 829–844. <https://doi.org/10.1093/brain/awv394>.
- Herbet, G., Moritz-Gasser, S., Lemaitre, A.-L., Almirac, F., Duffau, H., 2018. Functional compensation of the left inferior longitudinal fasciculus for picture naming. *Cognitive Neuropsychology* 36 (3–4), 140–157. <https://doi.org/10.1080/02643294.2018.1477749>.
- Hickok, G., Poeppel, D., 2007. The cortical organization of speech processing. *Nature Reviews Neuroscience* 8 (5), 393–402. <https://doi.org/10.1038/nrn2113>.
- Hillis, A.E., Heidler, J., 2002. Mechanisms of early aphasia recovery. *Aphasiology* 16 (9), 885–895. <https://doi.org/10.1080/0268703>.
- Holodny, A.I., Schuder, M., Ybasco, A., Liu, W.-C., 2002. Translocation of Broca's Area to the Contralateral Hemisphere as the Result of the Growth of a Left Inferior Frontal Glioma. *Journal of Computer Assisted Tomography* 26 (6), 941–943. <https://doi.org/10.1097/00004728-200211000-00014>.
- Ille, S., Engel, L., Albers, L., Schroeder, A., Kelm, A., Meyer, B., Krieg, S.M., 2019. Functional Reorganization of Cortical Language Function in Glioma Patients—A Preliminary Study. *Frontiers in Oncology* 9, 446. <https://doi.org/10.3389/fonc.2019.00446>.
- Ilmberger, J., Ruge, M., Kreth, F.-W., Briegel, J., Reulen, H.-J., Tonn, J.-C., 2008. Intraoperative mapping of language functions: A longitudinal neurolinguistic analysis: Clinical article. *Journal of Neurosurgery* 109 (4), 583–592. <https://doi.org/10.3171/JNS/2008/109/10/0583>.
- Ius, T., Angelini, E., Thiebaut de Schotten, M., Mandonnet, E., Duffau, H., 2011. Evidence for potentials and limitations of brain plasticity using an atlas of functional resectability of WHO grade II gliomas: Towards a “minimal common brain”. *NeuroImage* 56 (3), 992–1000. <https://doi.org/10.1016/j.neuroimage.2011.03.022>.
- Jehna, M., Becker, J., Zaar, K., von Campe, G., Mahdy Ali, K., Reishofer, G., Payer, F., Synowitz, M., Fazekas, F., Enzinger, C., Deutschmann, H., 2017. Symmetry of the arcuate fasciculus and its impact on language performance of patients with brain tumors in the language-dominant hemisphere. *Journal of Neurosurgery* 127 (6), 1407–1416. <https://doi.org/10.3171/2016.9.JNS161281>.
- Jin, L., Li, C., Zhang, Y., Yuan, T., Ying, J., Zuo, Z., Gui, S., 2021. The Functional Reorganization of Language Network Modules in Glioma Patients: New Insights From Resting State fMRI Study. *Frontiers in Oncology* 11, 617179. <https://doi.org/10.3389/fonc.2021.617179>.
- Kawashima, A., Krieg, S.M., Faust, K., Schneider, H., Vajkoczy, P., Picht, T., 2013. Plastic reshaping of cortical language areas in patients evaluated by navigated transcranial magnetic stimulation in a surgical case of glioblastoma multiforme. *Clinical Neurology and Neurosurgery* 115 (10), 2226–2229. <https://doi.org/10.1016/j.clineuro.2013.07.012>.
- Kinoshita, M., Nakada, M., Okita, H., Hamada, J.-I., Hayashi, Y., 2014. Predictive value of fractional anisotropy of the arcuate fasciculus for the functional recovery of language after brain tumor resection: A preliminary study. *Clinical Neurology and Neurosurgery* 117, 45–50. <https://doi.org/10.1016/j.clineuro.2013.12.002>.
- Kong, N.W., Gibb, W.R., Tate, M.C., 2016. Neuroplasticity: Insights from Patients Harboring Gliomas. *Neural Plasticity* 2016, 1–12. <https://doi.org/10.1155/2016/2365063>.
- Kośla, K., Bryszewski, B., Jaskólski, D., Blasiak-Polacińska, N., Stefańczyk, L., Majos, A., 2015. Reorganization of language areas in patient with a frontal lobe low grade glioma—fMRI case study. *Polish Journal of Radiology* 80, 290–295. <https://doi.org/10.12659/PJR.893897>.
- Kośla, K., Pfajfer, L., Bryszewski, B., Jaskólski, D., Stefańczyk, L., & Majos, A. (2012). Functional rearrangement of language areas in patients with tumors of the central nervous system using functional magnetic resonance imaging. 7.
- Krieg, S.M., Sollmann, N., Hauck, T., Ille, S., Foerschler, A., Meyer, B., Ringel, F., 2013. Functional Language Shift to the Right Hemisphere in Patients with Language-Eloquent Brain Tumors. *PLoS ONE* 8 (9), e75403. <https://doi.org/10.1371/journal.pone.0075403>.
- Krishna, S., Kakaizada, S., Almeida, N., Brang, D., Hervey-Jumper, S., 2021. Central Nervous System Plasticity Influences Language and Cognitive Recovery in Adult Glioma. *Neurosurgery* 89 (4), 539–548. <https://doi.org/10.1093/neuros/nyaa456>.
- Latini, F., Axelson, H., Fahlström, M., Jemstedt, M., Alberius Munkhammar, Å., Zetterling, M., Ryttefors, M., 2021. Role of Preoperative Assessment in Predicting

- Tumor-Induced Plasticity in Patients with Diffuse Gliomas. *Journal of Clinical Medicine* 10 (5), 1108. <https://doi.org/10.3390/jcm10051108>.
- Lazar, R.M., Marshall, R.S., Pile-Spellman, J., Duong, H.C., Mohr, J.P., Young, W.L., Solomon, R.L., Perera, G.M., DeLaPaz, R.L., 2000. Interhemispheric transfer of language in patients with left frontal cerebral arteriovenous malformation. *Neuropsychologia* 38 (10), 1325–1332. [https://doi.org/10.1016/S0028-3932\(00\)00054-3](https://doi.org/10.1016/S0028-3932(00)00054-3).
- Lee, A.T., Faltermeier, C., Morshed, R.A., Young, J.S., Kakaizada, S., Valdivia, C., Findlay, A.M., Tarapore, P.E., Nagarajan, S.S., Hervey-Jumper, S.L., Berger, M.S., 2021. The impact of high functional connectivity network hub resection on language task performance in adult low- and high-grade glioma. *Journal of Neurosurgery* 134 (4), 1102–1112. <https://doi.org/10.3171/2020.1.JNS192267>.
- Li, Q., Dong, J.W., Del Ferraro, G., Petrovich Brennan, N., Peck, K.K., Tabar, V., Makse, H.A., Holodny, A.I., 2019. Functional Translocation of Broca's Area in a Low-Grade Left Frontal Glioma: Graph Theory Reveals the Novel. *Adaptive Network Connectivity. Frontiers in Neurology* 10, 702. <https://doi.org/10.3389/fneur.2019.00702>.
- Lizarazu, M., Gil-Robles, S., Pomposo, I., Nara, S., Amoroso, L., Quiñones, I., Carreiras, M., 2020. Spatiotemporal dynamics of postoperative functional plasticity in patients with brain tumors in language areas. *Brain and Language* 202, 104741. <https://doi.org/10.1016/j.bandl.2019.104741>.
- Lubrano, V., Draper, L., Roux, F.-E., 2010. What Makes Surgical Tumor Resection Feasible in Broca's Area? Insights Into Intraoperative Brain Mapping. *Neurosurgery* 66 (5), 868–875. <https://doi.org/10.1227/01.NEU.0000368442.92290.04>.
- Mandonnet, E., Delattre, J.-Y., Tanguy, M.-L., Swanson, K.R., Carpentier, A.F., Duffau, H., Cornu, P., Van Effenterre, R., Alvard, E.C., Capelle, L., 2003. Continuous growth of mean tumor diameter in a subset of grade II gliomas. *Annals of Neurology* 53 (4), 524–528. <https://doi.org/10.1002/ana.10528>.
- Martino, J., Taillandier, L., Moritz-Gasser, S., Gatignol, P., Duffau, H., 2009. Reoperation is a safe and effective therapeutic strategy in recurrent WHO grade II gliomas within eloquent areas. *Acta Neurochirurgica* 151 (5), 427–436. <https://doi.org/10.1007/s00701-009-0232-6>.
- Meyer, P.T., Sturz, L., Schreckenberger, M., Spetzger, U., Meyer, G.F., Setani, K.S., Sabri, O., Buell, U., 2003. Preoperative mapping of cortical language areas in adult brain tumour patients using PET and individual non-normalised SPM analyses. *European Journal of Nuclear Medicine and Molecular Imaging* 30 (7), 951–960. <https://doi.org/10.1007/s00259-003-1186-1>.
- Meyers, C.A., Hess, K.R., Yung, W.K.A., Levin, V.A., 2000. Cognitive Function as a Predictor of Survival in Patients With Recurrent Malignant Glioma. *Journal of Clinical Oncology* 18 (3), 646. <https://doi.org/10.1200/JCO.2000.18.3.646>.
- Moher, D., Liberati, A., Tetzlaff, J., Altman, D.G., PRISMA Group\*, 2009. Preferred reporting items for systematic reviews and meta-analyses: the PRISMA statement. *Annals of internal medicine* 151 (4), 264–269. <https://doi.org/10.7326/0003-4819-151-4-200908180-00135>.
- Moher, D., Shamseer, L., Clarke, M., Ghersi, D., Liberati, A., Petticrew, M., Shekelle, P., Stewart, L.A., 2015. Preferred reporting items for systematic review and meta-analysis protocols (PRISMA-P) 2015 statement. *Systematic Reviews* 4 (1), 1–9. <https://doi.org/10.1186/2046-4053-4-1>.
- Nadkarni, T.N., Andreoli, M.J., Nair, V.A., Yin, P., Young, B.M., Kundu, B., Pankratz, J., Radtke, A., Holdsworth, R., Kuo, J.S., Field, A.S., Baskaya, M.K., Moritz, C.H., Meyerand, M.E., Prabhakar, V., 2015. Usage of fMRI for pre-surgical planning in brain tumor and vascular lesion patients: Task and statistical threshold effects on language lateralization. *NeuroImage: Clinical* 7, 415–423. <https://doi.org/10.1016/j.nicl.2014.12.014>.
- Noll, K.R., Sullaway, C., Ziu, M., Weinberg, J.S., Wefel, J.S., 2015. Relationships between tumor grade and neurocognitive functioning in patients with glioma of the left temporal lobe prior to surgical resection. *Neuro-Oncology* 17 (4), 580–587. <https://doi.org/10.1093/neuonc/nou233>.
- Noonan, K.A., Jefferies, E., Visser, M., Lambon Ralph, M.A., 2013. Going beyond Inferior Prefrontal Involvement in Semantic Control: Evidence for the Additional Contribution of Dorsal Angular Gyrus and Posterior Middle Temporal Cortex. *Journal of Cognitive Neuroscience* 25 (11), 1824–1850. [https://doi.org/10.1162/jocn\\_a.00442](https://doi.org/10.1162/jocn_a.00442).
- Ojemann, J.G., John, W., M., & Daniel L., S., 1996. Preserved Function in Brain Invaded by Tumor. *Neurosurgery* 39 (2), 253–259. <https://doi.org/10.1097/00006123-199608000-00003>.
- Page, M.J., McKenzie, J.E., Bossuyt, P.M., Boutron, I., Hoffmann, T.C., Mulrow, C.D., Moher, D., 2021. The PRISMA 2020 statement: an updated guideline for reporting systematic reviews. *Systematic reviews* 10 (1), 1–11. <https://doi.org/10.1136/bmj.n71>.
- Pallud, J., Capelle, L., Taillandier, L., Badoual, M., Duffau, H., Mandonnet, E., 2013. The silent phase of diffuse low-grade gliomas. Is it when we missed the action? *Acta Neurochirurgica* 155 (12), 2237–2242. <https://doi.org/10.1007/s00701-013-1886-7>.
- Papagno, C., Gallucci, M., Casarotti, A., Castellano, A., Falini, A., Fava, E., Giussani, C., Carrabba, G., Bello, L., Caramazza, A., 2011. Connectivity constraints on cortical reorganization of neural circuits involved in object naming. *NeuroImage* 55 (3), 1306–1313. <https://doi.org/10.1016/j.neuroimage.2011.01.005>.
- Papagno, C., Casarotti, A., Comi, A., Pisoni, A., Lucchelli, F., Bizzi, A., Riva, M., Bello, L., 2014. Long-term proper name anomia after removal of the uncinate fasciculus. *Brain Structure and Function* 221 (1), 687–694. <https://doi.org/10.1007/s00429-014-0920-8>.
- Partovi, S., Jacobi, B., Rapps, N., Zipp, L., Karimi, S., Rengier, F., Lyo, J.K., Stippich, C., 2012. Clinical Standardized fMRI Reveals Altered Language Lateralization in Patients with Brain Tumor. *American Journal of Neuroradiology* 33 (11), 2151–2157. <https://doi.org/10.3174/ajnr.A3137>.
- Pasquini, L., Di Napoli, A., Rossi-Espagnet, M.C., Visconti, E., Napolitano, A., Romano, A., Bozzao, A., Peck, K.K., Holodny, A.I., 2022. Understanding Language Reorganization With Neuroimaging: How Language Adapts to Different Focal Lesions and Insights Into Clinical Applications. *Frontiers in Human Neuroscience* 16, 747215. <https://doi.org/10.3389/fnhum.2022.747215>.
- Pedersen, P.M., Vinter, K., Olsen, T.S., 2004. Aphasia after Stroke: Type, Severity and Prognosis. *Cerebrovascular Diseases* 17 (1), 35–43. <https://doi.org/10.1159/000073896>.
- Petersen, S.E., Fox, P.T., Posner, M.I., Mintun, M., Raichle, M.E., 1988. Positron emission tomographic studies of the cortical anatomy of single-word processing. *Nature* 331, 585–589.
- Petrovich, N.M., Holodny, A.I., Brennan, C.W., Gutin, P.H., 2004. Isolated translocation of Wernicke's area to the right hemisphere in a 62-year-old man with a temporo-parietal glioma. *American journal of neuroradiology* 25 (1), 130–133.
- Pial, V., De Witte, E., Sierpowska, J., Knight, R.T., Berger, M.S., 2019. Language neuroplasticity in brain tumour patients revealed by magnetoencephalography [Preprint]. <https://doi.org/10.31234/osf.io/1qkxg>.
- Picart, T., Herbet, G., Moritz-Gasser, S., Duffau, H., 2019. Iterative Surgical Resections of Diffuse Glioma With Awake Mapping: How to Deal With Cortical Plasticity and Connectome Constraints? *Neurosurgery* 85 (1), 105–116. <https://doi.org/10.1093/neuros/nyy218>.
- Pillai, J.J., 2010. Insights into Adult Postlesional Language Cortical Plasticity Provided by Cerebral Blood Oxygen Level-Dependent Functional MR Imaging. *American Journal of Neuroradiology* 31 (6), 990–996. <https://doi.org/10.3174/ajnr.A1896>.
- Plaza, M., Gatignol, P., Leroy, M., Duffau, H., 2009. Speaking without Broca's area after tumor resection. *Neurocase* 15 (4), 294–310. <https://doi.org/10.1080/13554790902729473>.
- Połyńska, M.M., Beck, L., Kuhn, T., Benjamin, C.F., Ly, T.K., Japardi, K., Cavanagh, L., Bookheimer, S.Y., 2021. Tumor location and reduction in functional MRI estimates of language laterality. *Journal of Neurosurgery* 1–11. <https://doi.org/10.3171/2020.9.JNS202036>.
- Price, C.J., 2000. The anatomy of language: Contributions from functional neuroimaging. *Journal of Anatomy* 197 (3), 335–359. <https://doi.org/10.1046/j.1469-7580.2000.19730335.x>.
- Pulvermüller, F., Neininger, B., Elbert, T., Mohr, B., Rockstroh, B., Koebbel, P., & Taub, E. (2001). Constraint-Induced Therapy of Chronic Aphasia After Stroke. *Stroke*, 32 (7), 1621–1626. <https://doi.org/10.1161/01.STR.32.7.1621>.
- Rauschecker, J. P., & Scott, S. K. (2009). Maps and streams in the auditory cortex: Nonhuman primates illuminate human speech processing. *Nature Neuroscience*, 12 (6), 718–724. <https://doi.org/10.1038/nn.2331>.
- Rolston, J.D., Chang, E.F., 2018. Critical Language Areas Show Increased Functional Connectivity in Human Cortex. *Cerebral Cortex* 28 (12), 4161–4168. <https://doi.org/10.1093/cercor/bhx271>.
- Rosenberg, K., Liebling, R., Avidan, G., Perry, D., Siman-Tov, T., Andelman, F., Ram, Z., Fried, I., Hendler, T., 2008. Language related reorganization in adult brain with slow growing glioma: fMRI prospective case-study. *Neurocase* 14 (6), 465–473. <https://doi.org/10.1080/13554790802459486>.
- Rösler, J., Niraula, B., Strack, V., Zdzunczyk, A., Schilt, S., Savolainen, P., Lioumis, P., Mäkelä, J., Vajkoczy, P., Frey, D., Picht, T., 2014. Language mapping in healthy volunteers and brain tumor patients with a novel navigated TMS system: Evidence of tumor-induced plasticity. *Clinical Neurophysiology* 125 (3), 526–536. <https://doi.org/10.1016/j.clinph.2013.08.015>.
- Saito, T., Muragaki, Y., Miura, I., Tamura, M., Maruyama, T., Nitta, M., Kurisu, K., Iseki, H., Okada, Y., 2014. Functional Plasticity of Language Confirmed with Intraoperative Electrical Stimulations and Updated Neuronavigation: Case Report of Low-Grade Glioma of the Left Inferior Frontal Gyrus. *Neurologia Medico-Chirurgica* 54 (7), 587–592. <https://doi.org/10.2176/nmc.c.2013-0248>.
- Sanai, N., Mirzadeh, Z., Berger, M.S., 2008. Functional Outcome after Language Mapping for Glioma Resection. *New England Journal of Medicine* 358 (1), 18–27. <https://doi.org/10.1056/NEJMoa067819>.
- Sarubbo, S., Latini, F., Sette, E., Milani, P., Granieri, E., Fainardi, E., Cavallo, M.A., 2012a. Is the resection of gliomas in Wernicke's area reliable? Wernicke's area resection. *Acta Neurochirurgica* 154 (9), 1653–1662. <https://doi.org/10.1007/s00701-012-1416-z>.
- Sarubbo, S., Le Bars, E., Moritz-Gasser, S., Duffau, H., 2012b. Complete recovery after surgical resection of left Wernicke's area in awake patient: A brain stimulation and functional MRI study. *Neurosurgical Review* 35 (2), 287–292. <https://doi.org/10.1007/s10143-011-0351-4>.
- Sarubbo, S., De Benedictis, A., Merler, S., Mandonnet, E., Balbi, S., Granieri, E., Duffau, H., 2015. Towards a functional atlas of human white matter. *Human Brain Mapping* 36 (8), 3117–3136. <https://doi.org/10.1002/hbm.22832>.
- Satoer, D., Visch-Brink, E., Smits, M., Kloet, A., Looman, C., Dirven, C., Vincent, A., 2014. Long-term evaluation of cognition after glioma surgery in eloquent areas. *Journal of Neuro-Oncology* 116 (1), 153–160. <https://doi.org/10.1007/s11060-013-1275-3>.
- Satoer, D., De Witte, E., Smits, M., Bastiaanse, R., Vincent, A., Mariën, P., Visch-Brink, E., 2017. Differential Effects of Awake Glioma Surgery in "Critical" Language Areas on Cognition: 4 Case Studies. *Case Reports in Neurological Medicine* 2017, 1–10. <https://doi.org/10.1155/2017/6038641>.
- Saur, D., 2006. Dynamics of language reorganization after stroke. *Brain* 129 (6), 1371–1384. <https://doi.org/10.1093/brain/awl090>.
- Saur, D., & Hartwigsen, G. (2012). Funktionsanpassung im sprachlichen System. *In Kognitive Neurowissenschaften* (3. Auflage, S. 741–749). Springer.
- Saur, D., Kreher, B.W., Schnell, S., Kümmerer, D., Kellmeyer, P., Vry, M.-S., Umarova, R., Musso, M., Glauche, V., Abel, S., Huber, W., Rijntjes, M., Hennig, J., Weiller, C., 2008. Ventral and dorsal pathways for language. *Proceedings of the National*

- Academy of Sciences 105 (46), 18035–18040. <https://doi.org/10.1073/pnas.0805234105>.
- Sierpowska, J., León-Cabrera, P., Camins, A., Juncadella, M., Gabarrós, A., & Rodríguez-Fornells, A. (2020). The black box of global aphasia: Neuroanatomical underpinnings of remission from acute global aphasia with preserved inner language function. *Cortex*, 130, 340–350. <https://doi.org/10.1016/j.cortex.2020.06.009>.
- Sierpowska, J., Gabarrós, A., Fernandez-Coello, A., Camins, A., Castañer, S., Juncadella, M., de Diego-Balaguer, R., Rodríguez-Fornells, A., 2015. Morphological derivation overflow as a result of disruption of the left frontal aslant white matter tract. *Brain and Language* 142, 54–64. <https://doi.org/10.1016/j.bandl.2015.01.005>.
- Skirboll, S., Ojemann, G., Berger, M., Lettich, E., Winn, H., 1996. Functional Cortex and Subcortical White Matter Located within Gliomas. *Neurosurgery* 38 (4), 678–685.
- Smits, A., Zetterling, M., Lundin, M., Melin, B., Fahlström, M., Grabowska, A., Larsson, E.-M., Berntsson, S.G., 2015. Neurological Impairment Linked with Cortico-Subcortical Infiltration of Diffuse Low-Grade Gliomas at Initial Diagnosis Supports Early Brain Plasticity. *Frontiers in Neurology* 6, 137. <https://doi.org/10.3389/fneur.2015.00137>.
- Sollmann, N., Negwer, C., Tussis, L., Hauck, T., Ille, S., Maurer, S., Giglhuber, K., Bauer, J.S., Ringel, F., Meyer, B., Krieg, S.M., 2017. Interhemispheric connectivity revealed by diffusion tensor imaging fiber tracking derived from navigated transcranial magnetic stimulation maps as a sign of language function at risk in patients with brain tumors. *Journal of Neurosurgery* 126 (1), 222–233. <https://doi.org/10.3171/2016.1.JNS152053>.
- Southwell, D.G., Hervey-Jumper, S.L., Perry, D.W., Berger, M.S., 2016. Intraoperative mapping during repeat awake craniotomy reveals the functional plasticity of adult cortex. *Journal of Neurosurgery* 124 (5), 1460–1469. <https://doi.org/10.3171/2015.5.JNS142833>.
- Spena, G., Costi, E., Panciani, P.P., Roca, E., Migliorati, K., Fontanella, M.M., 2015. Acute functional reactivation of the language network during awake intraoperative brain mapping. *Neurocase* 21 (3), 403–407. <https://doi.org/10.1080/13554794.2014.910306>.
- Stockert, A., Kümmerer, D., Saur, D., 2016. Insights into early language recovery: From basic principles to practical applications. *Aphasiology* 30 (5), 517–541. <https://doi.org/10.1080/02687038.2015.1119796>.
- Stockert, A., Wawrzyniak, M., Klingbeil, J., Wrede, K., Kümmerer, D., Hartwigsen, G., Kaller, C.P., Weiller, C., Saur, D., 2020. Dynamics of language reorganization after left temporo-parietal and frontal stroke. *Brain* 143 (3), 844–861. <https://doi.org/10.1093/brain/awaa023>.
- Szafarski, J. P., Ball, A. L., Grether, S., Al-fwaress, F., Griffith, N. M., Neils-Strunjas, J., & Reichhardt, R. (2008). Constraint-induced aphasia therapy stimulates language recovery in patients with chronic aphasia after ischemic stroke. *Medical science monitor: international medical journal of experimental and clinical research*, 14(5), CR243.
- Szaliszno, K., Silverstein, D.N., Duffau, H., Smits, A., 2013. Pathological Neural Attractor Dynamics in Slowly Growing Gliomas Supports an Optimal Time Frame for White Matter Plasticity. *PLoS ONE* 8 (7), e69798. <https://doi.org/10.1371/journal.pone.0069798>.
- Tarapore, P.E., Martino, J., Guggisberg, A.G., Owen, J., Honma, S.M., Findlay, A., Berger, M.S., Kirsch, H.E., Nagarajan, S.S., 2012. Magnetoencephalographic Imaging of Resting-State Functional Connectivity Predicts Postsurgical Neurological Outcome in Brain Gliomas. *Neurosurgery* 71 (5), 1012–1022. <https://doi.org/10.1227/NEU.0b013e31826d2b78>.
- Thiel, A., Herholz, K., von Stockhausen, H.-M., van Leyen-Pilgram, K., Pietrzyk, U., Kessler, J., Wienhard, K., Klug, N., & Heiss, W.-D. (1998). Localization of Language-Related Cortex with 15O-Labeled Water PET in Patients with Gliomas. *NeuroImage*, 7 (4), 284–295. <https://doi.org/10.1006/nimg.1998.0334>.
- Thiel, A., Herholz, K., Koyuncu, A., Ghaemi, M., Kracht, L.W., Habedank, B., Heiss, W.-D., 2001. Plasticity of language networks in patients with brain tumors: A positron emission tomography activation study. *Annals of Neurology* 50 (5), 620–629. <https://doi.org/10.1002/ana.1253>.
- Thiel, A., Habedank, B., Winhuisen, L., Herholz, K., Kessler, J., Haupt, W.F., Heiss, W.-D., 2005. Essential language function of the right hemisphere in brain tumor patients. *Annals of Neurology* 57 (1), 128–131. <https://doi.org/10.1002/ana.20342>.
- Thiel, A., Habedank, B., Herholz, K., Kessler, J., Winhuisen, L., Haupt, W.F., Heiss, W.-D., 2006. From the left to the right: How the brain compensates progressive loss of language function. *Brain and Language* 98 (1), 57–65. <https://doi.org/10.1016/j.bandl.2006.01.007>.
- Tomasino, B., Marin, D., Maieron, M., D'Agostini, S., Medeossi, I., Fabbro, F., Skrap, M., Luzzatti, C., 2015. A multimodal mapping study of conduction aphasia with impaired repetition and spared reading aloud. *Neuropsychologia* 70, 214–226. <https://doi.org/10.1016/j.neuropsychologia.2015.02.023>.
- Tomasino, B., Tronchin, G., Marin, D., Maieron, M., Fabbro, F., Cubelli, R., Skrap, M., Luzzatti, C., 2019. Noun-verb naming dissociation in neurosurgical patients. *Aphasiology* 33 (12), 1418–1440. <https://doi.org/10.1080/02687038.2018.1542658>.
- Traut, T., Sardesh, N., Bulbas, L., Findlay, A., Honma, S.M., Mizuir, D., Berger, M.S., Hinkley, L.B., Nagarajan, S.S., Tarapore, P.E., 2019. MEG imaging of recurrent gliomas reveals functional plasticity of hemispheric language specialization. *Human Brain Mapping* 40 (4), 1082–1092. <https://doi.org/10.1002/hbm.24430>.
- Tuncer, M.S., Salvati, L.F., Grittner, U., Hardt, J., Schilling, R., Bährend, I., Silva, L.L., Fekonja, L.S., Faust, K., Vajkoczy, P., Rosenstock, T., Picht, T., 2021. Towards a tractography-based risk stratification model for language area associated gliomas. *NeuroImage: Clinical* 29, 102541. <https://doi.org/10.1016/j.nicl.2020.102541>.
- Turkeltaub, P.E., Messing, S., Norise, C., Hamilton, R.H., 2011. Are networks for residual language function and recovery consistent across aphasic patients? *Neurology* 76 (20), 1726–1734. <https://doi.org/10.1212/WNL.0b013e31821a44c1>.
- Turkeltaub, P.E., Coslett, H.B., Thomas, A.L., Faseyitan, O., Benson, J., Norise, C., Hamilton, R.H., 2012. The right hemisphere is not unitary in its role in aphasia recovery. *Cortex* 48 (9), 1179–1186. <https://doi.org/10.1016/j.cortex.2011.06.010>.
- Vajkoczy, P., Menger, M.D., 2004. Vascular microenvironment in gliomas. *Angiogenesis in Brain Tumors* 249–262.
- Van Dokkum, L.E.H., Moritz Gasser, S., Deverdun, J., Herbet, G., Mura, T., D'Agata, B., Picot, M.C., Menjot de Champfleury, N., Duffau, H., Molino, F., le Bars, E., 2019. Resting state network plasticity related to picture naming in low-grade glioma patients before and after resection. *NeuroImage: Clinical* 24, 102010. <https://doi.org/10.1016/j.nicl.2019.102010>.
- Van Geemen, K., Herbet, G., Moritz-Gasser, S., Duffau, H., 2014. Limited plastic potential of the left ventral premotor cortex in speech articulation: Evidence from intraoperative awake mapping in glioma patients: Ventral Premotor Cortex and Speech. *Human Brain Mapping* 35 (4), 1587–1596. <https://doi.org/10.1002/hbm.22275>.
- Voets, N.L., Jones, O.P., Mars, R.B., Adcock, J.E., Stacey, R., Apostolopoulos, V., Plaha, P., 2019. Characterising neural plasticity at the single patient level using connectivity fingerprints. *NeuroImage: Clinical* 24, 101952. <https://doi.org/10.1016/j.nicl.2019.101952>.
- Voets, N.L., Jones, O.P., Isaac, C., Mars, R.B., Plaha, P., 2021. Tracking longitudinal language network reorganisation using functional MRI connectivity fingerprints. *NeuroImage: Clinical* 30, 102689. <https://doi.org/10.1016/j.nicl.2021.102689>.
- Wang, L., Chen, D., Yang, X., Olson, J.J., Gopinath, K., Fan, T., Mao, H., 2013. Group Independent Component Analysis and Functional MRI Examination of Changes in Language Areas Associated with Brain Tumors at Different Locations. *PLoS ONE* 8 (3), e59657. <https://doi.org/10.1371/journal.pone.0059657>.
- Wang, Z., Fekonja, L., Dreyer, F., Vajkoczy, P., & Picht, T. (2020). Transcranial magnetic stimulation language mapping analysis revisited: Machine learning classification of 90 patients reveals distinct reorganization pattern in aphasic patients [Preprint]. <https://doi.org/10.1101/2020.02.06.20020693>.
- Wang, S., Young, K.M., 2014. White matter plasticity in adulthood. *Neuroscience* 276, 148–160. <https://doi.org/10.1016/j.neuroscience.2013.10.018>.
- Wise, R.J.S., 2003. Language systems in normal and aphasic human subjects: Functional imaging studies and inferences from animal studies. *British Medical Bulletin* 65 (1), 95–119. <https://doi.org/10.1093/bmb/65.1.95>.
- Witwer, B.P., Mofakhar, R., Hasan, K.M., Deshmukh, P., Haughton, V., Field, A., Arfanakis, K., Noyes, J., Moritz, C.H., Meyerand, M.E., Rowley, H.A., Alexander, A. L., Badie, B., 2002. Diffusion-tensor imaging of white matter tracts in patients with cerebral neoplasm. *Journal of Neurosurgery* 97 (3), 568–575. <https://doi.org/10.3171/jns.2002.97.3.0568>.
- Wood, J.M., Kundu, B., Utter, A., Gallagher, T.A., Voss, J., Nair, V.A., Kuo, J.S., Field, A. S., Moritz, C.H., Meyerand, M.E., Prabhakaran, V., 2011. Impact of Brain Tumor Location on Morbidity and Mortality: A Retrospective Functional MR Imaging Study. *American Journal of Neuroradiology* 32 (8), 1420–1425. <https://doi.org/10.3174/ajnr.A2679>.
- Wright, P., Stamatakis, E.A., Tyler, L.K., 2012. Differentiating Hemispheric Contributions to Syntax and Semantics in Patients with Left-Hemisphere Lesions. *Journal of Neuroscience* 32 (24), 8149–8157. <https://doi.org/10.1523/JNEUROSCI.0485-12.2012>.
- Wu, Chen-xing, W., Song, P., Yi, L., Yong-zhi, W., Tao, J., Jian, X., Miao, W., Xiao-li, Y., & Xiao-yi, W. (2008). Fractionated resection on low grade gliomas involving Broca's area and insights to brain plasticity. *Chinese medical journal*, 121(20), 2026–2030.
- Wunderlich, G., Knorr, U., Herzog, H., Kiwit, J.C.W., Freund, H.-J., Seitz, R.J., 1998. Precentral Glioma Location Determines the Displacement of Cortical Hand Representation. *Neurosurgery* 42 (1), 18–27. <https://doi.org/10.1097/00006123-199801000-00005>.
- Yuan, B., Zhang, N., Yan, J., Cheng, J., Lu, J., Wu, J., 2020. Tumor grade-related language and control network reorganization in patients with left cerebral glioma. *Cortex* 129, 141–157. <https://doi.org/10.1016/j.cortex.2020.04.015>.
- Zhang, N., Xia, M., Qiu, T., Wang, X., Lin, C., Guo, Q., Lu, J., Wu, Q., Zhuang, D., Yu, Z., Gong, F., Farrukh Hameed, N.U., He, Y., Wu, J., Zhou, L., 2018. Reorganization of cerebellar circuit in patients with left hemispheric gliomas involving language network: A combined structural and resting-state functional MRI study. *Human Brain Mapping* 39 (12), 4802–4819. <https://doi.org/10.1002/hbm.24324>.
- Zheng, G., Chen, X., Xu, B., Zhang, J., Lv, X., Li, J., Li, F., Zhang, T., Li, Y., 2013. Plasticity of language pathways in patients with low-grade glioma: A diffusion tensor imaging study. *Neural Regeneration Research* 8 (7), 647. <https://doi.org/10.3969/j.issn.1673-5374.2013.07.009>.
- Zimmermann, M., Rössler, K., Kaltenhäuser, M., Grummich, P., Yang, B., Buchfelder, M., Doerfler, A., Kölbl, K., Stadlbauer, A., 2020. Refined Functional Magnetic Resonance Imaging and Magnetoencephalography Mapping Reveals Reorganization in Language-Relevant Areas of Lesioned Brains. *World Neurosurgery* 136, e41–e59. <https://doi.org/10.1016/j.wneu.2019.10.014>.