



Methods for cerebellar imaging analysis

Nikos Priovoulos^{1,2,3,*} and Pierre-Louis Bazin^{4,5}

The human cerebellum consists of an extended, highly-folded, and laminated cortical sheet overlying the white matter and cerebellar nuclei. This complex anatomy hinders the processing of magnetic resonance imaging data, as the relevant structures are not fully resolved. In this review, we explore the typical processing techniques employed for the anatomical and functional imaging of the cerebellum, along with their primary limitations with respect to imaging fidelity. Moreover, we discuss emerging methods applicable postmortem and *in-vivo* that greatly enhance fidelity in cerebellar imaging through higher-resolution data and individual-level processing.

Addresses

¹ Spinoza Center for Neuroimaging, Amsterdam, the Netherlands

² Computational Cognitive Neuroscience and Neuroimaging, Netherlands Institute for Neuroscience, Amsterdam, the Netherlands

³ Amsterdam UMC, Biomedical Engineering and Physics, Amsterdam, the Netherlands

⁴ Integrative Model-Based Cognitive Neuroscience Research Unit, University of Amsterdam, Amsterdam, the Netherlands

⁵ Department of Neurophysics, Max Planck Institute for Human Cognitive and Brain Sciences, Leipzig, Germany

Corresponding author: Priovoulos, Nikos

(n.priovoulos@spinozacentre.nl),

* Twitter account: [@nikospriovoulos](https://twitter.com/nikospriovoulos)

Current Opinion in Behavioral Sciences 2023, 54:101328

This review comes from a themed issue on **Role of the Cerebellum in Cognition and Behavior**

Edited by **Sheeba.Arnold-Anteraper** and **Wietske van der Zwaag**

Available online xxxx

<https://doi.org/10.1016/j.cobeha.2023.101328>

2352–1546/© 2023 The Author(s). Published by Elsevier Ltd. This is an open access article under the CC BY license (<http://creativecommons.org/licenses/by/4.0/>)

Cerebellar imaging methods

The cerebellum consists of an extended, highly-folded, and laminated cortical sheet overlying the white matter which encapsulates the cerebellar nuclei. T1-weighted (T1w) magnetic resonance (MR) images, such as images produced from Magnetization Prepared (2) Rapid Gradient Echo (MP2RAGE) sequences can help visualize the cerebellar cortex and white matter [1] while individual cortical layers can be seen in the phase images of

T2* w sequences [2]. The iron-rich cerebellar nuclei, the main output of the cerebellar cortex, are frequently visualized with T2* w-contrast [3]. Standard MR imaging (MRI) tools, such as functional and diffusion MRI, can also be used to track its function and white-matter structure respectively.

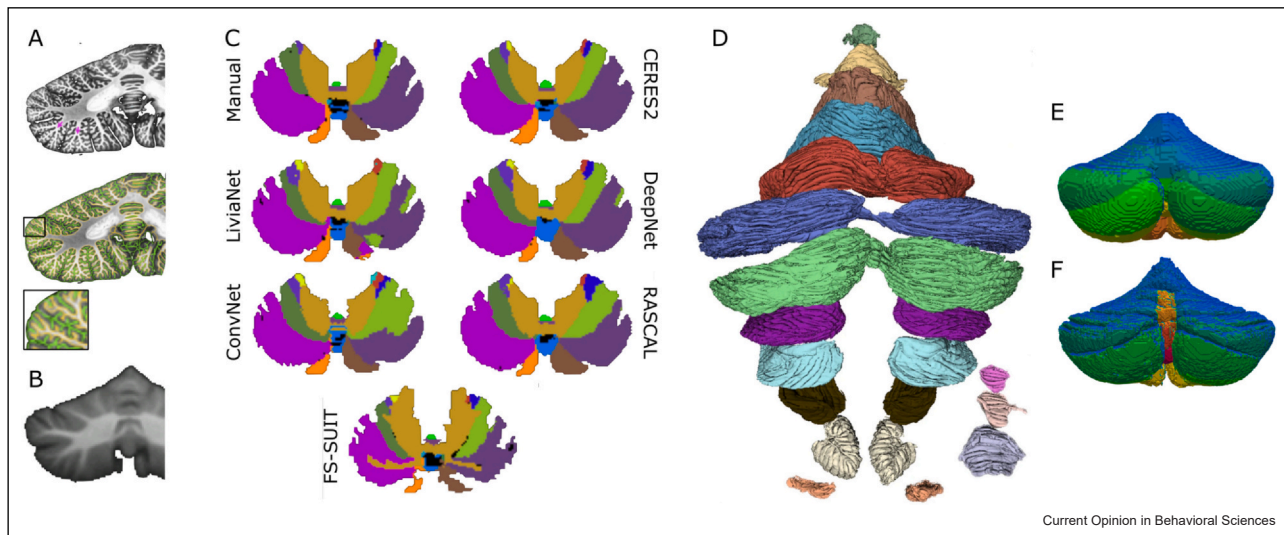
Challenges in human cerebellar imaging

Similar to the cerebrum, processing of MRI data requires image enhancement, the delineation of the relevant areas of interest, such as the gray and white matter, and potentially the application of additional transformations, such as group normalization or surface projection. These steps, however, are particularly challenging in the cerebellum, since the anatomy is typically not fully resolved, due to the small size of the relevant structures, that is the cerebellar nuclei and thin cortex (Figure 1a–b [4]). The resulting partial volume effects, as well as the tight foliation of the cerebellar cortex, hinder the separation of gray matter banks, particularly with segmentation pipelines that are optimized in the cerebrum. Cerebellar segmentation is further hindered by adjacent structures, such as the dura and sinuses, that, depending on the MRI sequence, may have a similar signal intensity to the cortex, while the fine cerebellar vasculature and cortical folding are characterized by similarly-high spatial frequencies which render edge-detection challenging. Furthermore, registration-based approaches, for example, to achieve segmentation or group homogenization are severely limited by the individual-dependent complex cerebellar foliation, which reduces registration accuracy beyond the main cerebellar lobules. The complex anatomy also hinders the creation of well-defined segmentations and surfaces (i.e. without holes/handles), while the inflation of these highly-curved surfaces results in large distortions [4]. All these are exacerbated by the relatively low signal-to-noise (SNR) and high signal inhomogeneity in the cerebellum with typical coil geometries, particularly in ultra-high-field MRI [5], as well as pulsatility artifacts close to the 4th ventricle. Finally, even if adequately high-resolution datasets are acquired, most neuroimaging packages struggle with the increased computational requirements since they are optimized for relatively low-resolution datasets [6]. The above challenges greatly hinder cerebellar research resulting in the cerebellum being relatively understudied *in-vivo*.

Image enhancement

Image enhancement techniques can help ameliorate some of these issues in structural images: intensity-bias correction is a common first step to homogenize the signal distribution [7]. Denoising approaches can

Figure 1



(a) High-resolution (0.2 mm) postmortem cerebellar MRI (coronal slice; top) and pial and white matter delineation (bottom). (b) Comparable slice from the SUIT atlas based on conventional MRI data (1 mm). Note that the fine fissure detail is not resolved. (c) Axial slices from cerebellar parcellations (manual delineation and automated parcellations) from conventional MRI data. The parcellations do not fully resolve the fine cerebellar anatomical detail. (d) High-resolution cerebellar parcellation projected on a post-mortem surface. (e) Surface projection of SUIT atlas cerebellar parcellation. (f) Surface projection of CHROMA atlas cerebellar parcellation. (a) (bottom; adapted with permission from [4]). (c) Adapted with permission from [10]. (d) adapted with permission from [11].

improve SNR of high-resolution data, for example by leveraging the redundancy of multi-dimensional MRI data. Such approaches may be particularly useful for the lower-SNR later echoes of multi-echo data used to visualize the cerebellar nuclei [8]. Super-resolution acquisition/reconstruction approaches can also help improve the SNR/resolution tradeoff in the cerebellum, as shown recently in diffusion data [9].

Tissue classification

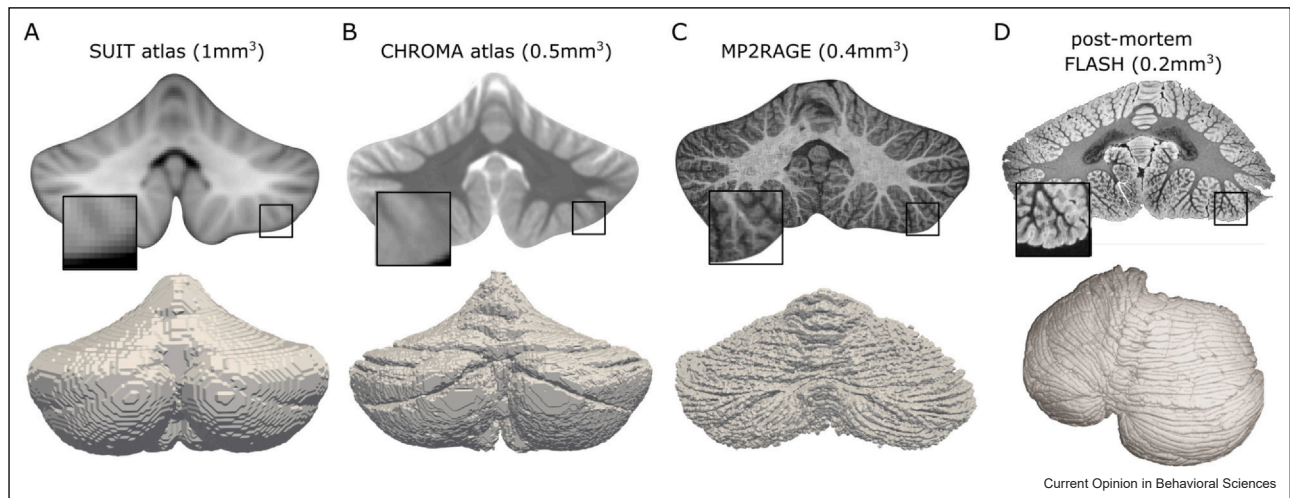
Tissue classification in the cerebellum is commonly performed through neuroimaging packages like the cerebellum-specific SUIT [12], CERES2 [13], and ACAPULCO [14], or the cerebrum-focused Freesurfer [15] (for a performance evaluation, see [10], Figure 1c). These packages rely on atlases or combined atlas and signal-intensity automated methods, thus segmenting the cerebellar lobules in a reproducible manner. Similar approaches exist for the cerebellar nuclei [3,12,16,17]. These methods therefore greatly facilitate the analysis of lower resolution data, such as from functional MRI (fMRI) or non-specialized cerebellar imaging approaches [12], however, they implicitly segment at a spatial scale that smooths over the fine anatomical detail, such as the individual cerebellar folia, or the dentate cortex. This is a pragmatic choice since the current *in-vivo* state-of-the-art MRI scans do not fully resolve the cerebellar anatomy and the computational demands increase quickly with finer sampling (Figure 1d–e).

These streamlined methods have therefore found widespread usage in human neuroscience, but produce cortical measures (e.g. cortical thickness) several factors off of the biological ground-truth [1,4]. Recently-released packages, such as the Nighres platform [18] and the submillimeter CHROMA atlas (Figure 1f, Figure 2a–b, [19,20]), may better approximate the cerebellar cortical surface with increasing image resolution. Cerebellar nuclei parcellation may also benefit from more elaborate shape-based methods at higher resolution, for example [21,22].

Individual-level segmentation

The limited resolving power compared to the fine cerebellar anatomy, stemming from acquisition and analysis limitations, has hindered even post-mortem research, with the large-scale cerebellar cortical features being less well-characterized compared to the cerebrum. Only recently the accurate reconstruction of the complete cerebellar cortical surface was achieved from post-mortem MRI [4] or 3D-reconstructed histology data [11]. Both of these studies used high-resolution data combined with signal-intensity-based methods and manual corrections to segment the cerebellar surface to the level of individual folia. They showed that the cerebellar cortical sheet has a similar surface area to the cerebral, though high variability remains in the thickness estimates of the granular and molecular layers across the cerebellum [11,23]. We recently showed that dedicated cerebellar

Figure 2



Cerebellar coronal slices (top) and corresponding cerebellar surfaces (bottom). (a) SUIT atlas (1 mm). (b) CHROMA atlas (0.5 mm). (c) individual MP2RAGE at 0.4 mm. Postmortem FLASH MRI at 0.2 mm. Higher-resolution and individual-level segmentations improve surface fidelity towards resolving the fine cerebellar cortical detail, such as fissures. FLASH, fast low angle shot; MP2RAGE, Magnetization Prepared (2) Rapid Gradient Echo; MRI, MR imaging. (c) (adapted with permission from [1]). (adapted with permission from [4]).

imaging at 7T combined with motion correction, denoising, and semi-automated intensity-based segmentation algorithms can closely approximate the cerebellar surface *in vivo*, though still lagging compared to these post-mortem datasets (Figure 2c–d, [1]). Acquisition and analysis improvements to streamline cerebellar segmentation *in-vivo* while retaining anatomical detail remains an important target for cerebellar imaging.

Functional MRI in the cerebellum

Functional MRI of the cerebellum has convincingly shown its importance across the cognitive domain [24–29]. Compared to fMRI in the cerebral cortex, cerebellar fMRI further suffers from increased susceptibility-inhomogeneities and physiological noise. With typical fMRI acquisition techniques and particularly at higher fields, this may require distortion correction and physiological noise removal techniques to be applied during preprocessing [30]. Depending on the B_0 inhomogeneity change throughout the acquisition, non-linear motion correction techniques may also be required. The projection of fMRI results to reference cerebellar atlases [12,31], and associated surface-based representations [12,32,33] has greatly facilitated functional cerebellar research in humans [26,34,35]. Recently, the combination of accurate structural reconstruction of the cerebellum and high-resolution fMRI has allowed the detailed examination of the functional activation of the cerebellar cortex [20], revealing a similar somatotopic organization to the

cerebral cortex. Note that the functional organization of the cerebellum is not limited to specific lobules [26]: electrophysiology animal studies indicate instead a finer patch and stripe-like organization [36]. Currently, the blood oxygen level dependent (BOLD) fMRI effective resolution limits have not allowed studying this finer functional organization in the cerebellum, but the recent advent of high-specificity fMRI techniques may allow this [37]. This may require adapting the cerebellar fMRI processing pipelines to facilitate examining more spatially-specific activation, similar, for example to layer-specific analysis in the cerebral cortex [32,38–40].

Conclusions

Overall, many of the image processing tools needed for detailed analysis of cerebellar structure and function are available, from denoising and super-resolution all the way to cortical mapping. The main challenge still resides in the cerebellar incredibly compact organization, which requires stretching the capabilities of MR imaging to the limit. However, these are rapidly changing, combining optimized acquisition techniques, multi-dimensional contrasts, and machine learning reconstruction to push the boundary of *in-vivo* MRI [1,41–43] while the latest efforts of post-mortem MRI and whole brain microscopy provide invaluable data sets to start scaling up analysis pipelines to account for individual folia and nuclei in the near future [4,11,23,44,45].

CRedit authorship contribution statement

Nikos Priovoulos: Conceptualization, Writing – original draft. **Pierre-Louis Bazin:** Conceptualization, Supervision, Writing – review & editing.

Data Availability

Data will be made available on request.

Declaration of Competing Interest

None.

Acknowledgements

Nikos Priovoulos is supported by a Dutch Research Council (NWO) grant (OCENW.XS22.4.007) and an Amsterdam Brain and Cognition grant (T0922).

References and recommended reading

Papers of particular interest, published within the period of review, have been highlighted as:

- of special interest
 - of outstanding interest
1. Priovoulos N, Andersen M, Dumoulin SO, Boer VO, van der Zwaag W: **High-Resolution Motion-corrected 7.0-T MRI to derive morphologic measures from the human cerebellum in vivo.** *Radiology* 2023, **307**:e220989.
 - In this study, we describe an acquisition and processing method to resolve most of the cerebellar cortical surface *in vivo*.
 2. Marques JP, van der Zwaag W, Granziera C, Krueger G, Gruetter R: **Cerebellar cortical layers: in vivo visualization with structural high-field-strength MR imaging.** *Radiology* 2010, **254**:942-948.
 - This study showcases a method to visualize the cerebellar cortical layers.
 3. Diedrichsen J, Maderwald S, Küper M, Thürling M, Rabe K, Gizewski ER, Ladd ME, Timmann D: **Imaging the deep cerebellar nuclei: a probabilistic atlas and normalization procedure.** *NeuroImage* 2011, **54**:1786-1794.
 - This study proposes a normalization technique that facilitates the functional localization of the deep cerebellar nuclei.
 4. Sereno MI, Diedrichsen J, Tachrount M, Testa-Silva G, d'Arceuil H, De Zeeuw C: **The human cerebellum has almost 80% of the surface area of the neocortex.** *Proc Natl Acad Sci* 2020, **117**:19538-19543.
 - This is the first study to fully resolve and digitally reconstruct the human cerebellar cortical surface. The surface cortical area was found to be several factors larger than previously estimated from *in-vivo* data.
 5. Priovoulos N, Roos T, Ipek Ö, Meliado EF, Nkrumah RO, Klomp DWJ, van der Zwaag W: **A local multi-transmit coil combined with a high-density receive array for cerebellar fMRI at 7 T.** *NMR Biomed* 2021, **34**:e4586.
 6. Bazin P-L, Weiss M, Dinse J, Schäfer A, Trampel R, Turner R: **A computational framework for ultra-high resolution cortical segmentation at 7Tesla.** *NeuroImage* 2014, **93**:201-209.
 7. Tustison NJ, Avants BB, Cook PA, Zheng Y, Egan A, Yushkevich PA, Gee JC: **N4ITK: improved N3 bias correction.** *IEEE Trans Med Imaging* 2010, **29**:1310-1320.
 8. Bazin P-L, Alkemade A, van der Zwaag W, Caan M, Mulder M, Forstmann BU: **Denoising high-field multi-dimensional MRI with local complex PCA.** *Front Neurosci* 2019, **13**:1066.
 - This approach takes advantage of the redundancy in multi-dimensional MRI data to reduce noise and increase SNR in the human cerebellum.
 9. Vis G, Nilsson M, Westin C-F, Szczepankiewicz F: **Accuracy and precision in super-resolution MRI: enabling spherical tensor diffusion encoding at ultra-high b-values and high resolution.** *NeuroImage* 2021, **245**:118673.

10. Carass A, Cuzzocreo JL, Han S, Hernandez-Castillo CR, Rasser PE, Ganz M, Bellevue V, Dolz J, Ben Ayed I, Desrosiers C, et al.: **Comparing fully automated state-of-the-art cerebellum parcellation from magnetic resonance images.** *NeuroImage* 2018, **183**:150-172.
- This study compares the current state-of-the-art cerebellar parcellation techniques.
11. Zheng J, Yang Q, Makris N, Huang K, Liang J, Ye C, Yu X, Tian M, Ma T, Mou T, et al.: **Three-dimensional digital reconstruction of the cerebellar cortex: lobule thickness, surface area measurements, and layer architecture.** *Cerebellum* 2023, **22**:249-260.
- This study extracts accurate cerebellar cortical measures from post-mortem MRI.
12. Diedrichsen J, Balsters JH, Flavell J, Cussans E, Ramnani N: **A probabilistic MR atlas of the human cerebellum.** *NeuroImage* 2009, **46**:39-46.
- This study describes SUIT, a popular cerebellar segmentation method and flatmap representation. This common reference space greatly facilitated research in the cognitive and clinical role of the cerebellum.
13. Romero JE, Coupé P, Giraud R, Ta V-T, Fonov V, Park MTM, Chakravarty MM, Voineskos AN, Manjón JV: **CERES: a new cerebellum lobule segmentation method.** *NeuroImage* 2017, **147**:916-924.
14. Han S, Carass A, He Y, Prince JL: **Automatic cerebellum anatomical parcellation using U-Net with locally constrained optimization.** *NeuroImage* 2020, **218**:116819.
15. Fischl B: **FreeSurfer.** *NeuroImage* 2012, **62**:774-781.
16. Kim J, Patriat R, Kaplan J, Solomon O, Harel N: **Deep cerebellar nuclei segmentation via semi-supervised deep context-aware learning from 7T diffusion MRI.** *IEEE Access* 2020, **8**:101550-101568.
17. Tellmann S, Bludau S, Eickhoff S, Mohlberg H, Minnerop M, Amunts K: **Cytoarchitectonic mapping of the human brain cerebellar nuclei in stereotaxic space and delineation of their co-activation patterns.** *Front Neuroanat* 2015, **9**:54.
18. Huntenburg JM, Steele CJ, Bazin P-L: **Nighres: processing tools for high-resolution neuroimaging.** *GigaScience* 2018, **7**:giy082.
19. Bazin P-L, Kipping J, Steele C., Margulies D.S., Turner R., Villringer A.: **Subject-specific cortical cerebellar mapping at 3T and 7T, 19th Annual Meeting of the Organization for Human Brain Mapping, 2013.**
20. Boillat Y, Bazin P-L, van der Zwaag W: **Whole-body somatotopic maps in the cerebellum revealed with 7T fMRI.** *NeuroImage* 2020, **211**:116624.
21. Bazin P-L, Deistung, Andreas, Schäfer A, Turner R, Reichenbach, Jürgen, Timmann D: **Automated Segmentation of Cerebellar Nuclei from Ultra-High-Field Quantitative Susceptibility Maps with Multi-Atlas Shape Fusion.** In Proceedings of the Joint Annual Meeting of ISMRM - ESMRMB, 2018.
22. Bazin P-L, Alkemade A, Mulder MJ, Henry AG, Forstmann BU: **Multi-contrast anatomical subcortical structures parcellation.** *eLife* 2020, **9**:e59430.
23. Liu CJ, Ammon W, Siless V, Fogarty M, Wang R, Atzeni A, Aganj I, Iglesias JE, Zöllei L, Fischl B, et al.: **Quantification of volumetric morphology and optical property in the cortex of human cerebellum at micrometer resolution.** *NeuroImage* 2021, **244**:118627.
24. Buckner RL, Krienen FM, Castellanos A, Diaz JC, Yeo BTT: **The organization of the human cerebellum estimated by intrinsic functional connectivity.** *J Neurophysiol* 2011, **106**:2322-2345.
- This study showcases the network topography of the cerebellum in a large human sample.
25. van Es DM, van der Zwaag W, Knapen T: **Topographic maps of visual space in the human cerebellum.** *Curr Biol* 2019, **29**:1689-1694 e3..
26. King M, Hernandez-Castillo CR, Poldrack RA, Ivry RB, Diedrichsen J: **Functional boundaries in the human cerebellum revealed by a multi-domain task battery.** *Nat Neurosci* 2019, **22**:1371-1378.

This influential study showcases the role of the cerebellum across the cognitive domain through a variety of tasks.

27. Marek S, Siegel JS, Gordon EM, Raut RV, Gratton C, Newbold DJ, Ortega M, Laumann TO, Adeyemo B, Miller DB, *et al.*: **Spatial and temporal organization of the individual human cerebellum.** *Neuron* 2018, **100**:977-993 e7..
28. Seitzman BA, Gratton C, Marek S, Raut RV, Dosenbach NUF, Schlaggar BL, Petersen SE, Greene DJ: **A set of functionally-defined brain regions with improved representation of the subcortex and cerebellum.** *NeuroImage* 2020, **206**:116290.
29. Thürling M, Kahl F, Maderwald S, Stefanescu RM, Schlamann M, Boele H-J, Zeeuw CID, Diedrichsen J, Ladd ME, Koekkoek SKE, *et al.*: **Cerebellar cortex and cerebellar nuclei are concomitantly activated during eyeblink conditioning: a 7T fMRI study in humans.** *J Neurosci* 2015, **35**:1228-1239.
30. van der Zwaag W, Jorge J, Buttica D, Gruetter R: **Physiological noise in human cerebellar fMRI.** *Magn Reson Mater Phys Biol Med* 2015, **28**:485-492.
31. Park MTM, Pipitone J, Baer LH, Winterburn JL, Shah Y, Chavez S, Schira MM, Lobaugh NJ, Lerch JP, Voineskos AN, *et al.*: **Derivation of high-resolution MRI atlases of the human cerebellum at 3T and segmentation using multiple automatically generated templates.** *NeuroImage* 2014, **95**:217-231.
32. Boillat Y, Bazin P-L, O'Brien K, Fartaria MJ, Bonnier G, Krueger G, van der Zwaag W, Granziera C: **Surface-based characteristics of the cerebellar cortex visualized with ultra-high field MRI.** *NeuroImage* 2018, **172**:1-8.
33. Van Essen DC: **Surface-based atlases of cerebellar cortex in the human, macaque, and mouse.** *Ann N Y Acad Sci* 2002, **978**:468-479.
34. D'Mello AM, Gabrieli JDE, Nee DE: **Evidence for hierarchical cognitive control in the human cerebellum.** *Curr Biol CB* 2020, **30**:1881-1892 e3..
35. Katsumi Y, Zhang J, Chen D, Kamona N, Bunce JG, Hutchinson JB, Yarossi M, Tunik E, Dickerson BC, Quigley KS, *et al.*: **Correspondence of functional connectivity gradients across human isocortex, cerebellum, and hippocampus.** *Commun Biol* 2023, **6**:1-13.
36. Apps R, Hawkes R, Aoki S, Bengtsson F, Brown AM, Chen G, Ebner TJ, Isope P, Jörntell H, Lackey EP, *et al.*: **Cerebellar modules and their role as operational cerebellar processing units.** *Cerebellum* 2018, **17**:654-682.
37. Priovoulos N, de Oliveira IAF, Poser BA, Norris DG, van der Zwaag W: **Combining arterial blood contrast with BOLD increases fMRI intracortical contrast.** *Hum Brain Mapp* 2023, **44**:2509-2522.
38. Blazejewska AI, Fischl B, Wald LL, Polimeni JR: **Intracortical smoothing of small-voxel fMRI data can provide increased detection power without spatial resolution losses compared to conventional large-voxel fMRI data.** *NeuroImage* 2019, **189**:601-614.
39. van Mourik T, van der Eerden JPJM, Bazin P-L, Norris DG: **Laminar signal extraction over extended cortical areas by means of a spatial GLM.** *PLoS ONE* 2019, **14**:e0212493.
40. Waehnert MD, Dinse J, Weiss M, Streicher MN, Waehnert P, Geyer S, Turner R, Bazin P-L: **Anatomically motivated modeling of cortical laminae.** *NeuroImage* 2014, **93**:210-220.
41. Caan MWA, Bazin P-L, Marques JP, de Hollander G, Dumoulin SO, van der Zwaag W: **MP2RAGEME: T1, T2*, and QSM mapping in one sequence at 7 tesla.** *Hum Brain Mapp* 2019, **40**:1786-1798.
42. van Gelderen P, Li X, de Zwart JA, Beck ES, Okar SV, Huang Y, Lai K, Sulam J, van Zijl PCM, Reich DS, *et al.*: **Effect of motion, cortical orientation and spatial resolution on quantitative imaging of cortical R2* and magnetic susceptibility at 0.3 mm in-plane resolution at 7 T.** *NeuroImage* 2023, **270**:119992.
43. Zhang C, Karkalousos D, Bazin P-L, Coolen BF, Vrenken H, Sonke J-J, Forstmann BU, Poot DHJ, Caan MWA: **A unified model for reconstruction and R2* mapping of accelerated 7T data using the quantitative recurrent inference machine.** *NeuroImage* 2022, **264**:119680.
44. Alkemade A, Bazin P-L, Balesar R, Pine K, Kirilina E, Möller HE, Trampel R, Kros JM, Keuken MC, Bleyers RLAW, *et al.*: **A unified 3D map of microscopic architecture and MRI of the human brain.** *Sci Adv* 2022, **8**:eabj7892.
45. Amunts K, Lepage C, Borgeat L, Mohlberg H, Dickscheid T, Rousseau M-E, Bludau S, Bazin P-L, Lewis LB, Oros-Peusquens A-M, *et al.*: **BigBrain: an ultrahigh-resolution 3D human brain model.** *Science* 2013, **340**:1472-1475.