

Robust Detection of Ocular Dominance Columns in Humans using High Field HSE BOLD fMRI

E. Yacoub¹, K. Ugurbil¹, A. Shmuel^{1,2}

¹University of Minnesota, Minneapolis, Minnesota, United States, ²Max-Planck Institute for Biological Cybernetics, Tuebingen, Germany

Introduction:

The ability to reliably and reproducibly map high resolution functional architecture using fMRI techniques has been a point of debate in animal as well as human studies. Several animal and human studies have successfully mapped high resolution functional organizations (1-4), however, the robustness of the phenomenon (i.e. reproducibility and demonstration in multiple subjects), which would certainly improve the credibility of the data, has been a subject of debate, with only limited reproducibility demonstrated so far. Several different techniques have been used (i.e. initial dip, blood flow, blood volume, GE BOLD); however, which one is optimal specifically for humans, has not been established. We have previously demonstrated the feasibility and reliability of using Hahn spin echo BOLD for high spatial resolution applications at high fields. Here we demonstrate the spatial specificity of Hahn spin echo (HSE) BOLD by robust mapping of ocular dominance columns in humans at the high magnetic field of 7 T.

Background:

High spatial resolution applications in humans are limited by signal to noise ratios, contrast to noise ratios from tissue areas, large vessel contamination, motion artifacts, and subject cooperation. Spatial specificity and sensitivity for fMRI have been bolstered with the recent implementation of high field systems for human use. SNR and the BOLD effect both increase with field strength, while the blood signal tends to be diminished because of the rapid shortening of its T2 relative to that of tissue. This bodes well for the accuracy of both GE and HSE BOLD. Although it has intrinsically much lower contrast to noise ratios, HSE BOLD has the added benefit of refocusing static effects around larger vessels and being primarily sensitive to small vessel dynamic averaging effects. Previous studies in humans mapping high resolution functional architecture used GE BOLD (at 4 T) presumably because of the much higher CNR compared to that of HSE BOLD images at 4T. However, the success of the GE BOLD approach rely on the expectation that non-specific large vessel contributions will be equivalent for the two conditions and can be cancelled out. This is not necessarily the case. In the HSE approach, this requirement is significantly alleviated. Furthermore, improved CNR and SNR at magnetic fields exceeding 4T make the HSE BOLD technique feasible for such high resolution studies.

Methods:

Studies were conducted at 7 T using slab selective FOV reduction (1) for HSE (TR/TE 6000/50 ms) and 3 image segments. Resolution (60 x 256): 0.5 x 0.5 x 3 mm³. To suppress gross subject motion, a bite bar was used. In addition, any scans with significant motion were discarded. The visual stimuli were presented through fiber optic video goggles. Subjects were brought back for several repeated studies to assess the reproducibility of the functional maps. Similar anatomic locations were selected in each scan. The maps from different sessions were co-registered to allow for identification of similar columns in the different sessions. Similar maps were generated using several different statistical analyses. Imaging was performed on a region of flat cortex where the ODC's are expected to run perpendicular to the inter-hemispheric fissure.

Results:

The results from one subject, three different sessions (over the period of several months), are shown in Fig.1. The displayed maps are differential maps (i.e. right eye minus left eye, with a confidence of 85%). The right and left eye columns were arbitrarily numbered from one of the scans and then projected on the other scans, after the co-registration. The columns run orthogonal to the midline plane as shown here in an oblique slice that runs parallel to the calcarine sulcus. Despite inevitable but small differences in the slice positioning, highly reproducible maps were obtained. Similar reproducibility was seen in 3 different subjects.

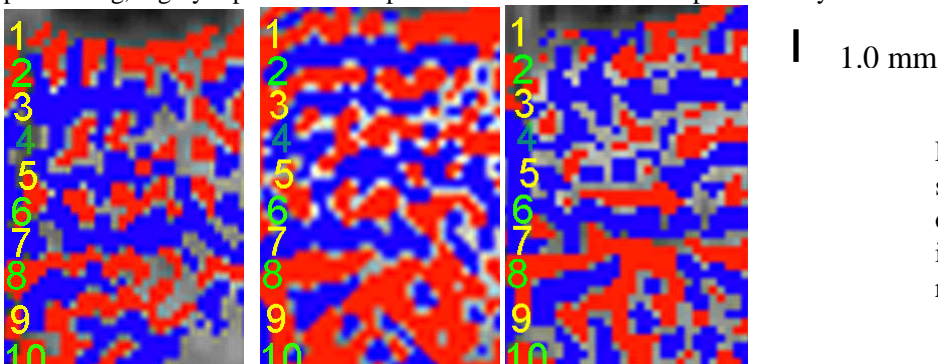


Fig.1 ODC maps from the same subject acquired on 3 different days. Red and blue colors denote increases in BOLD activity in the right and left eye, respectively.

Conclusions:

Using HSE BOLD at very high magnetic fields (7T), we have demonstrated not only that high field fMRI can produce *reliable* and *reproducible* maps at the sub-millimeter level but also that these maps have intrinsically high spatial specificity, even to the level of cortical columns in humans. We expect HSE BOLD to be the imaging choice for high resolution applications in humans at high fields.

References: 1. Menon *et al* 1997 2. Cheng *et al* 2001 3. Kim *et al* 2000 4. Duong *et al* 2001 5. Dechent *et al* 2000.

Acknowledgements: P41-RR008079, R21-EB00565, The Keck Foundation, The MIND institute.