Movements of the Glottis During Horn Performance

A Pilot Study

Peter W. Iltis, PhD,[1,4] Sarah L. Gillespie, DMA,[2] Jens Frahm, PhD,[3] Dirk Voit, PhD,[3]
Arun Joseph, PhD,[3] and Eckart Altenmüller, MD, PhD[4]

OBJECTIVE: The functional role of the glottis in brass performance is poorly understood and controversial, particularly with respect to pedagogy. Technological limitations have prevented the non-invasive, systematic study of the glottis in the past, but developments in real-time magnetic resonance imaging (RT-MRI) allow representations of glottal movement during performance on a MRI-compatible horn to be recorded and quantified. **METHODS**: We present RT-MRI data obtained on 6 advanced-level horn players from serial images acquired at an acquisition time of 33.3 ms as they performed sustained note exercises on three notes (concert E♭2, E♭4, and B♭4) at each of three dynamics (*pp*, *mf*, and *ff*) and a staccato exercise. An advanced-level trumpet player was also studied performing a modification of the staccato exercise designed to minimize vertical movement of the larynx. Glottal movements and positions in the coronal plane were analyzed using a customized MATLAB toolkit. **RESULTS**: In sustained note playing, there is a significant influence of dynamic on the degree of glottal adduction/abduction. There is greater adduction with softer notes, and greater abduction with louder notes. In slow staccato playing, glottal closure accompanies the cessation of each note and persists until iteration of the next note in the sequence. **CONCLUSIONS**: We demonstrate that RT-MRI provides a suitable method to identify and quantify glottal movement during horn playing. We further show that there is a direct relationship between dynamic level and glottal adduction/abduction, and that the glottis is involved in performing notes during slow staccato playing. *Med Probl Perform Art* 2017; 32(1):33–39.

From the [1]Department of Kinesiology, Gordon College, Wenham, MA, USA; [2]Department of Music, University of Wisconsin, Madison, WI, USA; [3]Biomedizinische NMR Forschungs GmbH am Max-Planck-Institut für biophysikalische Chemie, Göttingen, Germany; and [4]Hochschule für Musik, Theater und Medien, Hannover, Germany.

The authors declare no funding or conflicts of interest related to this study.

Address for correspondence: Dr. Peter W. Iltis, Dep. of Kinesiology, Gordon College, 225 Grapevine Rd., Wenham, MA 01984, USA. Tel: 978-867-4088. peter.iltis@gordon.edu.

https://doi.org/10.21091/mppa.2017.1007

Adduction and abduction of the vocal folds comprising the glottis are common phenomena during wind instrument performance[1–8] and are presumed to be under subconscious control. Some horn teachers, however, advocate for maintaining an "open throat" during breathing and playing, particularly in the low range.[9,10] The systematic study of glottal involvement in various aspects of horn playing skill has not been done, in part because of the limitations of data acquisition methods. Laryngoscopy during playing allows excellent visualization of the glottis,[1–8] but is uncomfortable, unnatural, and may interfere with normal movement. X-ray cinematography has also been used,[2] but its systematic employment in controlled studies is not possible because of the health risks associated with radiation exposure.

Real-time magnetic resonance imaging (RT-MRI) is a technology that has seen broad use in studying speech and swallowing,[11–13] cardiovascular function,[14–18] and, most recently, motor function inside the mouths and throats of brass musicians.[19–24] RT-MRI is noninvasive and can be conducted very easily while performing on MRI-compatible instruments.[20–22] These factors, along with its ability to provide dynamic quantitative data, make RT-MRI a logical candidate for extended study of glottal function during horn performance.

The purpose of the current investigation was two-fold: 1) to establish a method for obtaining objective measurements of glottal movement from RT-MRI films during horn playing, and 2) to examine these films for further clarification of glottal involvement during a selection of performance exercises.

METHODS

Participants

Six horn players without known illness volunteered to participate in this study. Three players were students at various German universities with accredited schools of music, two were professional hornists in regional symphonies in Germany, and the sixth was a doctoral candidate on horn from the United States. Three of the participants were male, and three were female, with the average age being 28 ± 5.1 years. In addition, one male, a 24-year old

FIGURE 1. The staccato exercise.

semi-professional trumpet player, was studied in a follow-up trial designed to refine our techniques of measuring glottal movement during staccato playing. None of the subjects had any known movement disorder involving the structures of the oral cavity and throat, and all reported that they had no other health disorders at the time of testing.

The study was done in accordance with the recommendations of the local ethics committee at the Max Planck Institute in Göttingen, Germany, and all subjects submitted written informed consent in compliance with the regulations established by this committee prior to their participation.

Procedures

Performance Tasks and Equipment

All horn-playing subjects performed a set of exercises on a custom-made (Richard Seraphinoff, Bloomington, IN) MRI-compatible, valve-less horn while lying supine within the MRI scanner. The instrument is made of graduated-diameter plastic tubing terminating in a non-ferromagnetic bell flare at one end, and a plastic mouthpiece at the other. Further details concerning the instrument and testing apparatus have been described previously.[20,21,23] A similar custom-made trumpet (Richard Seraphinoff, Bloomington, IN) was used for the pilot work on staccato playing.

The first exercises consisted of playing 3 sustained notes (8 beats duration at 60 beats/min) representing the low, middle, and upper-middle ranges of the instrument (concert E♭2, concert E♭4, and concert B♭4, respectively) at each of 3 dynamic levels (*pp*, *mf*, and *ff*). Each note was repeated two times. Thus, 9 movies were obtained for each subject from these exercises, and these were subsequently analyzed. In addition, a staccato exercise at the same tempo was performed (Fig. 1) providing a 10th film. The subjects were instructed to play each note with as short a staccato as possible by any means they desired except by using the tongue to stop the note, as this method has been deemed inferior in sound quality by numerous authors.[4,9,25,26] As explained in the Results and Discussion sections of this paper, this exercise was modified for the trumpet player to consist of staccato repetitions of only the first note in the sequence.

Real-Time MRI and Audio Data Acquisition

As in previous studies,[20,21,23] a 3T MRI system (Magnetom Prisma, Siemens Healthcare, Erlangen, Germany) equipped with a 64-channel head coil was used to obtain the images. RT-MRI was based on previously established techniques,[21,27,28] producing radially encoded gradient-echo images (1.96 ms repetition time, 1.28 ms echo time, 5° flip angle) at a rate of 30 fps (33.32 ms resolution) with 1.4 mm in-plane resolution, 5-mm slice thickness, and 192 × 192 mm^2 field-of-view. Movies and images were obtained in a coronal orientation to allow identification of a region of interest (ROI) comprising the distance between the arytenoid cartilages (Fig. 2 panel A). These structures attach to the posterior vocal folds, and their medial and lateral movements represent adduction and abduction of the vocal folds, respectively. This orientation was chosen rather than a more traditional transverse view, as typically seen during laryngoscopy, because of the thinness of the vocal folds (2–3 mm) and their tendency to move vertically during the

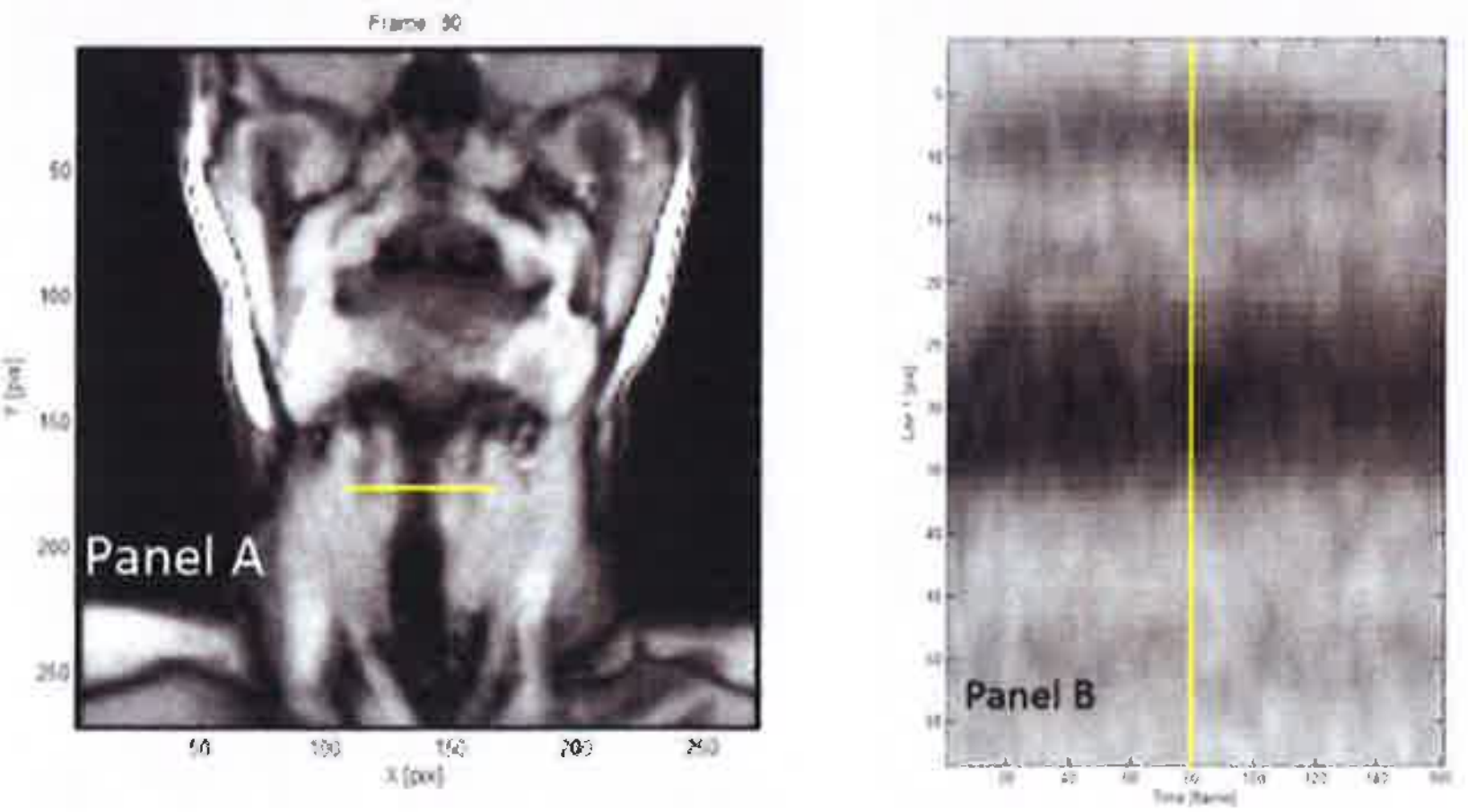

FIGURE 2. Coronal image (*panel A*) and corresponding unfiltered line profile graph (*panel B*) during performance of a sustained (~4.8 s) E♭4 at *ff* dynamic. The horizontal line in panel A transects the left and right arytenoid cartilages at the point of glottal fissure measurement. Illustrated sampling time is ~5.3 s. See text for more details.

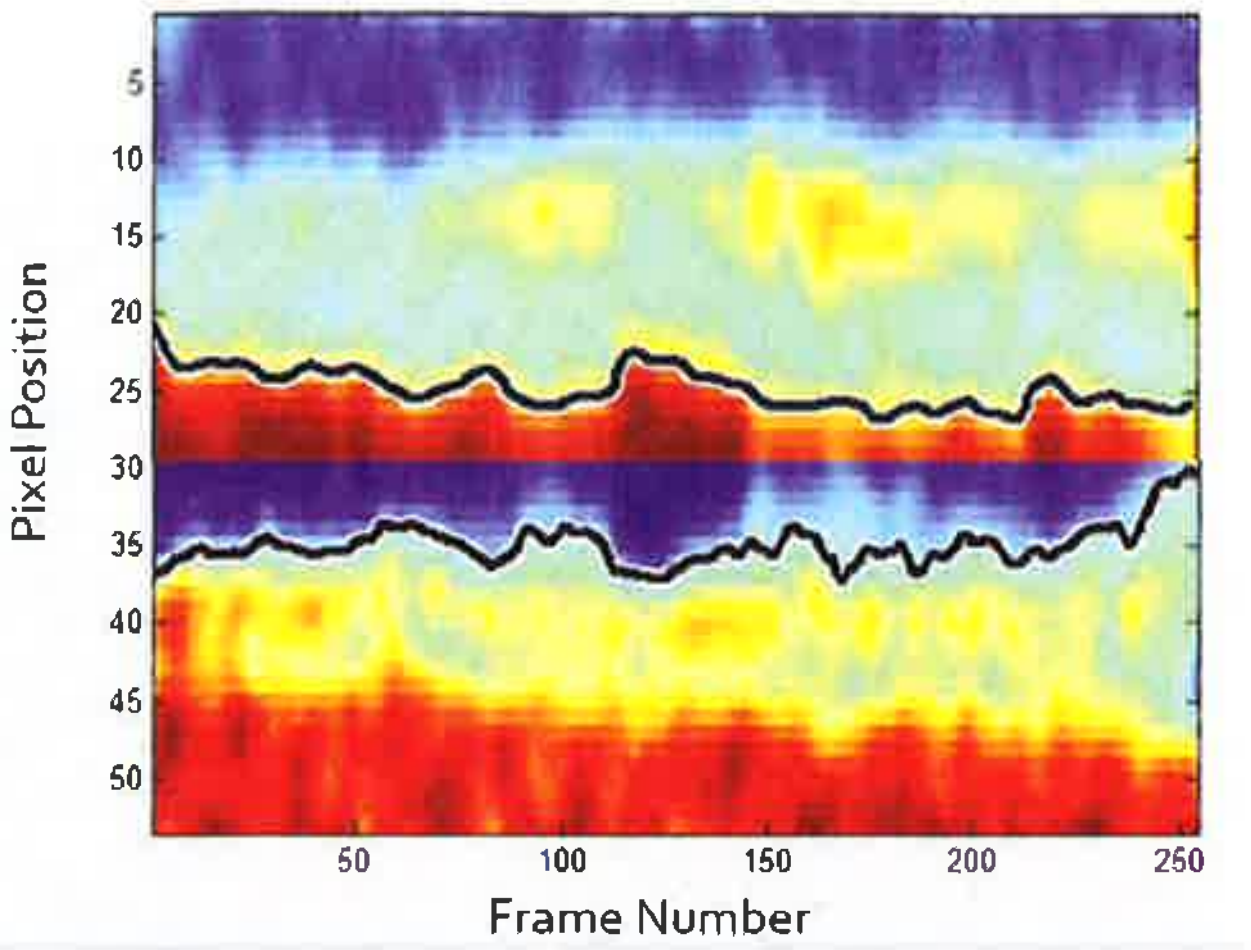

FIGURE 3. Example of an image-processed line profile graph depicting the left and right glottal borders (upper and lower lines, respectively) during a sustained B♭4/*pp* trial. Sampling time illustrated is ~8.3 s. See text for explanation of image processing.

playing of different notes. In preliminary testing, this vertical movement brought them into and out of the imaging plane of the MRI acquisition and was unacceptable.

A MR-compatible optical microphone (Dual Channel-FOMRI, Optoacoustics, Or Yehuda, Israel) was attached to the bell of the horn outside the bore of the magnet, and sound recordings were subsequently synchronized to image acquisition, as described by Niebergall et al.[12] The audio track for the harmonic sequence exercises was examined using standard audio-processing software (Audacity: http://audacity.sourceforge.net) to assess note quality and to determine the frame number range corresponding to the portion of the exercise to be analyzed. For the sustained note exercises, the analyzed portion comprised approximately 100 frames of data (~3 s) when the sound of the note was steadiest as determined by the experimenter using both visual (waveform) and audio information made available within the Audacity software. This software also makes possible the determination of the time and frame number for the beginning and ending of each note during staccato playing. For the staccato exercise, line profile graphs were descriptively examined (see Fig. 5 and accompanying text).

Identification and Analysis of Glottal Fissure

Quantitative information from the RT-MRI films was obtained using a customized RT-MRI toolbox developed for MATLAB (MATLAB R2014a, Natick, MA, including the Image Processing and Signal Processing Toolboxes), as described previously.[20,23] A reference line was positioned horizontally over the left and right arytenoid cartilages (Fig. 2 panel A). Movements of the glottis caused the pixel luminescence values along this line to vary with time during the exercises, and corresponding line profile graphs depicting this movement were created by the customized MATLAB software. Figure 2 panel B depicts such a graph during a sustained note exercise, with a vertical line indicating the precise moment (frame 80, 2.66 s) at which the coronal view (panel A) is seen during the exercise. Note that the orientation of panel B is rotated 90° clockwise with respect to panel A, so that the vertical line in panel B is a full-scale depiction of the reference line in panel A with a length of ~58 pixels. The dark area between approximately the 25th and 35th pixels in panel B represents the magnified distance between the arytenoid cartilages (henceforth referred to as the glottal fissure) in panel A.

The image in panel B contains blurring on either side of the glottal fissure. In order to obtain objective determination of the inner borders, the customized RT-MRI toolbox allows a Wiener2 filter to be applied to the raw image, and enables the calculation of gradients (derivative profiles) which conduct differentiation of luminescence values across the vertical (spatial) dimension. It is then possible to calculate the point along the reference line (Fig. 2 panel B) at which the greatest rate of change in pixel luminescence is found in each frame for the left (upper edge, Fig. 2 panel B) and right (lower edge, Fig. 2 panel B) borders of the glottal fissure. These are luminescence centroid values for each frame that, when plotted as a function of time, yield objective depictions of both the left and right edges of the glottis (Fig. 3). The resulting mean distance between these edges during the sampling period is calculated as the size of the glottal fissure. Both within-rater and between-rater reliability of this edge detection method have been assessed in our laboratory in a blinded, unpublished study. Intra-class correlation coefficients for both within- and between-rater reliability are excellent (≥0.918 and 0.968, respectively).

Statistical Analysis of Glottal Fissure Data

The glottal fissure data in this study were analyzed using a 2-way ANOVA with repeated measures using the IBM-SPSS program, version 2.4 (IBM-SPSS, Armonk, NY, USA). The model contained two within-subjects factors, each with three levels: pitch (E♭2, E♭4, and B♭4) and dynamic (*pp*, *mf*, and *ff*). Mauchley's test for sphericity was used to determine the degrees of freedom required adjustments for both main and interaction effects. All statistical analyses were run at the $p<0.05$ level of significance. Technical limitations on several trials involving the performance of E♭4 yielded images in which the RT-MRI software was unable to distinguish the glottal border, creating missing values for two subjects at both the *pp* and *mf* dynamics, and for three subjects at the *ff* dynamic. This reduced the data set to only three subjects for the complete analysis. Subsequently, the E♭4 trial was eliminated, and the analysis run a second time to allow for all six subjects to be included. Both sets of results are reported.

Glottal Involvement in Staccato Exercises

Quantitative analyses were not performed in assessing the role of the glottis in staccato playing. Rather, descriptive



FIGURE 4. Estimated marginal means (±SE) showing the effect of dynamic on glottal fissure size, using all three notes combined, across three subjects. Fissure size differences between the *pp* and *ff* dynamic approached statistical significance (*p*=0.056).

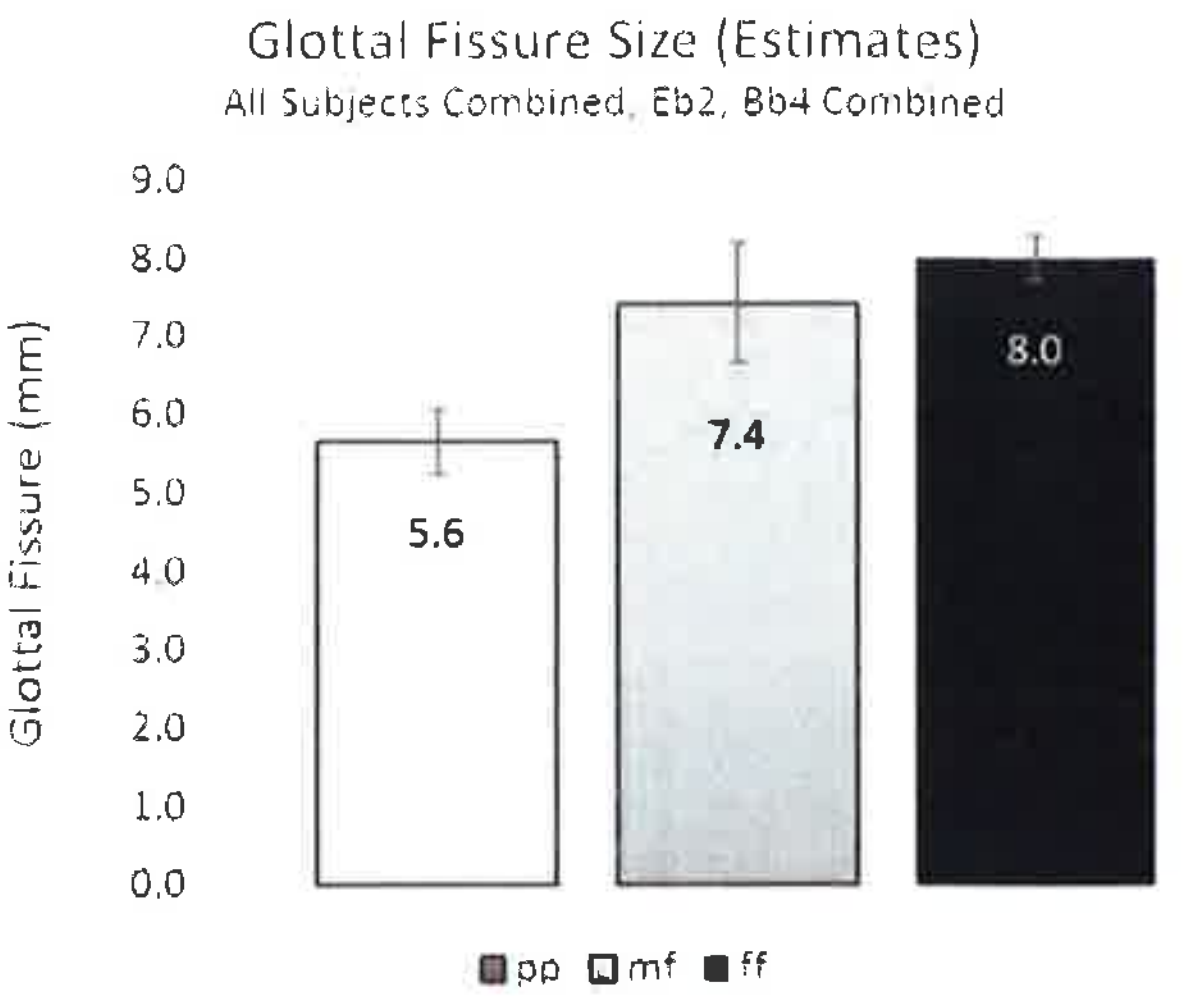

FIGURE 5. Estimated marginal means (±SE) showing the effect of dynamic on glottal fissure size, using E♭2 and B♭4 only, combined across all six subjects. Fissure size differences between the *pp* and *mf* as well as between *pp* and *ff* were statistically different (p=0.032 and 0.000, respectively).

observations were made from the RT-MRI films. In addition, line profile graphs of glottal movement were produced using the RT-MRI toolbox, using the same reference line positioning and analysis methods described for the sustained note exercises. Finally, in subsequent pilot testing with the trumpet performer, the precise position of the vocal folds was determined for the start and end of each note iteration and marked with vertical lines (see Fig. 7).

RESULTS

Sustained Note Exercises

Mauchley's test of sphericity was not significant for pitch or dynamic (*p*=0.927 and 0.964, respectively), so no adjustments to the degrees of freedom were required. The 2-way repeated measures ANOVA revealed a main effect demonstrated for dynamic level (F (2, 4) = 8.266, *p*=0.038, observed power 0.675), but there was no main effect for pitch (F (2, 4) = 1.567, *p*=0.314), or for pitch/dynamic interaction (F (4, 8) = 3.060, *p*=0.083). The adjusted mean glottal fissure size (estimated marginal means ± SE) for dynamic level are presented in Figure 4, showing a clear influence of dynamic on glottal fissure size. Subsequent pairwise comparisons revealed the primary source of the observed difference to be nearly significant differences between glottal fissure size at *pp* vs *ff* (mean difference = 3.33 mm, *p*=0.056).

When the repeated measures ANOVA was run a second time using all six subjects on only E♭2 and B♭4 (Fig. 5), the main effect for pitch and the interaction effect (pitch × dynamic) both remained insignificant, but again, differences were apparent with respect to the effect of dynamic on glottal fissure size (F (2, 10) = 11.356, *p*=0.003, observed power = 0.961). Subsequent pairwise comparisons revealed significant differences in glottal fissure size between both *pp* and *mf* (mean difference = 1.77, *p*=0.032) and between *pp* and *ff* (mean difference = 2.37, *p*=0.000).

Staccato Exercises

Figure 6 shows an example of a profile line graph of one subject that is analogous to Figure 2 panel B. The vertical line appearing at approximately frame 30 represents the beginning of the first note initiation, and the subsequent vertical "striping" that is seen corresponds to intermittent adduction of the glottis occurring during the exercise. This "striping" is not equally visible during the entire trial, and the degree of glottal closure does not appear to be perfectly consistent. In addition, there is apparently a narrowing of the dark region representing the glottal fissure as the exercise progresses.

Subsequent study of the coincidence of this "striping" with note initiation and cessation was inconclusive in this subject and in the others. Indeed, in several subjects, clear visualization of the borders of the glottal fissure was very difficult, and line profile graphs like Figure 6 could not be generated. The implications of this and the suggestion of a proposed solution will be described later in the Discussion portion of this paper.

DISCUSSION

Sustained Note Exercises

We have shown that adjustment of the glottal fissure size is present during the performance of sustained notes at dif-

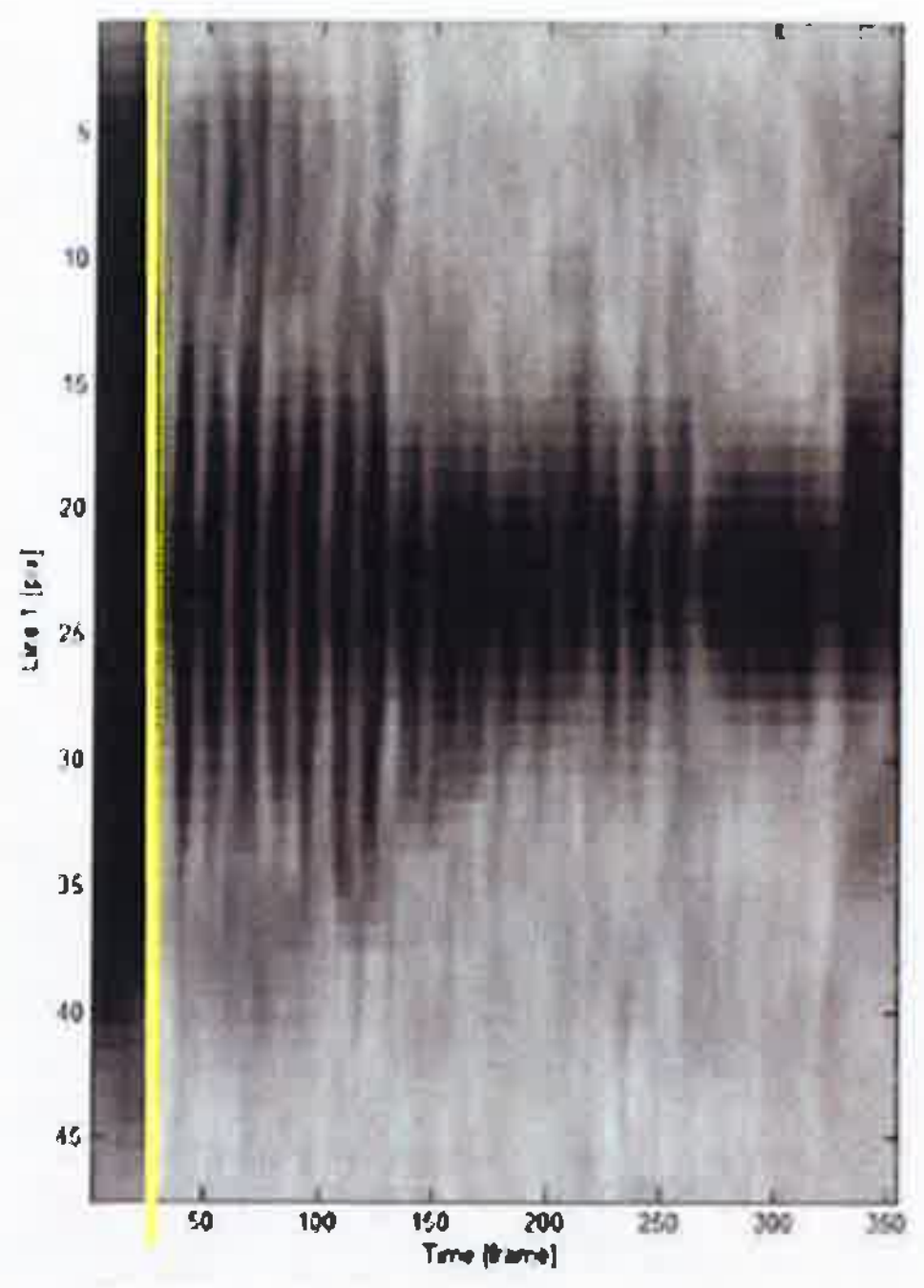

FIGURE 6. Example line profile graph during performance of the staccato exercise performed by the horn players. Sampling period is -11.7 sec. See text for details.

ferent dynamic levels across a selected range of notes in this sample of pre-professional horn players. Specifically, notes played softly involve a smaller glottal fissure than loudly played notes. These findings affirm those of Carter[2] who presented clear evidence of this in his work using x-ray imaging. In contrast, it does not appear that pitch has an independent effect on glottal fissure size. These findings are consistent with the theory originally proposed by Farkas,[4] who postulated that the glottis is one of several points of resistance whereby brass players regulate airflow, and that its manipulation is particularly important at a *pp* dynamic level. Whether these changes are made consciously or unconsciously is unknown. However, the subjects in the current study were given no instruction regarding how they were to achieve the different dynamic levels, but rather were simply told to play at each of the three indicated dynamics. It is therefore possible that the adjustments were completely subconscious.

As mentioned previously, the size of the glottal fissure corresponds directly to the loudness of the dynamic being played. It is therefore tempting to suggest that these changes are altering the dynamic level. However, the glottis is only one point along the length of the airway at which adjustments can be made, and the degree to which the size of the movements we measured actually affect pressure within the oral cavity (and by extension, note loudness) is unknown. Measuring intra-oral or trans-glottal pressures during our RT-MRI trials would be extremely difficult, but might help in clarifying this question. Future studies should attempt to address this.

Brass pedagogues in response to these findings may raise an important, related question. Should students be made aware of the glottal mechanism and taught to employ it? As stated previously, most brass teachers advocate an open throat during playing, suggesting that any conscious attempts to restrict airflow may have a detrimental effect on sound quality. To this objection, two ideas seem pertinent. First, do the very best horn players use this mechanism? Second, might there be ways to teach glottal fissure control that would not cause a detrimental effect on sound?

To the first question, the current investigation did not study the "very best" horn players and was limited to six pre-professionals. Though the subjects used were at an advanced level and presumably had a horn sound that was considered by many as very good, it is unknown whether glottal movements are similarly employed by truly elite horn players. Further study using such elite performers clearly seems indicated, and many more subjects need to be studied to bring greater statistical rigor to the findings.

Regarding the instruction of glottal manipulation to assist in dynamic control, a clear answer is more difficult. For students having difficulty producing an adequately soft pianissimo dynamic level, it may be that talking about this technique could be helpful. But excessive tension in the throat and neck certainly has adverse effects on tone quality,[4,9,25,26] and it is possible that drawing attention to glottal manipulation could bring about this unwanted result. Nonetheless, if elite performers successfully employ this mechanism without adverse effects on their sound, there must be a way to do it without such excess tension. Further study experimenting with different ways of narrowing the glottis while maintaining a relaxed throat and neck should be conducted. The use of EMG biofeedback to monitor tension in the throat and neck might be helpful in such work.

It appears that changes in glottal fissure size are related to playing at different dynamic levels. However, this is not the only mechanism available to horn players. Air speed is also altered by how hard the player blows, by the size of the aperture formed by the embouchure, by the bore of the mouthpiece, and by the resistance of the instrument itself.[4,10,25] Further study will be required to elucidate the degree to which glottal manipulation plays a role, but that it does play a role seems likely based upon these results.

There may be additional mechanisms employed by horn players to regulate air speed and dynamic levels. We have seen two other phenomena in previous data that suggest this. We have published data showing how changes in oral cavity size seen in sagittal views accompany changes in pitch in elite horn players.[20,21,23] In these same experiments, we have also seen similar changes when playing at different dynamic levels (unpublished data). Specifically, softer dynamics on a given note appear to be commensurate with reductions in oral cavity size. Likewise, in coronal images of the channel formed between the roof of the mouth and the superior surface of the tongue, there is verification of a narrowing of this channel at soft dynamic

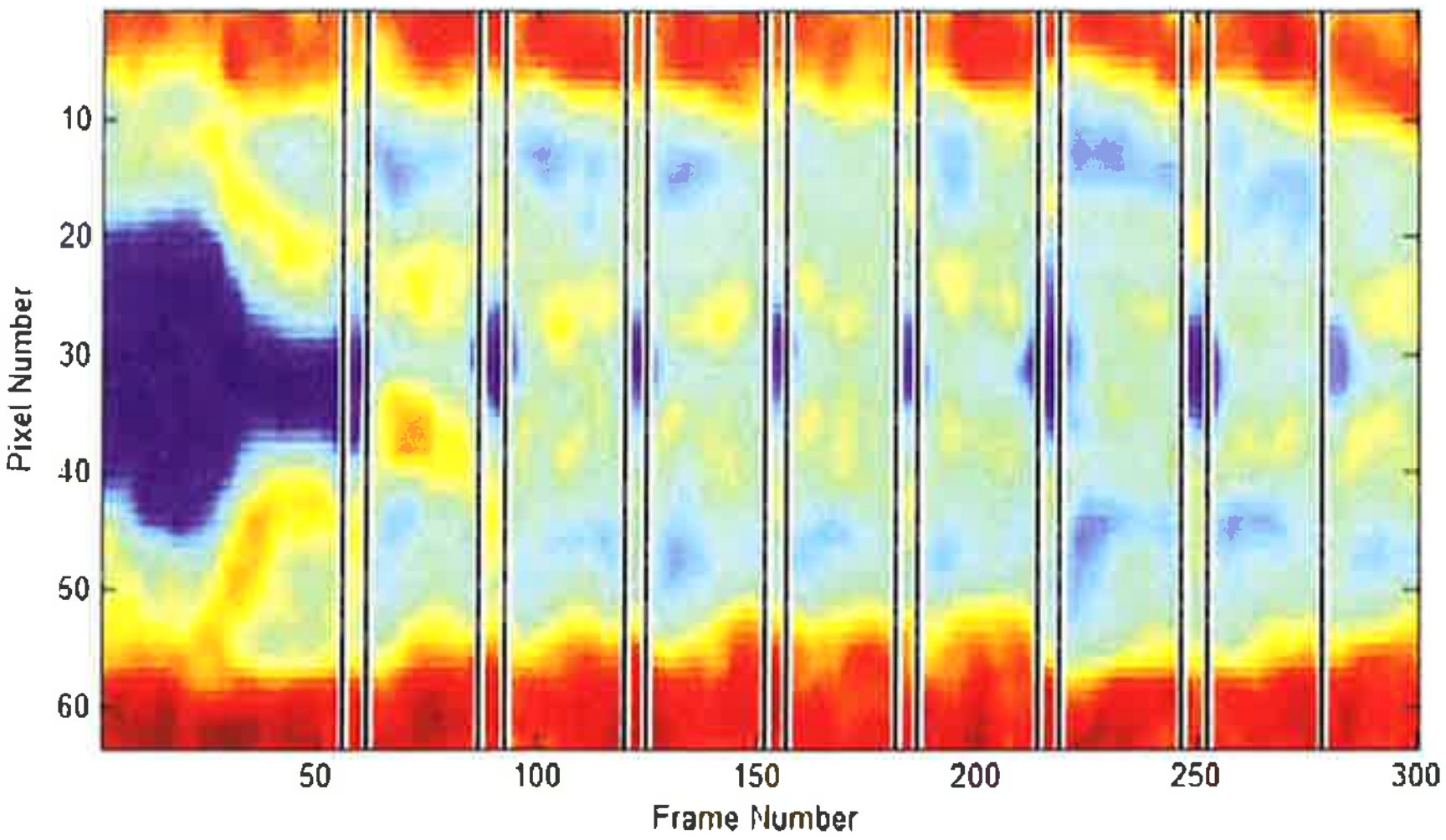

FIGURE 7. MATLAB image of glottal movement during performance of a repeated staccato note (C4, 262 Hz) on an MRI-compatible trumpet. Sampling period is 10 sec. (See text for details.)

levels. Apparently, there is a complex coordination of numerous mechanisms at play that as yet have not been studied systematically. To date, we have only been able to observe these phenomena in separate trials using different RT-MRI views (slices), and the results of this work are forthcoming. However, we are conducting additional experimentation attempting to allow simultaneous assessment of multiple views in multiple planes that, if successful, will allow a clearer understanding of the coordination of these mechanisms.

Staccato Exercises

A role for the glottis during the staccato exercise was clearly seen, as depicted in Figure 5 where vertical "striping" appears during the exercise. The stripes appear whenever adduction of the arytenoid cartilages occurs. However, it does not appear that the adduction involves complete closure of the glottis, as the vertical stripes fail to connect and actually appear to be quite variable in terms of the degree to which closure occurs. Further, the glottal fissure appears to vary during the exercise, as is indicated by the dark area between the left (upper) and right (lower) arytenoid cartilage borders. This glottal fissure variability seems to progressively narrow during the exercise, and this is puzzling considering the note sequence of the task (see Fig. 1). Further, the example presented in Figure 6 could not be reproduced in all subjects, as it was difficult to clearly distinguish the borders of the arytenoid cartilages in all subjects.

We believe that these difficulties are largely a function of the exercise itself. When pitch changes, vertical movement of the larynx occurs, and it is possible that horizontal movements also occur, although using the coronal view, the latter possibility cannot be conclusively verified. These movements introduce variability in the images of the glottal fissure that interferes with conclusive statements about changes in fissure size. Further, because the arytenoid cartilage borders may move into and out of focus with these movements, spurious observations about the degree of adduction or abduction of the arytenoid cartilages are likely.

In follow-up pilot experimentation, a trumpet player was studied while performing a staccato exercise on an MRI-compatible trumpet (Richard Seraphinoff, builder, Bloomington, IN). This exercise, in contrast to the current study, was performed on a single note, C4 (262 Hz). The results are shown in Figure 7.

In Figure 7, the dark areas enclosed by vertical lines in the center of the image represent an open glottis, and the areas between open areas represent closure of the glottis. The pairs of vertical lines represent the instant of sound production and sound cessation, respectively. This was determined by analyzing the .wav sound files in Audacity (Sound Finder function) treating as silence all periods below –26 dB. Adduction of the arytenoid cartilages occurs at the end of each note, and the glottis remains closed until the beginning of each subsequent note. Also, there is a slight lag time in sound production with respect to abduction, and the lag time is reversed with respect to sound cessation (i.e., sound cessation precedes complete glottal closure). Finally, the size of the glottal fissure, as suggested by the vertical dimension of each dark blue area, seems to be much more consistent than in the horn player presented previously (Fig. 6).

CONCLUSIONS

This study confirms the involvement of glottal movement during dynamic level changes and in producing staccato notes at slow tempos. The arytenoid cartilages, to which the vocal folds are attached, are adducted during the production of soft notes, and they are progressively abducted at louder dynamics. Further, adduction and abduction of these structures also accompany staccato playing when performing at a slow tempo (60 beats/min) on repeated, unchanging notes as performed by the trumpet player. Specifically, the cessation of staccato notes occurs when the glottis closes, and the initiation of subsequent notes involves opening the glottis. Vertical movements of the larynx during staccato note changes (the horn players) make detection of this impossible.

Future work needs to extend this study to include: a) modified testing protocols that enhance imaging quality by minimizing accessory laryngeal movement, b) more subjects (in particular, elite subjects to establish a "gold standard"), c) additional brass instruments, d) if possible, determination of the degree to which glottal movements contribute to regulating pressure changes in the oral cavity and thus, dynamic levels, and e) advancements in RT-MRI technology that allow simultaneous multi-plane imaging to study the coordination of multiple mechanisms of control.

REFERENCES

1. Bailey RE. An investigation of laryngeal activity of trumpet players during the performance of selected exercises [dissertation]. Denton, TX: Univ. of North Texas; 1989: p168.
2. Carter W. The role of the glottis in brass playing. *Instrumentalist* 1966; 21(5):75–79.
3. Eckley CA. Glottic configuration in wind instrument players. *Braz J Otorhinolaryngol* 2006; 72(1):45–7.
4. Farkas P. *The Art of Brass Playing: A Treatise on the Formation and Use of the Brass Player's Embouchure.* Bloomington, IN: Brass Publ.; 1962: p65.
5. Gallivan GJ, Eitnier CM. Vocal fold polyp in a professional brass/wind instrumentalist and singer. *J Voice* 2006; 20(1):157–64. doi: 10.1016/j.jvoice.2004.11.006
6. King A, Ashby J, Nelson C. Laryngeal function in wind instruments: the brass. *J Voice* 1989; 3(1):65–7. doi: 10.1016/S0892-1997(89)80123-7
7. Weikert M, Schlomicher J. Laryngeal movements in saxophone playing: video-endoscopic investigations with saxophone players: a pilot study. *J Voice* 1999; 13(2):265–73. doi: 10.1016/S0892-1997(99)80031-9
8. Mukai S. [Laryngeal movements during wind instruments play] [in Jpn]. *Nihon Jibiinkoka Gakkai Kaiho* 1989; 92(2):260–70.
9. Gardner R. *Mastering the Horn's Low Register.* Richmond, VA: International Opus; 2002.
10. Rider W. *Real World Horn Playing*, 2nd ed. San Jose, CA: W. Rider Publ; 2006.
11. Engwall O. A revisit to the application of MRI to the analysis of speech production—testing our assumptions. In: Proceedings of the 6th International Seminar on Speech Production, Sydney, 2003.
12. Niebergall A, et al. Real-time MRI of speaking at a resolution of 33 ms: undersampled radial FLASH with nonlinear inverse reconstruction. *Magn Reson Med* 2013; 69(2):477–85. doi: 10.1002/mrm.24276
13. Olthoff A, et al. On the physiology of normal swallowing as revealed by magnetic resonance imaging in real time. *Gastroenterol Res Pract* 2014; 2014:493174. doi: 10.1155/2014/493174.
14. Horvath KA, et al. Real-time magnetic resonance imaging guidance for cardiovascular procedures. *Semin Thorac Cardiovasc Surg* 2007; 19(4):330–5. doi: 10.1053/j.semtcvs.2007.10.006
15. Joseph AA, et al. Real-time phase-contrast MRI of cardiovascular blood flow using undersampled radial fast low-angle shot and nonlinear inverse reconstruction. *NMR Biomed* 2012; 25(7):917–24. doi: 10.1002/nbm.1812
16. Kober F, et al. Cine-MRI assessment of cardiac function in mice anesthetized with ketamine/xylazine and isoflurane. MAGMA 2004; 17(3-6):157–61. doi: 10.1007/s10334-004-0086-0
17. Untenberger M, et al. Advances in real-time phase-contrast flow MRI using asymmetric radial gradient echoes. *Magn Reson Med* 2016; 75(5):1901–8. doi: 10.1002/mrm.25696
18. Zhang S, et al. Real-time magnetic resonance imaging of cardiac function and flow-recent progress. *Quant Imag Med Surg* 2014; 4(5):313–29. doi: 10.3978/j.issn.2223-4292.2014.06.03
19. Echternach M, et al. Vocal tract and register changes analysed by real-time MRI in male professional singers-a pilot study. *Logoped Phoniatr Vocol* 2008; 33(2):67–73. doi: 10.1080/14015430701875653
20. Iltis PW, et al. Inefficiencies in motor strategies of horplayers with embouchure dystonia. *Med Probl Perform Art* 2016; 31(2):69–77. doi: 10.21091/mppa.2016.2014
21. Iltis PW, et al. Divergent oral cavity motor strategies between healthy elite and dystonic horn players. *J Clin Mov Disord* 2015; 2:15. doi: 10.1186/s40734-015-0027-2
22. Iltis PW, et al. High-speed real-time magnetic resonance imaging of fast tongue movements in elite horn players. *Quant Imag Med Surg* 2015; 5(3):374–81. doi: 10.3978/j.issn.2223-4292.2015.03.02
23. Iltis PW, et al. Real-time MRI comparisons of brass players: a methodological pilot study. *Hum Mov Sci* 2015; 42:132–45. doi: 10.1016/j.humov.2015.04.013
24. Schumacher M, et al. Motor functions in trumpet playing-a real-time MRI analysis. *Neuroradiol* 2013; 55(9):1171–81. doi: 10.1007/s00234-013-1218-x
25. Epstein E. Horn playing from the inside out: a method for all brass musicians. Eli Epstein Productions; 2013.
26. Fox F. Essentials of brass playing : an explicit, logical approach to important basic factors that contribute to superior brass instrument performance. Los Angeles: Fox; 1974: p64.
27. Uecker M, Zhang S, Frahm J. Nonlinear inverse reconstruction for real-time MRI of the human heart using undersampled radial FLASH. *Magn Reson Med* 2010; 63(6): 1456–62. doi: 10.1002/mrm.22453
28. Uecker M, et al. Real-time MRI at a resolution of 20 ms. *NMR Biomed* 2010; 23:986–94. doi: 10.1002/nbm.1585

Accepted 30-Oct-2016

https://doi.org/10.21091/mppa.2017.1007