



Behavioural Neurology

Unraveling corticobasal syndrome and alien limb syndrome with structural brain imaging[☆]

Franziska Albrecht ^{a,*}, Karsten Mueller ^a, Tommaso Ballarini ^a, Leonie Lampe ^{a,b}, Janine Diehl-Schmid ^{c,d}, Klaus Fassbender ^{c,e}, Klaus Fliessbach ^{c,f}, Holger Jahn ^{c,g}, Robert Jech ^o, Jan Kassubek ^{c,h}, Johannes Kornhuber ^{c,i}, Bernhard Landwehrmeyer ^h, Martin Lauer ^{c,j}, Albert C. Ludolph ^h, Epameinondas Lyros ^{c,e}, Johannes Prudlo ^{c,k}, Anja Schneider ^{c,f}, Matthis Synofzik ^{c,l,m}, Jens Wiltfang ^{c,n}, Adrian Danek ^{c,p}, Markus Otto ^{c,h}, FTLD-Consortium¹ and Matthias L. Schroeter ^{a,b,c}

^a Max Planck Institute for Human Cognitive and Brain Sciences, Leipzig, Germany

^b Clinic of Cognitive Neurology, University of Leipzig, Germany

^c FTLD Consortium Germany, Germany

^d Department of Psychiatry and Psychotherapy, Technical University of Munich, Germany

^e Clinic for Neurology, Saarland University, Germany

^f Department of Neurodegenerative Diseases and Geriatric Psychiatry, University Bonn, Germany

^g Clinic for Psychiatry and Psychotherapy, University Hospital Hamburg-Eppendorf, Germany

^h Clinic for Neurology, University of Ulm, Germany

ⁱ Department of Psychiatry and Psychotherapy, Friedrich-Alexander-University Erlangen-Nuremberg, Germany

^j Clinic for Psychiatry, Psychosomatic Medicine and Psychotherapy, University Würzburg, Germany

^k Department of Neurology, Rostock University Medical Center, Rostock, Germany & German Center for Neurodegenerative Diseases, Rostock, Germany

^l Department of Neurodegenerative Diseases, Centre for Neurology & Hertie-Institute for Clinical Brain Research, University of Tübingen, Germany

^m German Center for Neurodegenerative Diseases (DZNE), Tübingen, Germany

ⁿ University Medical Center Göttingen, Germany & German Center for Neurodegenerative Diseases (DZNE) Göttingen, Germany

^o Department of Neurology and Center of Clinical Neuroscience, First Faculty of Medicine, Charles University, Prague, Czech Republic

^p Clinic of Neurology, Ludwig Maximilian University of Munich, Germany

ARTICLE INFO

Article history:

Received 10 August 2018

Reviewed 25 September 2018

ABSTRACT

Alien limb phenomenon is a rare syndrome associated with a feeling of non-belonging and disowning toward one's limb. In contrast, anarchic limb phenomenon leads to involuntary but goal-directed movements. Alien/anarchic limb phenomena are frequent in corticobasal

[☆] Statistical Analysis conducted by Franziska Albrecht, M.Sc., Max Planck Institute for Human Cognitive and Brain Sciences.

* Corresponding author. Max Planck Institute for Human Cognitive and Brain Sciences, Stephanstr. 1A, 04103 Leipzig, Germany.
E-mail address: fabrecht@cbs.mpg.de (F. Albrecht).

¹ Members of the FTLD-Consortium are listed under the Acknowledgments section.

<https://doi.org/10.1016/j.cortex.2019.02.015>

0010-9452/© 2019 The Authors. Published by Elsevier Ltd. This is an open access article under the CC BY-NC-ND license (<http://creativecommons.org/licenses/by-nc-nd/4.0/>).

Revised 3 December 2018
 Accepted 15 February 2019
 Action editor Stephen Jackson
 Published online 25 February 2019

Keywords:

Alien limb syndrome
 Anarchic limb syndrome
 Corticobasal syndrome
 Diagnosis prediction
 Support vector machine

syndrome (CBS), an atypical parkinsonian syndrome characterized by rigidity, akinesia, dystonia, cortical sensory deficit, and apraxia.

The structure–function relationship of alien/anarchic limb was investigated in multi-centric structural magnetic resonance imaging (MRI) data. Whole-group and single-subject comparisons were made in 25 CBS and eight CBS-alien/anarchic limb patients versus controls. Support vector machine was used to see if CBS with and without alien/anarchic limb could be distinguished by structural MRI patterns.

Whole-group comparison of CBS versus controls revealed asymmetric frontotemporal atrophy. CBS with alien/anarchic limb syndrome versus controls showed frontoparietal atrophy including the supplementary motor area contralateral to the side of the affected limb. Exploratory analysis identified frontotemporal regions encompassing the pre-/and postcentral gyrus as compromised in CBS with alien limb syndrome. Classification of CBS patients yielded accuracies of 79%. CBS-alien/anarchic limb syndrome was differentiated from CBS patients with an accuracy of 81%. Predictive differences were found in the cingulate gyrus spreading to frontomedian cortex, postcentral gyrus, and temporoparietooccipital regions.

We present the first MRI-based group analysis on CBS-alien/anarchic limb. Results pave the way for individual clinical syndrome prediction and allow understanding the underlying neurocognitive architecture.

© 2019 The Authors. Published by Elsevier Ltd. This is an open access article under the CC BY-NC-ND license (<http://creativecommons.org/licenses/by-nc-nd/4.0/>).

1. Introduction

Alien and anarchic limb syndromes (AL) are peculiar phenomena that encompass patients struggling with an extremity experienced as rogue. In 1972, this syndrome was first acknowledged by Brion and his colleagues as ‘main étrangère’ (Brion, 1972). Only in 1991, Della Sala et al. published a first attempt to disentangle alien and anarchic limb syndrome cases, introduced an English terminology and description for the scientific community (Della Sala, Marchetti, & Spinnler, 1991). Alien limb syndrome is characterized by a feeling that the limb is unfamiliar or does not belong, whereas anarchic limb syndrome additionally involves the extremity performing targeted but unintended movements that are recognized as one's own (Della Sala et al., 1991; Marchetti & Della Sala, 1998; Synofzik, Vosgerau, & Newen, 2008). Alien limb, or posterior variant, seems related to the postcentral gyrus and somatosensory cortex, while anarchic limb, or frontal variant, seems related to the supplementary motor area and medial prefrontal cortex (Hassan & Josephs, 2016; Marchetti & Della Sala, 1998). In the following we generally use the term AL as an umbrella term for both alien and anarchic limb phenomena – in the literature both syndromes are often confounded – but apply the exact terms if referring to the peculiar phenomena. AL can be caused by various diseases, amongst which corticobasal syndrome (CBS) is the most frequent (Graff-Radford et al., 2013). CBS is a rare, atypical parkinsonian syndrome characterized by rigidity, akinesia, dystonia, cortical sensory deficit, and apraxia (Armstrong et al., 2013). Revised diagnostic criteria of CBS consider AL an important diagnostic criterion, seen in 30% of CBS patients. However, the exact anatomical correlates of AL are still a matter of debate.

This multi-center study assessed structural differences in the brains of CBS patients with and without AL. Our sample

consisted of 25 CBS patients, of which eight were diagnosed with AL. In the main analyses we did not distinguish between the subtypes of AL, as it would lead to insufficiently powered analysis. In an additional exploratory pilot analysis, we divided the CBS-AL cohort into four alien and three anarchic limb syndrome patients and compared them to the whole-group of controls to unmask the specific anatomical counterpart. Whole-group analyses were performed using voxel-based morphometry. We investigated whether multivariate pattern recognition (support vector machine) could distinguish between CBS patients and controls and also predict AL in CBS. We hypothesized atrophy in CBS with AL in the supplementary motor area, medial prefrontal cortex, posterior postcentral gyrus, and somatosensory cortex. For the CBS versus healthy controls contrast, we hypothesized atrophy in frontal, parietal, and temporal lobes.

2. Material and methods

2.1. Participants

Multi-centric patients' data were included from the German Consortium of Frontotemporal Lobar Degeneration (Otto et al., 2011). Detailed information on patients/controls' demographic data and summarized AL symptoms are listed in Table e1–e3. Specialists of the respective clinics (i.e., neurologists and/or psychiatrists) examined the patients thoroughly according to a standard operating procedure protocol and evaluated diagnosis (here CBS) as well as the occurrence of AL (i.e., ‘alien feeling’ or ‘unintended movements’) among several other clinical symptoms/syndromes to assess whether they fit the inclusion criteria for the FTLD Consortium (Otto et al., 2011). Twenty-five CBS patients were compared with 25 age- and gender-matched healthy controls. The patient

group was subdivided into a cohort of 17 CBS patients without AL (CBS-O) and a cohort of eight CBS patients with AL (CBS-AL). Four patients were diagnosed with alien limb, three with anarchic limb syndrome, and one showed signs of both. Pearson's Chi Squared test (χ^2) and unpaired Student's T-tests indicated no significant differences between the cohorts concerning gender, age, disease duration, and severity of clinical symptoms (Table 1). The study was approved by the local ethics committees (Leipzig:ID137-11-18042011). Participants were fully informed and gave written consent in accordance with the Declaration of Helsinki.

2.2. Data acquisition

T1-weighted structural brain images were acquired at each center using the magnetization-prepared rapid gradient-echo (MP-RAGE) sequence implemented on 3T scanners (Table e-2). Although scanner parameters slightly differ, an F-test in SPM12 (UCL, UK) revealed no significant influence.

2.3. Asymmetry correction in alien/anarchic limb syndrome patients

AL is seen in left and/or right limbs. The most severely affected limb for each subject was designated by clinical features at the time of scanning, but without considering the image. If necessary, images were flipped in the left-right dimension (Whitwell et al., 2010) such that the presumably affected hemisphere, contralateral to syndrome location, was positioned on the right side of the image in all AL patients. This allowed investigation of AL in the same hemisphere across subjects.

2.4. Voxel-based morphometry

Voxel-based morphometry was performed applying the CAT12 toolbox (University of Jena, Germany) with SPM12 (UCL, UK). Images were spatially normalized, segmented, modulated by the amount of non-linear deformation, and smoothed

with a Gaussian kernel of 8-mm full-width at half-maximum. Voxel-wise Student's T-tests were performed to compare, separately, the groups of patients with controls. Covariates were used to control for age, gender, and total intracranial volume. For the main comparison, clusters were detected using a voxel-threshold of $p < .001$ and a family-wise error (FWE) corrected cluster-threshold of $p < .05$. For exploratory analyses, clusters were detected applying an uncorrected voxel-threshold of $p < .001$.

The three patient cohorts (CBS, CBS-O, CBS-AL) were compared with healthy controls in whole-group comparisons. For exploratory pilot analyses, we split the CBS-AL cohort according to either alien ($N = 4$) or anarchic limb ($N = 3$) syndrome. Note that one patient was omitted given that he showed both syndromes (AL-16).

2.5. Support vector machine classification

Support vector machine classification allows the separation of data, by class, in a multidimensional space. We ran a support vector machine attempting to distinguish between CBS patients and controls as well as between CBS-AL and CBS-O using libSVM 3.18 (Chang & Lin, 2011). Classification accuracy was obtained by cross-validation using the "leave-one-subject-out" approach. Specificity and sensitivity were calculated by the number of correctly classified cases in each group. To investigate the reliability of the results the influence of several analysis parameters was inspected (e.g., linear/polynomial kernels). First, feature selection was based on SPM's gray matter tissue probability map, using different minimum gray matter probabilities ranging from 0 to 60% (Table e-5). The SPM map was also interpolated and smoothed with a Gaussian kernel of 8-mm full-width at half-maximum. Second, we used disease-specific regions-of-interest for feature selection. Regions-of-interest were selected according to our recent meta-analysis of CBS (Albrecht, Bisenius, Morales Schaack, Neumann, & Schroeter, 2017) as suggested previously (Bisenius et al., 2017; Meyer et al., 2017; Mueller et al., 2017) and generated using the WFU PickAtlas 3.0 (Lancaster, 1997).

Table 1 – Summarized subjects' demographic and clinical characteristics.

Cohort	Number	Female	Age (years)	Disease duration (years)	Clinical dementia rating score	Clinical dementia rating score-FTLD
Healthy controls	25	11	66.2 ± 10.1			
CBS	25	13	66.7 ± 10.1	3.7 ± 2.8	7.0 ± 4.2	8.4 ± 5.1
CBS-O	17	10	68.2 ± 5.4	4.1 ± 3.2	5.8 ± 3.9	7.1 ± 4.6
CBS-AL	8	3	63.4 ± 7.2	2.8 ± 1.6	9.0 ± 4.1	10.8 ± 5.4
<i>Statistical differences</i>						
Healthy controls versus CBS		$\chi^2 = .08, p = .8$	$t = .20, p = .84$			
Healthy controls versus CBS-O		$\chi^2 = .40, p = .5$	$t = .84, p = .41$			
Healthy controls versus CBS-AL		$\chi^2 = .25, p = .6$	$t = -.85, p = .40$			
CBS-O versus CBS-AL		$\chi^2 = 8.8^{e-32}, p = 1.0$	$t = -1.67, p = .12$	$t = -1.4, p = .18$	$t = 1.8, p = .09$	$t = 1.5, p = .15$
Mean ± standard deviation. Student's T-test was applied to compare numerical variables and χ^2 test to compare categorical variables across groups. CBS corticobasal syndrome, CBS-AL corticobasal syndrome with alien/anarchic limb syndrome, CBS-O corticobasal syndrome without alien limb syndrome, Clinical Dementia Rating Score-FTLD score modified for frontotemporal lobar degeneration.						

2.6. Data availability statement

Study protocol and statistical analysis plan will be shared at request. Data of participants are stored at the FTLD-Consortium. Patients' data are bound to maintain confidentiality and, accordingly, are only shared at reasonable request to replicate procedures and analysis of the study.

3. Results

3.1. Whole-group voxel-based morphometry

Fig. 1 and Table e-4 display gray matter volume differences between patients with CBS and healthy controls. In the left hemisphere reduced gray matter volume, for patients, was observed in inferior and middle occipital gyrus, medial temporal gyrus and temporoparietal junction, inferior/middle/superior frontal gyri, insula, and premotor and supplementary motor areas. On the right side, less gray matter was revealed in postcentral gyrus, supramarginal gyrus, inferior frontal gyrus, posterior and anterior insula, and supplementary motor area. Furthermore, right posterior cingulate gyrus, cuneus, and precuneus were affected.

Comparing CBS-O to controls revealed lower gray matter volume in superior temporal gyrus, medial temporal gyrus and temporoparietal junction, middle/inferior frontal gyrus, claustrum and putamen, posterior superior frontal sulcus and middle frontal gyrus/precentral gyrus; all on the left side. Less gray matter volume was also found bilaterally in the insula spreading to the superior temporal gyrus.

Contrasting CBS-AL and controls showed reduced gray matter volume in the posterior insula, superior temporal gyrus, and middle/superior frontal gyrus; all in the left

hemisphere. Lower gray matter volume was observed in the right precuneus, and cingulate gyrus spreading to fronto-medial cortex. Importantly, this included the supplementary motor area contralateral to the AL symptoms.

A direct comparison of CBS-AL and CBS-O did not reveal significant results, but may not have been a sufficiently powered analysis.

Contrasting CBS with alien limb syndrome to controls, lower gray matter volume was found in occipital pole, calcarine cortex, and inferior occipital gyrus; all on the left side (Figure e-1 and Table e-6). On the right side, superior/middle temporal gyrus including temporal pole, precentral/postcentral/supramarginal gyrus, and middle cingulate gyrus were implicated. Note that clusters in left occipital gyrus, right precentral/postcentral/supramarginal gyrus, and right superior/middle temporal gyrus were even apparent when correcting for multiple comparisons (see copper clusters in Figure e-1). The comparison of CBS with anarchic limb and controls showed less gray matter volume in superior parietal lobule/precuneus and parietal operculum/transverse temporal gyrus; all in the left hemisphere. In the right hemisphere, superior/middle/inferior occipital gyrus and posterior insula/putamen were compromised.

3.2. Support vector machine classification

The support vector machine classification could reliably identify CBS versus controls as well as CBS-AL versus CBS-O (Fig. 2 and Table e-5). Classification accuracies for the linear kernel were stable around 70–80%, independent of the gray matter mask. The highest accuracy of the classification of CBS patients and controls was 78.9% using a linear kernel and gray matter mask of .4. Regions contributing to correct classification mirrored areas identified in the univariate group comparison

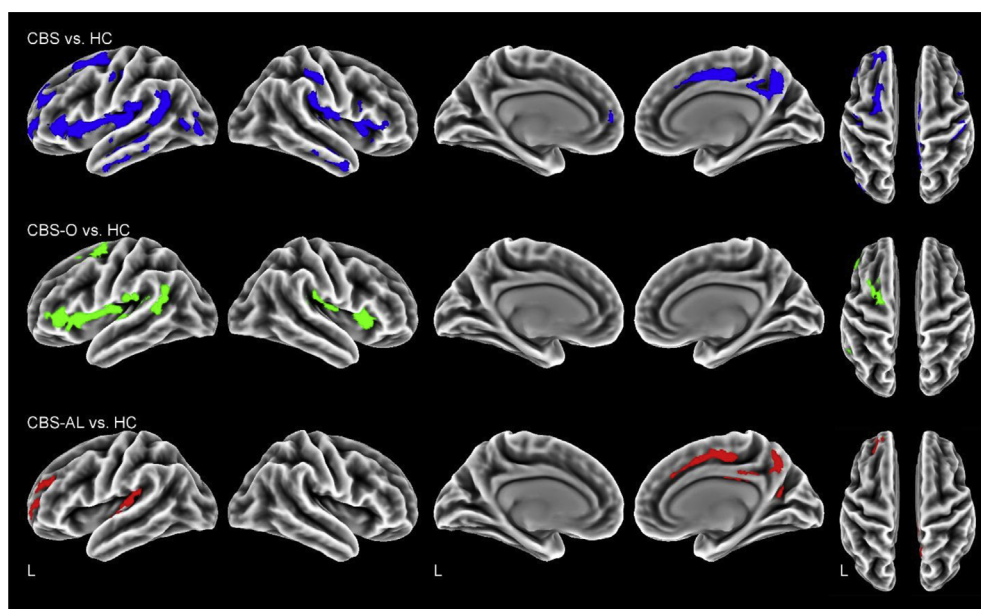


Fig. 1 – Reduced gray matter volume in each corticobasal syndrome (CBS) cohort compared with controls (HC). Clusters are corrected for multiple comparisons, $p < .05$ family-wise error rate (FWE). CBS whole patient cohort, CBS-AL CBS with alien/anarchic limb syndrome, CBS-O CBS without alien limb syndrome, L left.

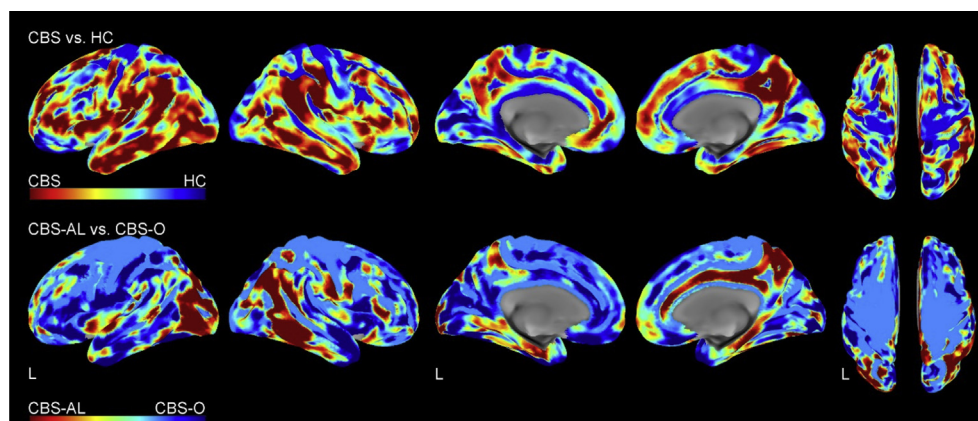


Fig. 2 – Weights of voxels most relevant for individual support vector machine classification between corticobasal syndrome (CBS) versus healthy controls (HC) and CBS with alien limb (CBS-AL) versus CBS without alien/anarchic limb (CBS-O). Note that these weights are relative and have no applicable units. Support vector machine classification was performed with a linear kernel on all voxels within the SPM's gray matter mask (tissue probability $>.4$, top row, tissue probability $>.5$, bottom row).

of the entire CBS group versus controls, as discussed above. Classifying CBS-AL versus CBS-O, resulted in an accuracy of 81.3% when applying a linear kernel and a gray matter mask of .5. Regions predictive of AL included, among others, the cingulate gyrus spreading to frontomedial cortex, postcentral gyrus, and temporoparietooccipital regions, at least partially overlapping with regions of thinner gray matter observed in the univariate comparison CBS-AL versus controls. Using the meta-analytically generated regions-of-interest masks did not improve the results.

4. Discussion

The complete group of CBS patients was characterized by apparent atrophy in frontotemporal and occipital regions, motor areas, and the insulae, in agreement with previous studies (Lee et al., 2011; Whitwell et al., 2010). To our knowledge, no prior study has systematically evaluated syndrome-specific atrophy in CBS with AL. Patients with AL showed apparent atrophy in the insula and frontotemporal gyri compared with healthy controls, and remarkably, also in the supplementary motor area and cingulate cortex contralateral to the symptomatic body side. This pattern was also evident in the entire CBS group although not when the CBS-O was compared with controls. This suggests the difference was driven by the CBS-AL patients.

4.1. Supplementary motor area is a neural correlate for alien/anarchic limb

Although CBS is mainly asymmetric it affects both body sides. Interestingly, AL is reportedly more often seen with left limbs, which would be consistent with neural correlates in the right hemisphere (Graff-Radford et al., 2013). It is speculated that the asymmetry of the functions of the hemispheres explains why certain variants of AL affect only left or right hand. For example Bartolo et al. (2011) report that the right

supplementary motor area is inhibiting both, right and left cortex, while the left supplementary motor area is not dominant and inhibits only contralateral, hence leading to right-sided AL. In Graff-Radford's large cohort, the left extremity was affected in 69% of AL cases. In our sample the prevalence was 50%. One should consider that Graff-Radford's review included cases with various diseases, not only CBS and did not differentiate between alien and anarchic limb phenomena. Their study identified the parietal lobe and its disconnection from other cortical areas as a common correlate for AL, which is in line with our CBS-AL comparison.

Interpreting neural correlates of alien and anarchic limb phenomena is often masked by the fact that in the literature both syndromes are confounded. Disentangling the anatomical counterparts of anarchic limb, studies have identified the supplementary motor area as a crucial brain structure (Frith, Blakemore, & Wolpert, 2000; Hassan & Josephs, 2016; Marchetti & Della Sala, 1998; Schaefer, Heinze, & Galazky, 2013). In line with those findings, our cohort suggests atrophy in the supplementary motor area. Thus, it is hypothesized that an impaired supplementary motor area is necessary for anarchic limb syndrome. The anterior region of the supplementary motor area is internally triggered and activated when movements are imagined and selected (Frith et al., 2000). To initiate the movement the supplementary motor area needs to be inhibited. The inhibition subsequently leads to activation of the primary motor cortex and initiates movement. Damage to this network by atrophy could lead to externally triggered, unintended, movements and disturbed selection of appropriate motor programs, as experienced by anarchic limb syndrome patients. Even visual stimuli of surroundings activate this circuit and motor programs (Sumner & Husain, 2008). Thus, the brain needs to weight several competing motor plans activated by objects in our proximity. Sumner and Husain (2008) summarized in their review that a network of medial frontal areas (including supplementary motor area) and parietal regions inhibit reflexive behavior and mediate competing

motor programs. Indeed, in patients with focal lesions in the supplementary motor area and supplementary eye field, automatic inhibition of subconscious motor activation is impaired, which correlated with the extent of the lesions (Sumner et al., 2007). Hence, automatic inhibition is crucial for flexible and volitional motor control in condition–action associations. Importantly for our results, a case study by McBride, Sumner, Jackson, Bajaj, and Husain (2013) observed disturbed automatic inhibition of primed reactions in the anarchic limb of a CBS patient. In the non-affected limb automatic inhibition remained preserved. This underlines that the hypothesis of automatic inhibition processes facilitating flexible and volitional behavior due to inhibiting unwanted motor plans, primed by surrounding objects, may account for the well-executed and purposeful anarchic limb movements. In the exploratory analyses however, we could not confirm atrophy in the supplementary motor area in anarchic limb syndrome, which may have been an insufficiently powered analysis since it only involved three patients.

Why the affected limb would be experienced as foreign in alien limb syndrome is not clear. One hypothesis is that disruption of parietal circuits leads to dysfunction in self-attribution (Sarva, Deik, & Severt, 2014). Thus, alien limb seems to arise due to a disturbed sense of ownership, but not disturbed sense of agency (Synofzik et al., 2008). Overall, the neural network processing body-ownership comprises the right temporo-parietal junction, right insula, inferior parietal cortex, and premotor cortex (Tsakiris, Longo, & Haggard, 2010). In line with that, Hassan and Josephs (2016) stated in their review that lesions in parietal lobe, i.e., posterior post-central gyrus, posterior primary sensory cortex, and tertiary somatosensory cortex, lead to alien limb syndrome. Notably, we also found these networks involved in the univariate group comparison of CBS-AL and controls as well as in the CBS-AL versus CBS-O classification results. Further, exploratory pilot analyses of the alien limb syndrome cohort confirmed putative atrophy in parietal cortex and postcentral gyrus.

4.2. The role of the cingulate cortex in alien/anarchic limb syndrome

In general, the cingulate cortex and especially its anterior part translates motor intentions into actions and mediates willed control, underlining the important role in motor actions and their cognitive control (Paus, 2001). Further, the anterior cingulate cortex is known for its dense projections from the motor cortex and spinal cord. In healthy conditions, the cingulate cortex implements the selection of actions as well as fights competing motor programs, a crucial part of volitional control.

Contrasting CBS-AL to controls, putative atrophy was also found in the right cingulate cortex, contralateral to the symptoms shown by the patients. In exploratory analyses, we could confirm volume loss in the cingulate cortex in the alien limb syndrome cohort but not in the anarchic limb syndrome cohort. Already, Goldberg, Mayer, and Togliola (1981) hypothesized that the two functional zones of the medial frontal gyrus, i.e., supplementary motor area and cingulate cortex, could be the reason for AL when implicated due to a lesion. Even at this time it was known that both regions are

connected reciprocally as Goldberg further reported. In an early study, Talairach et al. (1973) observed, when stimulating continuously the anterior cingulate cortex in epileptic patients, that they exhibited highly complex motor behavior even adapted to the environmental conditions. This finding already supports the hypothesis that the cingulate cortex plays an important role in high motor integration. Brugger, Galovic, Weder, and Kägi (2015) confirmed involvement of the cingulate cortex in disturbed self-initiated movements in anterior cerebral artery stroke patients with anarchic limb syndrome. The researchers underlined that the medial motor system is essential for volitional motor actions. In their study, they linked especially the pre-supplementary motor area to the signs of anarchic limb syndrome. Another case report of a patient with an ischemic lesion within the right cingulate motor area showed that this leads to anarchic limb-like involuntary movements of the left arm (Brázdil, Kuba, & Rektor, 2006). This provides a further hint that the cingulate cortex is involved in goal-directed motor behavior, their preparation as well as execution of those action programs.

4.3. Machine learning identifies corticobasal syndrome patients with and without alien/anarchic limb syndrome

The support vector machine analysis was able to distinguish between CBS and controls as well as CBS patients with and without AL, on a single-subject level. Remarkably, multivariate pattern recognition demonstrated much higher predictive power than the univariate group comparison (CBS-AL vs. CBS-O), which did not reveal any significant effects. Although, the putative atrophy in CBS/CBS-AL might be the main contributor to correct classification (if one compares Figs. 1 and 2). This suggests that support vector machine analysis might be applied in the future to support individual diagnosis and perhaps syndrome prediction. This discrepancy might be related to mathematics of the analyses. In voxel-based morphometry univariate relationships are detected voxel-wise across all participants. In support vector machine analysis, multivariate relationships are identified over the whole brain. A previous support vector machine analysis showed that progressive supranuclear palsy, another atypical parkinsonian syndrome, can be distinguished from controls achieving accuracies above 80% (Mueller et al., 2017).

4.4. Study's limitations

Our study identified consistent atrophy and enabled individual classification in CBS with and without AL, but there are also limitations. As our sample is not completely histopathologically validated one cannot draw conclusions concerning the pathology of CBS. It is possible that not all patients had underlying corticobasal degeneration (Armstrong et al., 2013). Our sample of AL patients is also rather small, thus the exploratory analyses to disentangle the neural correlates of AL subtypes should be interpreted with caution. However, as CBS and AL are regarded as orphan diseases, our multi-centric design allowed a reasonable number. Possible biases introduced by the multi-centric approach, including different scanner types/protocols, were minimized by applying strict standard operating procedures and including only 3T MRI. We

did not investigate white matter alterations in CBS patients, thus we cannot account for callosal lesions, which may have led to AL too.

5. Conclusion

This study presents the first MRI-based group analysis of alien and anarchic limb syndrome in CBS. Results may pave the way for individual clinical syndrome prediction, while allowing a better understanding of the underlying brain substrates and neurocognitive architecture.

Author contributions

Franziska Albrecht, study concept and design, analysis and interpretation of data, writing of manuscript.

Matthias L. Schroeter, study concept and design, data acquisition, analysis and interpretation of data, critical revision of manuscript, study supervision.

Karsten Mueller, Tommaso Ballarini, Leonie Lampe, Robert Jech, interpretation of data, critical revision of manuscript.

Adrian Danek, Janine Diehl-Schmid, Jan Kassubek, Bernhard Landwehrmeyer, Albert C. Ludolph, Markus Otto, study design, data acquisition, critical revision of manuscript.

Klaus Fassbender, Klaus Fliessbach, Holger Jahn, Johannes Kornhuber, Martin Lauer, Epameinondas Lyros, Johannes Prudlo, Anja Schneider, Matthias Synofzik, Jens Wiltfang, data acquisition, critical revision of manuscript.

Author disclosures

Franziska Albrecht, Tommaso Ballarini, Adrian Danek, Janine Diehl-Schmid, Klaus Fassbender, Klaus Fliessbach, Holger Jahn, Jan Kassubek, Johannes Kornhuber, Leonie Lampe, Bernhard Landwehrmeyer, Albert C. Ludolph, Martin Lauer, Epameinondas Lyros, Johannes Prudlo, Markus Otto, Karsten Mueller, Anja Schneider, Matthias L. Schroeter, Jens Wiltfang – Report no disclosures relevant to the manuscript.

Matthias Synofzik - Received consulting honoraria from Actelion Pharmaceuticals, unrelated to this study.

Robert Jech – Consultant to Ipsen, Cardion; Advisory Board of Ipsen.

Study funding

This study has been supported by the German Federal Ministry of Education and Research (BMBF) by a grant given to the German FTLD Consortium [grant number FKZ O1G11007A], by the Parkinson's Disease Foundation [grant number PDF-IRG-1307], by the Michael Fox Foundation [grant number 11362], by the German Research Foundation (DFG, SCHR 774/5-1), by the Else Kröner-Fresenius-Stiftung, by the International Max Planck Research School on Neuroscience of Communication: Function, Structure, and Plasticity (IMPRS NeuroCom) by the Max Planck Society, and by the Czech Science Foundation GAČR [grant number 16-13323S].

Acknowledgments

The authors thank all patients for participating in this study. We would like to thank Joshua Grant for proofreading and editing the manuscript for non-intellectual content.

Co-investigators

FTLD-Consortium: Sarah Anderl-Straub (Ulm), Katharina Brügger (Rostock), Marie Fischer (Erlangen), Hans Förstl (TU Muenchen), Anke Hammer (Erlangen), György Homola (Würzburg), Walter Just (Ulm), Johannes Levin (LMU München), Nicolai Marroquin (Ulm), Anke Marschhauser (Leipzig), Magdalena Nagl (Ulm), Timo Oberstein (Erlangen), Maryna Polyakova (Leipzig), Hannah Pellkofer (Göttingen), Tanja Richter-Schmidinger (Erlangen), Carola Rossmeier (TU München), Katharina Schuemberg (Leipzig), Elisa Semler (Ulm), Annika Spottke (Bonn), Petra Steinacker (Ulm), Angelika Thöne-Otto (Leipzig), Ingo Uttner (Ulm), and Heike Zech (Göttingen).

Supplementary data

Supplementary data to this article can be found online at <https://doi.org/10.1016/j.cortex.2019.02.015>.

REFERENCES

- Albrecht, F., Bisenius, S., Morales Schaack, R., Neumann, J., & Schroeter, M. L. (2017). Disentangling the neural correlates of corticobasal syndrome and corticobasal degeneration with systematic and quantitative ALE meta-analyses. *NPJ Parkinson's Disease*, 3(1), 12. <https://doi.org/10.1038/s41531-017-0012-6>.
- Armstrong, M. J., Litvan, I., Lang, A. E., Bak, T. H., Bhatia, K. P., Borroni, B., & Weiner, W. J. (2013). Criteria for the diagnosis of corticobasal degeneration. *Neurology*, 80(5), 496–503. <https://doi.org/10.1212/WNL.0b013e31827f0fd1>.
- Bartolo, M., Zucchella, C., Pichiecchio, A., Pucci, E., Sandrini, G., & Sinforiani, E. (2011). Alien hand syndrome in left posterior stroke [journal article] *Neurological Sciences*, 32(3), 483–486. <https://doi.org/10.1007/s10072-011-0490-y>.
- Bisenius, S., Mueller, K., Diehl-Schmid, J., Fassbender, K., Grimmer, T., Jessen, F., & group, F. T. s. (2017). Predicting primary progressive aphasia with support vector machine approaches in structural MRI data. *Neuroimage Clinical*, 14, 334–343. <https://doi.org/10.1016/j.nicl.2017.02.003>.
- Brázdil, M., Kuba, R., & Rektor, I. (2006). Rostral cingulate motor area and paroxysmal alien hand syndrome. *Journal of Neurology, Neurosurgery & Psychiatry*, 77(8), 992–993. <https://doi.org/10.1136/jnnp.2005.082529>.
- Brion, S. (1972). Troubles du transfert interhemispherique. A Propos de trios observations de tumeurs du corps calleux. Le signe de la main etrangere. *Revista de Neurologia*, 126, 257–266.
- Brugger, F., Galovic, M., Weder, B. J., & Kägi, G. (2015). Supplementary Motor complex and disturbed motor control – a retrospective clinical and lesion analysis of patients after anterior cerebral artery stroke. [original research]. *Frontiers in Neurology*, 6(209). <https://doi.org/10.3389/fneur.2015.00209>.

- Chang, C.-C., & Lin, C.-J. (2011). LIBSVM: a library for support vector machines. *ACM Transactions on Intelligent Systems and Technology (TIST)*, 2(3), 27.
- Della Sala, S., Marchetti, C., & Spinnler, H. (1991). Right-sided anarchic (alien) hand: a longitudinal study. *Neuropsychologia*, 29(11), 1113–1127.
- Frith, C. D., Blakemore, S.-J., & Wolpert, D. M. (2000). Abnormalities in the awareness and control of action. *Philosophical Transactions of the Royal Society of London. Series B: Biological Sciences*, 355(1404), 1771–1788. <https://doi.org/10.1098/rstb.2000.0734>.
- Goldberg, G., Mayer, N. H., & Togli, J. U. (1981). Medial frontal cortex infarction and the alien hand sign. *Archives of Neurology*, 38(11), 683–686.
- Graff-Radford, J., Rubin, M. N., Jones, D. T., Aksamit, A. J., Ahlskog, J. E., Knopman, D. S., & Josephs, K. A. (2013). The alien limb phenomenon. *Journal of Neurology*, 260(7), 1880–1888. <https://doi.org/10.1007/s00415-013-6898-y>.
- Hassan, A., & Josephs, K. A. (2016). Alien hand syndrome. *Current Neurology and Neuroscience Reports*, 16(8), 73. <https://doi.org/10.1007/s11910-016-0676-z>.
- Lancaster, J. (1997). The Talairach Daemon, a database server for Talairach atlas labels. *Neuroimage*, 5, S633.
- Lee, S. E., Rabinovici, G. D., Mayo, M. C., Wilson, S. M., Seeley, W. W., DeArmond, S. J., & Miller, B. L. (2011). Clinicopathological correlations in corticobasal degeneration. *Annals of Neurology*, 70(2), 327–340. <https://doi.org/10.1002/ana.22424>.
- Marchetti, C., & Della Sala, S. (1998). Disentangling the alien and anarchic hand. *Cognitive Neuropsychiatry*, 3(3), 191–207. <https://doi.org/10.1080/135468098396143>.
- McBride, J., Sumner, P., Jackson, S. R., Bajaj, N., & Husain, M. (2013). Exaggerated object affordance and absent automatic inhibition in alien hand syndrome. *Cortex*, 49(8), 2040–2054. <https://doi.org/10.1016/j.cortex.2013.01.004>.
- Meyer, S., Mueller, K., Stuke, K., Bisenius, S., Diehl-Schmid, J., Jessen, F., & Group, F. T. S. (2017). Predicting behavioral variant frontotemporal dementia with pattern classification in multi-center structural MRI data. *Neuroimage Clinical*, 14, 656–662. <https://doi.org/10.1016/j.nicl.2017.02.001>.
- Mueller, K., Jech, R., Bonnet, C., Tintera, J., Hanuska, J., Moller, H. E., & Group, F. T. S. (2017). Disease-specific regions outperform whole-brain approaches in identifying progressive supranuclear palsy: A multicentric MRI study. *Front Neurosci*, 11, 100. <https://doi.org/10.3389/fnins.2017.00100>.
- Otto, M., Ludolph, A. C., Landwehrmeyer, B., Förstl, H., Diehl-Schmid, J., Neumann, M., & Danek, A. (2011). Konsortium zur Erforschung der frontotemporalen Lobärdegeneration [journal article] *Der Nervenarzt*, 82(8), 1002. <https://doi.org/10.1007/s00115-011-3261-3>.
- Paus, T. (2001). Primate anterior cingulate cortex: where motor control, drive and cognition interface. *Nature Reviews Neuroscience*, 2(6), 417.
- Sarva, H., Deik, A., & Severt, W. L. (2014). Pathophysiology and treatment of alien hand syndrome. *Tremor Other Hyperkinet Movements (New York, N.Y.)*, 4, 241. <https://doi.org/10.7916/D8VX0F48>.
- Schaefer, M., Heinze, H. J., & Galazky, I. (2013). Waking up the alien hand: rubber hand illusion interacts with alien hand syndrome. *Neurocase*, 19(4), 371–376. <https://doi.org/10.1080/13554794.2012.667132>.
- Sumner, P., & Husain, M. (2008). At the edge of consciousness: Automatic motor activation and voluntary control. *Neuroscientist*, 14(5), 474–486. <https://doi.org/10.1177/1073858408314435>.
- Sumner, P., Nachev, P., Morris, P., Peters, A. M., Jackson, S. R., Kennard, C., et al. (2007). Human medial frontal cortex mediates unconscious inhibition of voluntary action. *Neuron*, 54(5), 697–711. <https://doi.org/10.1016/j.neuron.2007.05.016>.
- Synofzik, M., Vosgerau, G., & Newen, A. (2008). I move, therefore I am: a new theoretical framework to investigate agency and ownership. *Consciousness and Cognition*, 17(2), 411–424. <https://doi.org/10.1016/j.concog.2008.03.008>.
- Talairach, J., Bancaud, J., Geier, S., Bordas-Ferrer, M., Bonis, A., Szikla, G., et al. (1973). The cingulate gyrus and human behaviour. *Electroencephalography and Clinical Neurophysiology*, 34(1), 45–52. [https://doi.org/10.1016/0013-4694\(73\)90149-1](https://doi.org/10.1016/0013-4694(73)90149-1).
- Tsakiris, M., Longo, M. R., & Haggard, P. (2010). Having a body versus moving your body: neural signatures of agency and body-ownership. *Neuropsychologia*, 48(9), 2740–2749.
- Whitwell, J. L., Jack, C. R., Jr., Boeve, B. F., Parisi, J. E., Ahlskog, J. E., Drubach, D. A., & Josephs, K. A. (2010). Imaging correlates of pathology in corticobasal syndrome. *Neurology*, 75(21), 1879–1887. <https://doi.org/10.1212/WNL.0b013e3181feb2e8>.