

Technical Note

Artifacts caused by transcranial magnetic stimulation coils and EEG electrodes in T_2^* -weighted echo-planar imaging

J. Baudewig^{a,b}, W. Paulus^b, J. Frahm^{a,*}

^aBiomedizinische NMR Forschungs GmbH am Max-Planck-Institut für biophysikalische Chemie, D-37070 Göttingen, Germany

^bAbteilung für Klinische Neurophysiologie, Georg-August-Universität, D-37073 Göttingen, Germany

Received 15 November 1999; accepted 11 January 2000

Abstract

We investigated the effects of transcranial magnetic stimulation (TMS) coils and electroencephalographic (EEG) electrodes on T_2^* -weighted echo-planar images (EPI) at 2.0 T (gradient-echo EPI, mean TE = 53 ms, $2 \times 2 \times 4$ mm³). In comparison with anatomic gradient-echo images (3D FLASH, TE = 4 ms, $1 \times 1 \times 1$ mm³), T_2^* -weighted EPI acquisitions of a water-filled spherical phantom revealed severe signal losses and geometric distortions in the vicinity of TMS coils. Even remote effects were observed for image orientations perpendicular to the coil plane. EEG electrodes and the fixation gel caused milder localized distortions. In humans, complications were avoided by the large distance between the TMS coil and the cortical surface and when using an EPI orientation parallel to the plane of the coil. It is concluded that T_2^* -weighted EPI studies of human brain function may be performed without distortions caused by TMS coils and EEG electrodes. © 2000 Elsevier Science Inc. All rights reserved.

Keywords: Human brain; Artifacts; Transcranial magnetic stimulation; EEG electrodes

1. Introduction

Basic research in magnetic resonance imaging (MRI) of human brain function as well as foreseeable clinical applications attempt to expand the MRI capabilities by a combination with transcranial magnetic stimulation (TMS) and electroencephalographic (EEG) recordings [1–4]. Potential usages comprise the monitoring of electrophysiologic activity in parallel to dynamic imaging of blood oxygenation level dependent (BOLD) contrast, e.g., in epilepsy patients, a BOLD MRI assessment of TMS-induced neuronal activity, and functional imaging of TMS-related brain plasticity, e.g., during motor learning or rehabilitation.

Technically, the actual use of TMS and EEG may be arranged in an interleaved MRI acquisition mode so that problems due to induced currents are avoided. Nevertheless, pertinent combinations are potentially hampered by impaired image quality originating from static magnetic field inhomogeneities in the vicinity of TMS coils or EEG elec-

trodes. Such phenomena also occur for ‘MR-compatible’ materials [5,6] because functional MRI recordings are commonly based on strongly T_2^* -weighted, i.e., susceptibility-sensitized, gradient-echo sequences such as long-TE FLASH, EPI, or spiral imaging.

The purpose of the present study was to investigate the distortions in T_2^* -weighted EPI of phantoms and humans that are introduced by nonferromagnetic TMS coils and commercially available EEG electrodes.

2. Materials and methods

All studies were conducted at 2.0 T (Siemens Vision, Erlangen, Germany) using the standard imaging headcoil. We tested two differently sized TMS coils of figure-eight shape with a long axis of 166 mm and a diameter of 86 mm (Dantec Medical A/S, Skovlunde, Denmark) and a long axis of 190 mm and a diameter of 100 mm (Magstim, Carmarthen, Wales, UK). Both coils were especially designed for MR experiments using nonmagnetic materials and are not yet commercially available. To allow for remote switching in future MRI studies of TMS applications, the

* Corresponding author. Tel.: +49-551-201-1721; fax: +49-551-201-1307.

E-mail address: jfrahm@gwdg.de (J. Frahm).

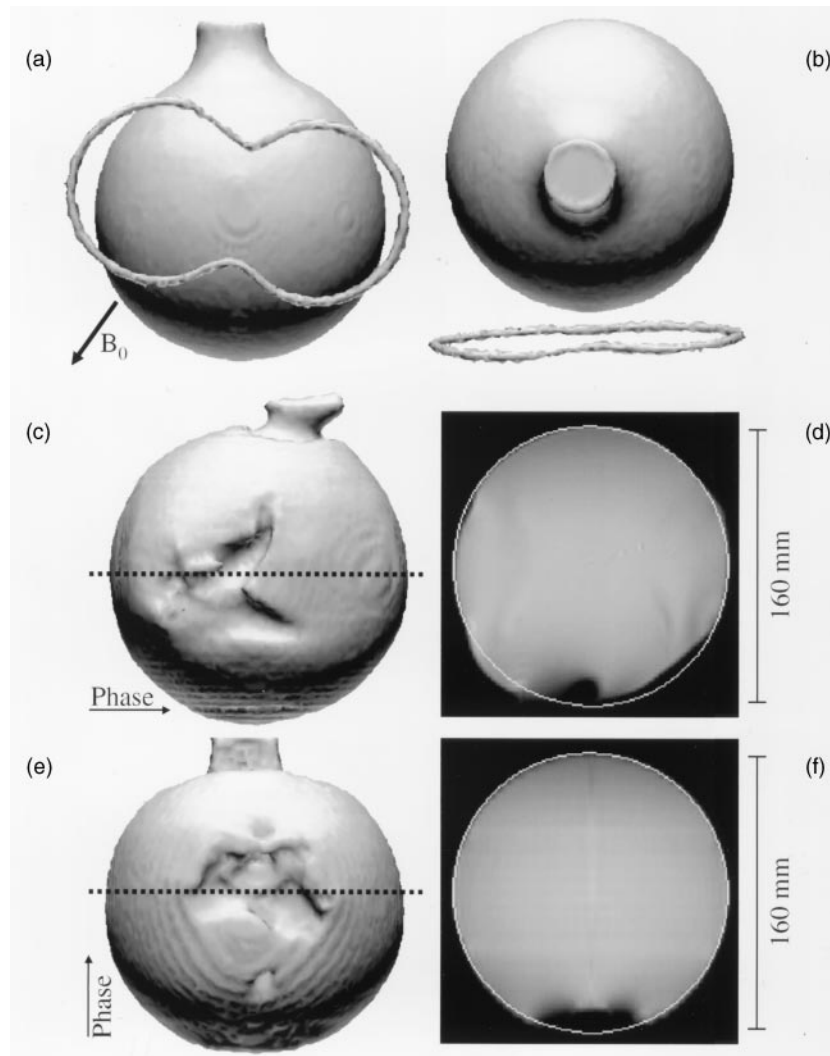


Fig. 1. (a) and (b), frontal and top views of 3D surface reconstructions of a spherical water phantom in the presence of a 166 mm long TMS coil. The images were acquired using 3D FLASH ($TE = 4$ ms, $1.0 \times 1.0 \times 1.0$ mm³ resolution). The figure-eight TMS coil is indicated by an attached water-filled tube. The arrow for B_0 indicates the direction of the static magnetic field; (c) Frontal view of a 3D surface reconstruction of contiguous T_2^* -weighted EPI scans ($TE = 53$ ms, $2.0 \times 2.0 \times 4.0$ mm³ resolution) with an orientation perpendicular to the plane of the TMS coil. The arrow for Phase indicates the orientation of the phase-encoding gradient. The broken line refers to the location of the cross-sectional image shown in (d). The circle in d represents the true structure as obtained by 3D FLASH in (a) and (b). In (e) and (f), same as (c) and (d) except for an EPI orientation parallel to the coil (i.e., in the plane of this page).

cable lengths were adjusted to about 8 m. To identify their location in MR images the TMS coils were surrounded by a water-filled plastic tube attached to their outer surface. The investigated EEG electrodes were taken from a commercially available MR-compatible EEG system (Schwarzer, München, Germany). The Ag/AgCl electrodes and screened cables were fixed using a conventional adhesive electrode gel (Nihon Kohden, Japan).

For studies of a water-filled spherical glass container (diameter 160 mm) the TMS coils were mounted inside the head coil and closely attached to the phantom without any spatial displacement. To assess EEG effects we separately investigated the fixation gel and the electrodes. Small portions of the gel were placed on the glass surface, whereas EEG electrodes were fixed with an adhesive tape. For hu-

man studies informed written consent was obtained before all examinations. The TMS coils were mounted as close as possible to the subjects' vertex. EEG electrodes were fixed with the electrode gel in standard positions.

Both phantoms and humans were imaged with use of a short-TE 3D FLASH sequence ($TR/TE = 15/4$ ms, flip angle 20° , 1 mm isotropic resolution) and a T_2^* -weighted single-shot, blipped gradient-echo EPI sequence (mean $TE = 53$ ms, $TR = 2000$ ms, flip angle 70° , frequency-selective fat suppression, 2.0×2.0 mm² resolution, 4 mm section thickness). In either case, contiguous images covered the entire phantom or brain. In addition to an evaluation of cross-sectional images the visual inspection of induced distortions was facilitated by 3D surface reconstructions (top, frontal, or side views) of the water phantom

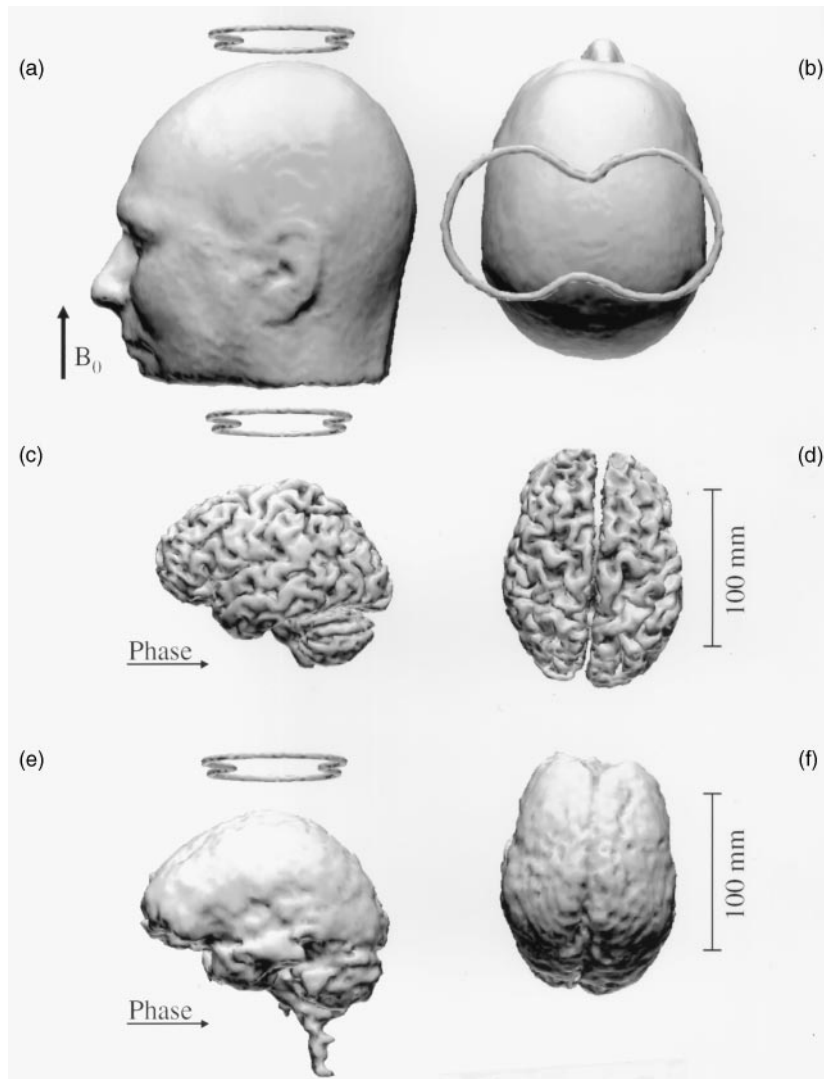


Fig. 2. Side and top views of 3D surface reconstructions of a subject with a 166 mm long TMS coil placed on the vertex. In (a) and (b), head surface and (c) and (d) cortical surface from 3D FLASH, and (e) and (f) brain surface from T_2^* -weighted EPI with a transverse orientation parallel to the TMS coil. For other parameters, see Fig. 1.

as well as of the subjects' head and brain. They were obtained with use of CURRY (NeuroScan, Herndon, VA, USA).

3. Results and discussion

3.1. TMS coils

As demonstrated by the frontal and top view in Figs. 1a and 1b high-resolution short-TE gradient-echo images of the water phantom revealed no distortions in the presence of the 166 mm long TMS coil. The position of the coil relative to the inner water volume is indicated by the "figure eight"-shaped structure representing the water tube attached to the coil surface. The resulting 3D images are identical to those acquired in the absence of a coil (not shown).

In contrast, significant distortions are seen in T_2^* -weighted echo-planar images. For EPI acquisitions perpendicular to the coil plane as shown in Figs. 1c and 1d, the images are not only affected by regional signal loss in areas near to the coil but also show contortions at rather far distances. Whereas marked signal losses are directly seen in the frontal view (Fig. 1c), geometric distortions are better appreciated in cross-sectional images (Fig. 1d). In comparison with 3D MR images (Fig. 1a), the EPI scan from a central section of the phantom reveals considerable deviations from a circular shape. Distortions may lead to protrusions or deflections with respect to the true structure and reach as far as 140 mm from the center of the coil. As indicated in Figs. 1e and 1f, these effects are much less pronounced in EPI sections acquired parallel to the TMS coil. Pertinent acquisitions yielded a local signal loss in regions as deep as 25 mm from the coil plane as the

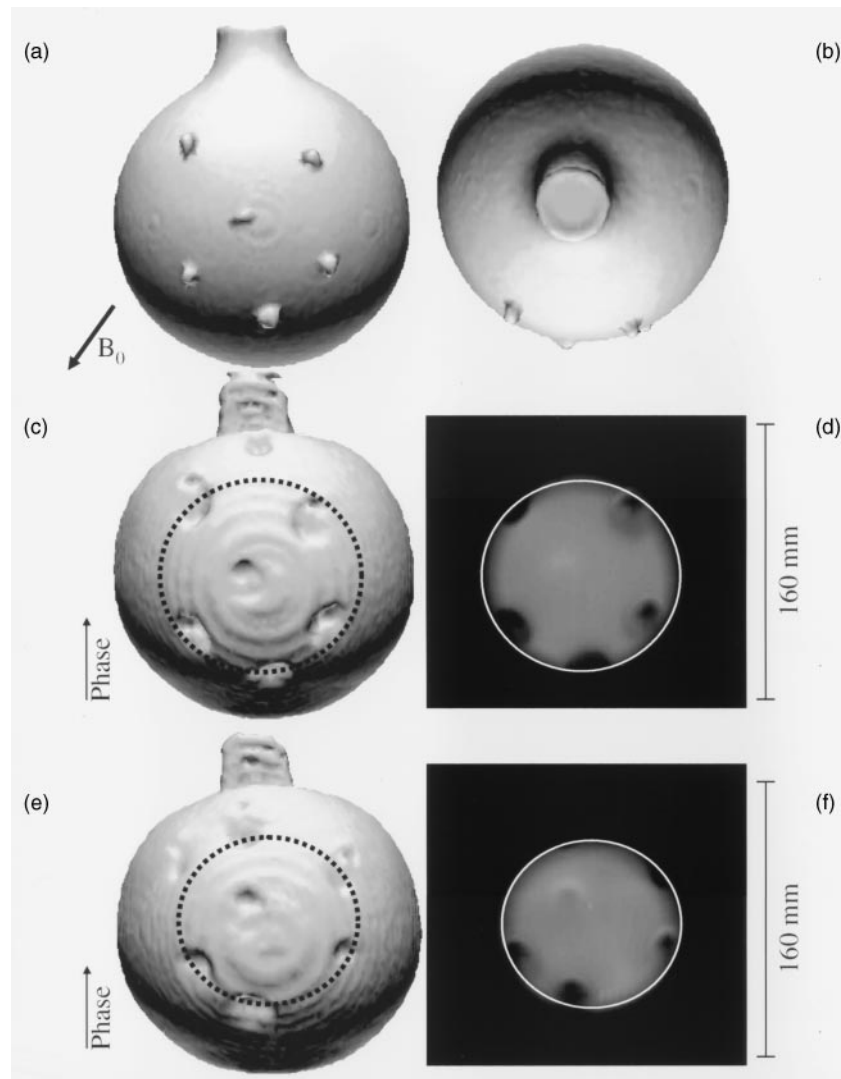


Fig. 3. In (a) and (b), frontal and top views of 3D surface reconstructions of a spherical water phantom with electrode gel from 3D FLASH. In (c), frontal view of a spherical water phantom with electrode gel from T_2^* -weighted EPI with an orientation parallel to the plane of this page; (d) Selected EPI scan of c for a section affected by multiple gel spots; (e,f) Same as c and d except for the use of EEG electrodes fixed with adhesive tape (i.e., no electrode gel). For other parameters, see Fig. 1.

predominant artifact. The lateral extensions were about 80 mm. In all cases, the distortions for the only slightly larger 190 mm long TMS coil roughly increased in proportion with the size of the coil.

A possible interpretation of the aforementioned observations stems from the different influences of the induced magnetic field inhomogeneities on the three imaging gradients. For a parallel acquisition only the slice selection gradient crosses the plane of the TMS coil. Accordingly, the image may be affected by signal losses due to incomplete refocusing of excited transverse magnetizations but does not result in geometric distortions in the image plane. Conversely, perpendicular orientations lead to a direct inhomogeneity effect either onto the blipped phase-encoding gradient or the alternating frequency-encoding gradient. The corresponding affection of the k space data may then become translated into distortions in various locations of the

resulting Fourier image. Different sensitivities of the EPI phase- and frequency-encoding gradients may explain the asymmetry of the major artifact seen in Fig. 1c, whereas the signal loss in Fig. 1f seems to reflect a rather symmetric (and exclusive) influence on the slice selection gradient.

Fig. 2 presents related data for a human subject using the same TMS coil placed on the vertex. Again, the 3D anatomic gradient-echo images show neither an influence of the TMS coil on the head surface (Figs. 2a,b) nor on the cortical surface (Fig. 2, c and d). Based on the experience of the phantom study, EPI was performed in a transverse orientation, i.e., parallel to the plane of the TMS coil. As demonstrated in Fig. 2, e and f, the side and top views of corresponding brain surface reconstructions (mainly reflecting liquor in contrast to gray matter in Fig. 2, c and d) reveal no visible artifacts. Apart from a proper EPI/TMS orientation, part of this fortunate result must be ascribed to the effective

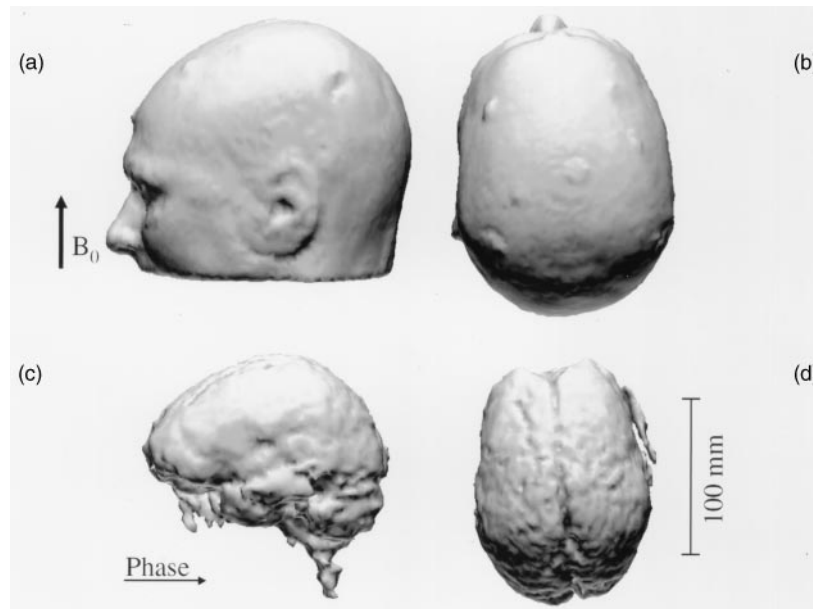


Fig. 4. Side and top views of 3D surface reconstructions of a subject with gel-fixed EEG electrodes. In (a) and (b), head surface from 3D FLASH, and (c) and (d), brain surface from T_2^* -weighted EPI in a transverse orientation. For other parameters, see Fig. 1.

distance between the coil and the brain surface. In the shown subject with the coil positioned at the vertex, the distance was about 28 mm (compare Fig. 2c) and thus slightly larger than the 25 mm zone affected in Fig. 1f.

3.2. EEG electrodes

The effects of fixation gel and EEG electrodes are separately demonstrated in Fig. 3. Using anatomic gradient-echo images the locations of the fixation gel are easily identifiable by bright spots that reflect their intrinsic water proton spins with relatively short T_1 relaxation times (Fig. 3, a and b). In T_2^* -weighted EPI the electrode gel caused an opposite effect. As shown in the frontal view (Fig. 3c) as well as in a corresponding cross-sectional image (Fig. 3d), the presence of the gel resulted in an inhomogeneity-induced signal dephasing in EPI beyond the actual size of the applied gel (compare Fig. 3a). The signal loss reached a depth of about 15–20 mm from the gel and lateral extensions of up to 25 mm. The EEG electrodes were not visible in anatomic images when fixed with adhesive tape to the phantom. Figs. 3e and 3f reveal signal losses in EPI that are caused by susceptibility differences from the electrodes alone. They are comparable to the artifacts from the electrode gel.

Fig. 4 depicts the results of a human subject with gel-fixed EEG electrodes in standard positions. The findings are in agreement with what might be expected from the preceding phantom and human studies, i.e., Figs. 2 and 3. Whereas anatomic gradient-echo images identify the location of the electrodes by exploiting the signal from the fixation gel (Fig. 4, a and b), the combined signal losses from the gel and the electrodes in transverse T_2^* -weighted EPI did not

extend to the cortex, and therefore yielded unaffected 3D reconstructions of the brain surface (Fig. 4, c and d).

4. Conclusion

Nonferromagnetic TMS coils may cause severe artifacts in T_2^* -weighted gradient-echo images such as in long-TE EPI scans commonly employed for functional neuroimaging. This particularly holds true for image orientations crossing the plane of the TMS coil. Also, EEG electrodes and fixation gels may impair T_2^* -weighted images. Pertinent signal losses are localized though larger than the size of the electrodes.

The observed effects in phantoms are much less pronounced in applications to humans. This is mainly because the head surface is typically about 15–25 mm atop the cortical surface, so that the examined brain regions may be free from artifactual signal losses and/or geometric distortions. It may therefore be concluded that most MRI studies of brain function are unlikely to be hampered by susceptibility artifacts from interleaved TMS applications or EEG recordings. However, parallel orientations of EPI acquisitions and TMS coils planes are recommended and specific care should be taken in cases where TMS studies require an oblique coil orientation relative to EPI.

References

- [1] Bohning DE, Pecheny AP, Epstein CM, Speer AM, Vincent DJ, Dannels W, George MS. Mapping transcranial magnetic stimulation (TMS) fields in vivo with MRI. *NeuroReport* 1997;8:2535–8.

- [2] Bohning DE, Shastri A, McConnell KA, Nahas Z, Lorberbaum JP, Roberts DR, Teneback C, Vincent DJ, George MS. A combined TMS/fMRI study of intensity-dependent TMS over motor cortex. *Biol Psychiatry* 1999;45:385–94.
- [3] Ives JR, Warach S, Schmitt F, Edelmann RR, Schomer DL. Monitoring the patient's EEG during echo planar MRI. *Electroencephalog Clin Neurophysiol* 1993;87:417–20.
- [4] Lemieux L, Allen PJ, Franconi F, Symms MR, Fish DR. Recording of EEG during fMRI experiments: patient safety. *Magn Reson Med* 1997;38:943–52.
- [5] Krakow K, Allen PJ, Symms MR, Lemieux L, Fish DR. The effect of EEG recording on functional MR image quality. In: *Book of Abstracts: Seventh Annual Meeting of the International Society for Magnetic Resonance in Medicine*. Philadelphia: ISMRM; 1999. p. 1698.
- [6] Chen Q, Keenan J, Ives J, Kauffman T, Edelman R, Schlaug G, Pascual-Leone A. Technical problems and safety of applying transcranial magnetic stimulation within the MRI environment. In: *Book of Abstracts: Fifth International Conference on Functional Mapping of the Human Brain*, Düsseldorf, Germany: HBM, 1999. p. 224.