

# Impaired hemodynamics and neural activation?

## A fMRI study of major cerebral artery stenosis

M. Hund-Georgiadis, MD; T. Mildner, PhD; D. Georgiadis, MD, PhD; K. Weih, PhD; and D.Y. von Cramon, MD, PhD

**Abstract**—Functional MRI motor mapping was performed in two women with unilateral high-grade stenosis of the middle cerebral artery (MCA) to determine the influence of impaired hemodynamics on the blood oxygenation level dependent (BOLD) response. In both patients no structural lesions were present in primary motor pathways. A redistribution of the motor network to the healthy hemisphere was the main indicator of chronic hemodynamic compromise.

NEUROLOGY 2003;61:1276–1279

Patients with severe cerebral arterial stenosis often exhibit only mild persisting neurologic impairment in spite of a decreased hemodynamic reserve (“misery-perfusion syndrome”).<sup>1</sup> Discrete structural damage on morphologic MRI often coincides with wider areas of hemodynamic compromise as assessed by PET.<sup>2</sup>

Functional mapping with fMRI or PET is based on the tight coupling between regional blood flow and local metabolic demand, thereby indirectly depicting regional neuronal activity. Little is known about this dynamic linkage in patients with impaired hemodynamics. Previous research provided evidence for changes of neural activity, which correlated with the severity of hemodynamic impairment in the somatosensory system: a graded reduction of the initial somatosensory evoked field component (N20) and an augmentation of the second field component (N30) as a compensatory mechanism were described.<sup>3</sup> The existence of a neuronal reserve mechanism, supplementing hemodynamic reserve strategies in an attempt to maintain neuronal function, thus appears probable. The current study assessed the influence of impaired hemodynamics on the fMRI blood oxygenation level dependent (BOLD) signal changes and their relation to neural activation of the involved functional network in both hemispheres.

**Methods.** *Case reports.* Patient 1. A 38-year-old strongly right-handed woman had a transient facial numbness and paresis mostly involving the lip muscles. Three-dimensional structural MR imaging revealed a small T1-hypointense lesion in the supralenticular white matter adjacent to the right inferior parietal lobule.

Patient 2. A 34-year-old right-handed woman repeatedly experienced several short episodes of speech arrest, lasting for about 20 seconds. Structural MR imaging showed a small inhomoge-

neous lesion in the territory of the left A. sulci precentralis. The motor cortices were structurally intact.

Neurologic examination had normal results in both patients at the time of the MR session, performed 14 and 20 months after symptom onset in Patients 1 and 2.

Full right-handedness was assessed based on the Edinburgh Handedness Inventory (EHI) in both patients with a score of 100% (range  $\pm$  100%). MR examinations included morphologic imaging, functional motor mapping, MR angiography, and a brain perfusion study in both patients. Six healthy right-handed controls—four women, two men (mean age  $35.8 \pm 6.2$  years/EHI: 100%)—underwent structural and functional MR imaging. All subjects gave their informed consent to participate in this study, which was approved by the local ethics committee.

*fMRI. Motor mapping.* A paced finger tapping task (2 Hz) was performed in response to a red and green visual stimulus using a blocked design.<sup>4</sup> Right, left, and bimanual finger tapping were recorded and monitored online in three different scans against a resting baseline. A training test determined the patient’s ability to solve the task prior to the functional session. No mirror movements occurred in patients and controls. The experiments were carried out on a 3T scanner (Medspec 30/100, Bruker, Ettlingen, Germany). Sixteen axial slices (19.2 cm field of view, 64 by 64 matrix, 5 mm thickness, 2 mm spacing) parallel to the AC-PC plane were acquired using a single shot, gradient recalled echoplanar imaging (EPI) sequence (echo time [TE] = 30 msec, repetition time [TR] = 2 sec, 90° flip angle).

Perfusion images were obtained by dynamic first-pass bolus tracking of Gd-DTPA with a gradient echo EPI sequence (TR/TE 1000/30). The contrast agent bolus (0.1 mmol/kg) was administered at a rate of 5 mL/sec by a power injector. Concentration time curves were processed to determine maximum peak (MP), mean transit time (MTT), and time-to-peak (TTP) maps following a pragmatic approach in the absence of arterial input function curves.<sup>5</sup>

Data analysis was performed with the LIPSIA software package,<sup>6</sup> which implements the statistical routines of SPM. Statistical parametric maps were thresholded at  $p < 0.001$  (uncorrected) at the voxel level. In order to reduce the probability of accepting false positives, only clusters of significant size ( $p < 0.025$ , corrected for multiple comparisons, as determined using the theory of Gaussian random fields<sup>7</sup>) were considered for further analysis. Based on these thresholds motor activation vs resting baseline was separately assessed for each patient and the controls in a first step. In a second step a SPM analysis was performed contrasting the motor activation states of each patient against the corresponding

From Max-Planck-Institute of Cognitive Neuroscience (Drs. Hund-Georgiadis, Mildner, Weih, and von Cramon), Leipzig, Germany; and Department of Neurology (Dr. Georgiadis), University of Zürich, Switzerland.

Received October 18, 2002. Accepted in final form July 29, 2003.

Address correspondence and reprint requests to Dr. Margret Hund-Georgiadis, Max-Planck-Institute of Cognitive Neuroscience, Stephanstr. 1b, 04103 Leipzig, Germany; e-mail: hund@cns.mpg.de

1276 Copyright © 2003 by AAN Enterprises, Inc.

activation in the control group. Significant differences in activation patterns of individual patients and controls were also assessed based on a time course analysis of averaged activation clusters in the primary motor cortices. Lateralization indices (LI) were calculated based on significantly activated voxels for each hemisphere and each condition ( $LI = nPl - nPr/nPl + nPr$ , range  $\pm 1$ ). Positive indices indicate a left, and negative a right hemisphere dominance for the motor activation.

**Results.** *MR angiography and MR perfusion.* MR angiography with Gd-DTPA revealed severe stenosis of the M1 segment of the MCA in both patients (Patient 1: right proximal MCA trunc with reduced filling in the A. sulci centralis and postcentralis; Patient 2: left distal MCA trunc without obvious filling deficits, figure 1).

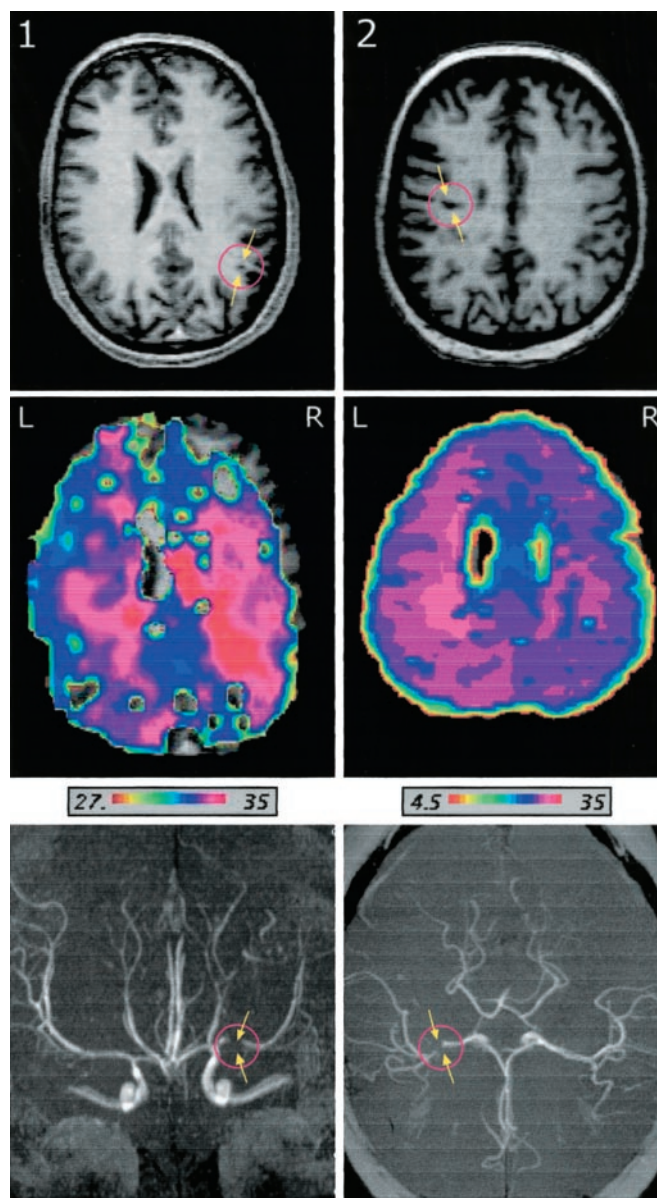
An impairment of cerebral hemodynamics, restricted to the side of the MCA stenosis, was diagnosed in both patients on the MR perfusion study. TTP-map showed a mean delay of the gadolinium enhanced MR signal of 4.3 seconds in the right primary motor cortices (M1) area in Patient 1 (TTP right vs left: 34.5 vs 30.2 sec), and of 4.9 seconds in the left M1 area (27.2 vs 32.1 sec) in Patient 2 (see figure 1). Interhemispheric differences were also found in MTT (right vs left: 4.2 vs 5.9 sec and 6.3 vs 4.8 sec in Patients 1 and 2), but not in MP maps (MP right vs left: 0.41 vs 0.44 in Patient 1 and 0.38 vs 0.35 in Patient 2).

*fMRI.* Unilateral finger tapping was associated with a strong activation of the contralateral M1 in the control group. Cerebellar activation in response to unilateral finger tapping was strongly ipsilateral to the tapping hand. Bilateral finger tapping recruited additionally the supplementary motor area (SMA) (figure 2).

The statistical comparison of the various motor conditions of patients vs controls yielded significantly different patterns in both patients, when the hand contralateral to the stenosis performed the tapping task. Both patients showed a significantly stronger recruitment of additional ipsilateral M1, premotor cortex, and SMA, which was not found in the controls. Bilateral finger tapping was also associated with additional SMA and bilateral premotor cortex activation as compared to the controls. The overall contributions of the primary motor cortices in the hypoperfused hemisphere were smaller ( $p = 0.02$ ) as compared to the unaffected hemisphere during finger tapping in both patients. Cerebellar activation in response to unilateral finger tapping was strongly ipsilateral to the moving hand and did not differ between patients and controls. Figure 2 summarizes the fMRI data of the patients and the control group.

The time course analysis of fMRI signal changes in the primary motor cortices yielded significant hemispheric differences between patients and controls. Expectedly, the M1 cortices of both hemispheres showed strongly crossed organization patterns in the controls when left and right finger tapping was performed. Major contributions came from M1 cortices contralateral to the tapping hand clearly following crossed motor organization patterns; i.e., 1.32% signal change in the right M1 was accompanied by 0.1% signal change in the left M1 during left hand finger tapping (see figure 2).

The expected scheme of crossed organization patterns was replaced by more bilateral and ipsilateral M1 contributions when the hand contralateral to the stenosis was performing the tapping task in both patients (see figure 2). Moreover, laterality assessment for the different tasks



**Figure 1.** Structural anatomic and perfusion imaging as well as MR angiography of two patients (1 and 2) with a high-grade stenosis (>80%) of the middle cerebral artery (MCA). T1-weighted anatomic imaging showed a small hypointense lesion in the right parietal white matter in Patient 1 and an incomplete small infarction in the territory of the left A. sulci precentralis in Patient 2. The primary motor and premotor cortices appeared structurally intact in both patients. Gadolinium-enhanced perfusion imaging showed a delay in the time to peak map (time in seconds to reach the maximum peak concentration) of 4 to 5 seconds in the ischemic hemisphere (Patient 1: right side; Patient 2: left side). The local relative maximum of contrast agent concentration (MP map) did not show interhemispheric differences for the two patients. MR angiography showed a high grade stenosis (>80%) of the main trunc of the MCA in both patients. In Patient 1 (anteroposterior view) the proximal trunc on the right side and in Patient 2 (dorsal view) the distal trunc of the left MCA just before the bifurcation was highly narrowed.

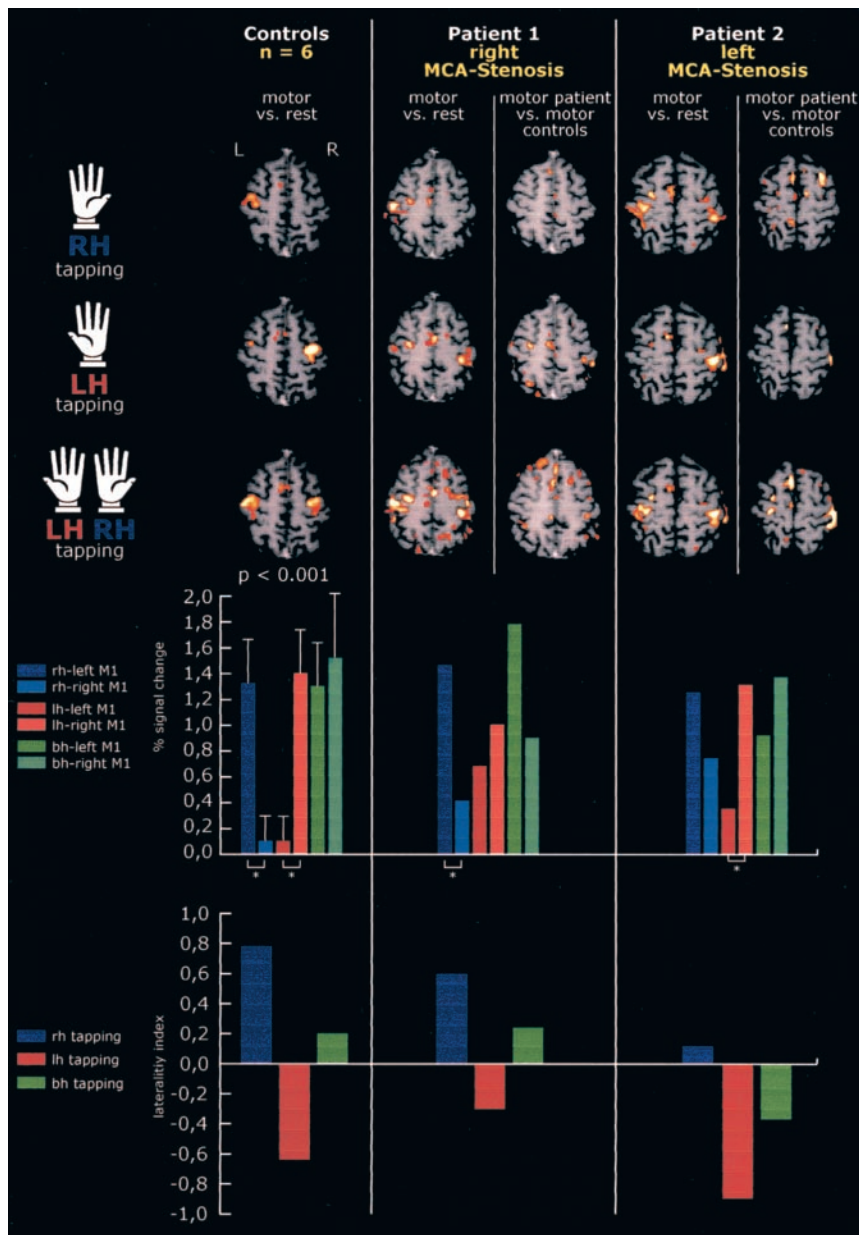


Figure 2. Top graph/left column: Activation results of the left hand, right hand, and bilateral finger tapping vs a resting baseline in normal controls ( $p < 0.001$ , uncorrected voxel level and  $p < 0.025$ , corrected cluster level). The fMRI data were normalized and averaged onto a three-dimensional reference image. Top graph/middle and right columns: Motor activation maps for each individual patient are displayed in two different ways. Left: Activation results of finger tapping vs resting baseline ( $p < 0.001$ , uncorrected voxel level and  $p < 0.025$ , corrected cluster level). Right: Additional motor activations of patients as compared to the control group. The statistical comparison is based on the contrast of motor activation states of individual patients vs the controls ( $p < 0.001$ , uncorrected voxel level and  $p < 0.025$ , corrected cluster level). Middle graph: The magnitude of the MR signal changes related to motor activation in the primary motor cortex (M1) of both hemispheres—based on a time course analysis—is displayed in the bar charts for the different conditions. It differed significantly between patients and controls. The strong bihemispheric contributions, when the hand contralateral to the stenosis was tapping, indicates the modulation of the MR blood oxygenation level dependent response in both patients and may indicate a reserve strategy. Bottom graph: Hemispheric motor laterality indices for the different tasks (range  $\pm 1$ : positive indices indicate left hemisphere dominance, negative indices show right hemisphere dominance). The expected crossed activation patterns typical of the normal controls were replaced by a more bilateral involvement of the motor network in each patient when the hand contralateral to the stenosis was tapping.

showed a reduced preponderance of the hypoperfused hemispheres in both patients when the corresponding hand was tapping (right vs left hand tapping: Patient 1: 0.62 vs  $-0.31$ ; Patient 2: 0.12 vs  $-0.93$ ; controls: 0.81 vs  $-0.66$ ).

**Discussion.** This article provides strong evidence of a task-related modulation of the fMRI BOLD response in the presence of impaired hemodynamics. The activated motor cortices appeared structurally intact. Our main finding was that patients with MCA stenosis showed an increased engagement of M1 and premotor cortices in the intact hemisphere during a motor task. Probably, this additional activation—not present in normal controls—served the maintenance of function. Hence, in the presence of impaired hemodynamics, the principle of crossed motor organization patterns is abandoned as a compen-

satory strategy. This functional shift to ipsilateral homologous motor and premotor cortices was previously described as a compensatory strategy in patients with central lesions.<sup>8,9</sup> It cannot be ruled out that the observed patterns evolved as reorganizational changes in the absence of major lesions.

Which mechanism accounts for the decrease in BOLD signal changes of the hypoperfused hemisphere in the patients? In a situation where the cerebral blood flow (CBF) is restricted, the close correspondence between neural activity and CBF—i.e., the neurovascular coupling—is deranged. Thus, failure to see normal activation does not necessarily indicate a lack of neuronal activity. The BOLD signal in the compromised hemisphere is therefore not clearly interpretable, regardless of whether the hemodynamic response is driven by local energy use on

the presynaptic level or by neurotransmitter related signaling processes as recently claimed.<sup>10</sup>

## References

1. Gibbs JM, Wise RJ, Leenders KL, Jones T. Evaluation of cerebral perfusion reserve in patients with carotid-artery occlusion. *Lancet* 1984; 11:310–314.
2. Inao S, Tadokoro M, Nishino M, et al. Neural activation of the brain with hemodynamic insufficiency. *J Cereb Blood Flow Metab* 1998;18: 960–967.
3. Bundo M, Inao S, Nakamura A, et al. Changes of neural activity correlate with the severity of cortical ischemia in patients with unilateral major cerebral artery occlusion. *Stroke* 2002;33:61–66.
4. Hund-Georgiadis M, von Cramon DY. Motor-learning-related changes in piano players and non-musicians revealed by functional magnetic-resonance signals. *Exp Brain Res* 1999;125:417–425.
5. Barbier EL, Lamalle L, Decors M. Methodology of brain perfusion imaging. *J MRI* 2001;13:496–520.
6. Lohmann G, Mueller K, Bosch V, et al. LIPSIA—A new software system for the evaluation of functional magnetic resonance images of the human brain. *Comput Med Imaging Graph* 2001;25:449–457.
7. Kiebel SJ, Poline JB, Friston KJ, et al. Robust smoothness estimation in statistical parametric maps using standardized residuals from the general linear model. *Neuroimage* 2000;10:756–766.
8. Caramia MD, Telera S, Palmieri MG, et al. Ipsilateral motor activation in patients with cerebral gliomas. *Neurology* 1998;51:196–202.
9. Seitz RJ, Hoflich P, Binkofski F, et al. Role of the premotor cortex in recovery from middle cerebral artery infarction. *Arch Neurol* 1998;55: 1081–1088.
10. Attwell D, Iadecola C. The neural basis of functional brain imaging signals. *Trends Neurosci* 2002;25:621–625.

# CME A randomized trial of botulinum toxin A for treatment of drooling

A. Lipp, MD; T. Trottenberg, MD; T. Schink; A. Kupsch, MD; and G. Arnold, MD

**Abstract**—The authors compared the efficacy of three different doses (18.75, 37.5, and 75 MU per parotid gland) of botulinum toxin A (BTX-A; Dysport, Ipsen Pharma, Germany) injections vs vehicle in patients with sialorrhea (n = 32) using a single-center, prospective, double-blind, placebo-controlled dose-finding study. The primary endpoint was achieved with 75 MU BTX-A without treatment-related adverse events, suggesting BTX-A is a safe and effective treatment for patients with sialorrhea.

NEUROLOGY 2003;61:1279–1281

Excess saliva and drooling are common complaints of patients with neurodegenerative disorders. Up to 80% of patients with Parkinson's disease (PD)<sup>1</sup> and approximately 20% of patients with motor neuron disease are affected by excess saliva and drooling.<sup>2</sup> Pharmacotherapy is limited by insufficient efficacy and adverse effects. Surgical treatments like denervation of the parotid gland,<sup>3</sup> salivary duct ligation,<sup>4</sup> or bilateral excision of the sublingual salivary glands<sup>5</sup> may risk irreversible adverse effects.

Botulinum toxin A (BTX-A; Dysport, Ipsen Pharma, Germany) is a known inhibitor of acetylcholine release in cholinergic nerve terminals and is well known to effectively alleviate dystonic and spastic symptoms.<sup>6,7</sup> Recently, several open-label studies reported decreased drooling after BTX-A injections into the parotid gland.<sup>8,9</sup> However, placebo-controlled

studies concerning dosages of BTX-A and duration of the clinical effect are not available.

The present study is a single-center, prospective, double-blind, placebo-controlled dose-finding study to test the efficacy and safety of three different doses of BTX-A (Dysport) in patients with sialorrhea.

**Patients and methods.** After approval by the local ethics committee, we examined 32 patients (23 men and 9 women) with severe drooling from our local movement disorder outpatient department (figure 1). Twelve patients had a bulbar form of ALS (mean severity of 27 points according to the ALS Functional Rating Scale [ALSFERS]); 12 patients had PD (mean motor impairment of 38 as measured by the Unified PD Rating Scale [UPDRS], part III); 4 patients had multiple system atrophy (MSA); and 4 patients had corticobasal degeneration (CBD; mean UPDRS III, 57 points). All patients had a loss of life quality because of drooling. Four weeks before the study and during the study, none of the patients received any antidrooling treatment other than the study drug.

After written informed consent, patients were randomized into one of four groups—placebo, 18.75, 37.5, or 75 MU BTX-A—for each parotid gland. Injection volumes were kept constant at 0.5 mL per side to assure blinding. We injected each parotid gland twice: one injection into the mass of the gland (0.3 mL) and an-

Additional material related to this article can be found on the *Neurology* Web site. Go to [www.neurology.org](http://www.neurology.org) and scroll down the Table of Contents for the November 11 issue to find the title link for this article.

From the Department of Neurology, Medical Faculty of the Charité, Humboldt University, Berlin, Germany.

Drs. Lipp and Trottenberg contributed equally to this article.

Supported in part by a research grant from Ipsen International GmbH, Germany.

Received February 3, 2003. Accepted in final form July 22, 2003.

Address correspondence and reprint requests to Dr. Axel Lipp, Department of Neurology, Charite, Humboldt University of Berlin, Schumannstrasse 20/21, D-10117 Berlin, Germany.